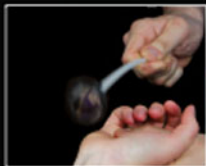
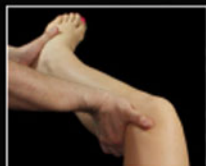
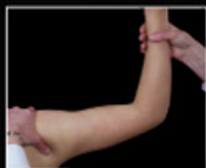Paul HATTAM and Alison SMEATHAM



SPECIAL TESTS IN MUSCULOSKELETAL EXAMINATION


An evidence-based guide for clinicians



CHURCHILL
LIVINGSTONE
ELSEVIER



Special Tests in Musculoskeletal Examination



Commissioning Editor: Rita Demetriou-Swanwick
Development Editor: Veronika Watkins
Project Manager: Vijayakumar Sekar
Designer/Design Direction: Kirsteen Wright
Illustration Manager: Bruce Hogarth

Special Tests in Musculoskeletal Examination

An evidence-based
guide for clinicians


Written by

Paul Hattam MSc MCSP FSOM

Director and Principal Physiotherapist,
The Physios, Sheffield, UK

Alison Smeatham MSc MCSP FSOM

Extended Scope Practitioner, Royal Devon
and Exeter Hospital, Exeter, UK



Edinburgh London New York Oxford Philadelphia
St Louis Sydney Toronto 2010

**CHURCHILL
LIVINGSTONE**
ELSEVIER

First published 2010, © Elsevier Limited. All rights reserved.

No part of this publication may be reproduced or transmitted in any form or by any means, electronic or mechanical, including photocopying, recording, or any information storage and retrieval system, without permission in writing from the publisher. Permissions may be sought directly from Elsevier's Rights Department: phone: (+1) 215 239 3804 (US) or (+44) 1865 843830 (UK); fax: (+44) 1865 853333; e-mail: healthpermissions@elsevier.com. You may also complete your request online via the Elsevier website at <http://www.elsevier.com/permissions>.

ISBN 978-0-7020-3025-3

British Library Cataloguing in Publication Data

A catalogue record for this book is available from the British Library

Library of Congress Cataloguing in Publication Data

A catalog record for this book is available from the Library of Congress

Notice

Neither the Publisher nor the Authors assume any responsibility for any loss or injury and/or damage to persons or property arising out of or related to any use of the material contained in this book. It is the responsibility of the treating practitioner, relying on independent expertise and knowledge of the patient, to determine the best treatment and method of application for the patient.

The Publisher

ELSEVIER

your source for books,
journals and multimedia
in the health sciences

www.elsevierhealth.com

Working together to grow
libraries in developing countries

www.elsevier.com | www.bookaid.org | www.sabre.org

ELSEVIER

BOOK AID
International

Sabre Foundation

The
Publisher's
policy is to use
paper manufactured
from sustainable forests

Printed in China

CONTENTS

Dedication	vi
About the authors	vii
Acknowledgements	viii
Foreword	x
1 Introduction	1
2 Shoulder	17
3 Elbow	89
4 Wrist and hand	113
5 Hip	151
6 Knee	181
7 Ankle and foot	235

DEDICATION

For Jean Barbara Smeatham 1937–2008
Faith, hope and love.

ABOUT THE AUTHORS

Paul Hattam and Alison Smeatham are physiotherapists with a special interest in musculoskeletal medicine, having accumulated many years of experience treating patients both in the National Health Service and in private practice. They were among the first extended scope physiotherapists (ESPs) to establish orthopaedic triage in primary care during the 1990s, a model that was subsequently evaluated and reproduced throughout the UK. They completed a musculoskeletal master's programme in 2002/3 and retain a keen interest in research in their area of specialty. Both tutor regularly on postgraduate courses for doctors and physiotherapists in musculoskeletal medicine as well as being actively involved in educational programmes closer to their homes. Paul now leads the team at The Physios (www.thephysios.com) in Sheffield, UK, while Alison works as an ESP with the specialist hip team at the Princess Elizabeth Orthopaedic Centre in Exeter, UK.

ACKNOWLEDGEMENTS

The authors would like to thank everyone who helped us see this project through to completion. As is often the case, the size of an undertaking only becomes evident once you have started it and the encouragement we received from our families, friends and colleagues was always welcome and helped to spur us on.

We benefited enormously from the collective wisdom of a number of medical and physiotherapy colleagues from across the UK and are particularly grateful to the following: Jill Gillespie, Margaret Rees, Chris Blundell, and the hip and knee surgeons and ESPs at Princess Elizabeth Orthopaedic Centre and Devon PCT for their contributions. We appreciated the free exchange of information and ideas with our teaching colleagues Elaine Atkins, Jill Kerr and Emily Goodlad, even though they managed to pip us to the post and submit the manuscript for their book first.

Nigel Hanchard contributed to the labral, tendon and impingement tests at the shoulder. As lead author of the Cochrane prototype diagnostic review on this topic (in development), and of the Chartered Society of Physiotherapy's clinical guidelines on shoulder impingement, his familiarity with the evidence base provided a rich resource of which we made good use. Nigel also made welcome suggestions for the introductory chapter, all of which were very valuable.

We would like to thank Gordon Smith who, despite agreeing to completely unreasonable deadlines, painstakingly proof read each section and provided correction and challenge in equal measure. We were also very grateful for the fresh pair of eyes willingly provided by Joy Hattam at the final proof reading stage. Our model for the photographs, Alison Crewesmith, was good humoured throughout a very long day and Ant Clifford had the eye to make the photos clear and visually appealing. Space to spread out and edit the book was generously provided by Lindsay Jackson at EEF, Sheffield.

Thanks to everyone at Elsevier, particularly Heidi Harrison for her initial enthusiasm that helped to launch the idea and to Veronika Watkins and Rita Demetriou-Swanwick for their endless patience and guidance during the writing and final editing stages.

Paul thanks

Time away researching and writing the book inevitably meant an increased burden on my colleagues and I would like to thank everyone at *The Physios* for their encouragement and support. My family have exhibited patience beyond measure and I am hugely grateful to my wife, Alison, for taking everything perfectly in her stride and helping me keep things in perspective, as well as retaining a keen sense of humour throughout. The same can be said for Rachael, James and Naomi who happily got on with life while Dad tapped away on the computer. You're amazing!

Alison thanks

I would like to thank friends and colleagues who managed to remain interested and enthusiastic about this project over many cups of tea and glasses of wine. My family, and in particular Mum and Dad, continued to provide unwavering encouragement and support even when much more important events were taking place and my love and gratitude goes to them and to David, Karen, Tom, Rosie, Irene and Terry.

FOREWORD

Paul Hattam and Alison Smeatham are long-time teaching colleagues of mine. From their first musings that a new text was needed to acknowledge and examine the growing bank of additional tests for peripheral lesions, I have been so excited to see their book in print knowing that they would create this clear, concise and highly readable resource drawn from a rigorous and objective trawl through the available evidence. They have wisely recruited the opinion of other experts too though, acknowledging that many tests are chiefly derived from empirical practice and should not be discarded without due consideration for clinical experience. As we might expect, many of the tests do not enjoy a strong, consistent evidence base to support their application and not surprisingly, it is the expert opinion that draws the eye to guide practice.

I have read this book because I wanted to learn from it and I have already found it to be a valuable resource. The initial 'About the book' section sets the scene for the rest of the book, providing generic 'ground rules' for how to apply the tests and an explanation of how the literature was searched and the evidence appraised and interpreted. 'Likelihood ratios', combining sensitivity and specificity, are justified as the best statistics to assess the clinical usefulness of the diagnostic tests they have presented. The tests are described simply and clearly and are accompanied by concise, referenced discussion to provide context; focussing on the tests themselves as opposed to the pathology of specific lesions. In this respect a gap has been plugged since that tends to sit outside the remit of other texts in musculoskeletal medicine; even those dedicated to assessment.

The book includes tests I haven't come across, tests I'd forgotten and tests I've always been slightly confused about. The authors' determination to unravel the complex and to keep to the facts is both welcome and reassuring and the simple device of beginning each test with an 'also known as' (aka) list defuses the confusion where many of the tests described in the literature exist under several different names. In this they have exposed their awareness of just who their reader is – a busy clinician with the nous and will to read more – but with so little time. The authors have struck an

effective balance between providing a useful pocket reference resource and a handbook to support clinical assessment and diagnosis. I commend their text with confidence, knowing both authors as I do for their determination to question and challenge and the rigour with which they will have performed their review.

Elaine Atkins DProf MA MCSP Cert FE
October 2009

This page intentionally left blank

INTRODUCTION

A ABOUT THIS BOOK 2

B ALSO KNOWN AS (AKA) 3

C TECHNIQUE 3

Ground rules 3

How to do the tests 5

D CLINICAL CONTEXT 6

Searching the literature 6

Appraising the evidence 6

Interpreting the evidence 9

E VARIATIONS AND RELATED TESTS 13

F CLINICAL TIPS/EXPERT OPINION 13

A ABOUT THIS BOOK

Clinical examination is the bedrock of diagnosis in musculoskeletal (MSK) medicine. It enables the clinician to both assemble information and to interpret the findings in order to assist in identifying the nature and stage of the patient's disease or injury, determine the need for further investigations, provide a prognosis, guide treatment and measure outcome. Its big advantage is that it can be used at any stage in the patient's management and reproduction of the symptoms provides not only immediate feedback but also reassuring evidence, to both clinician and patient, that the source of the pain has been identified. Physical tests are quick and convenient to perform and, in the hands of a skilled practitioner, facilitate appropriate and cost-effective intervention.

The proliferation of additional or special tests used in MSK examination over the years has left the clinician with a vast array of physical tests at his or her disposal. All clinicians know that isolating the lesion and planning effective intervention is not about performing lots of tests for the sake of it, but instead selecting the most appropriate examination procedures as part of the clinical reasoning process. With so many tests in the clinical domain, combined with uncertainty concerning their accuracy and reliability, it can be hard for clinicians to determine whether or not the tests they have chosen are in fact providing them with the information they need. In addition, because tests involve both clinical and interpretative skills, results may differ with the level of the tester's technical expertise, thereby limiting the generalization of results produced from individual studies.

Special tests are usually incorporated into the physical examination once a thorough history has been taken and clinicians can use this information to guide the selection of examination procedures. A familiarity with the core elements of the physical examination is therefore essential before incorporating special tests that can be more challenging to perform and interpret. These tests are often misreported, poorly evaluated or simply overlooked, leaving clinicians uncertain about their application and value. Most of us have had the experience of being confounded when a learned colleague expresses disbelief at our omission from the patient examination of the 'grabem-pullem-and-twistem' test – the one perfect test guaranteed to diagnose the particular condition facing you! Having familiarized yourself with this manoeuvre and used it in practice, it is

sometimes not too long before you are questioning its value and wondering whether it is any more helpful than any other test you might have used. So, how do we decide which tests are actually worth using and which ones should be discarded?

As clinicians who treat patients on a daily basis, we decided to dig a bit deeper and look at the evidence base for as many additional or special tests as we could. As our primary aim was to produce a useful guide for clinicians, we selected tests which were either in common use, had supporting evidence or which we and our colleagues working in a particular specialty deemed helpful.

By gathering the tests in one place, describing the technique in detail, presenting the evidence and mixing in clinical tips and expert opinion, we hope in this book to inform your selection of special tests, enable you to reproduce the manoeuvres reliably and interpret the results meaningfully.

As you will see, there is a format which is repeated for each test; we explain the background to each section below.

B ALSO KNOWN AS (AKA)

Where we found several names for the same test we have listed the less well known names in the 'also known as' (aka) section. The use of eponyms in this area of medicine is commonplace and we have continued the tradition by using them in cases where the test is best known by this name. Inevitably, there are instances of regional and professional differences in the name given to a particular test and we have had to make a judgement in one or two cases. There has been debate about the relative merits of using eponyms (Matteson & Woywodt 2007, Whitworth 2007), but since their use is ingrained in medical practice, in our view it would be perverse to refer to the tests in any other way.

C TECHNIQUE

Ground rules

There are a number of essential principles to keep in mind when performing these special tests:

- 1 *You have already taken a thorough history and performed a basic physical examination.*

From this, you may suspect a lesion in a joint or specific tissue. Special tests are most likely to confirm or rule out what you already suspect and no test or investigation can replace this initial 'sifting' process. It serves as a vital starting point that enables the clinician to consider differential diagnoses before selecting the most appropriate test(s)/investigation(s) needed for the target condition.

2 *Know what is 'normal' for your patient.*

Experienced clinicians will recognize that the range of joint movement in the normal population varies hugely with age, sex and body type – imagine the range of 'normal' hip movement in a 15-year-old gymnast, a 30-year-old prop forward and a 75-year-old former sumo wrestler if you have any doubts! In musculoskeletal medicine we have the advantage in most patients that their 'normal' will be obvious when examining the unaffected side. For each test, we have made the assumption that the clinician will first have carried out the manoeuvre on the unaffected limb in order to ascertain the patient's normal range of movement and response to the procedure.

3 *Be selective in which tests you use.*

Some tests have good evidence to support their use while others are advocated for use in certain circumstances by expert clinicians. In many cases, the jury is still out, and the clinician therefore needs to exercise great care when applying the tests and interpreting the results. Opt for quality rather than quantity – using a huge range of extra tests is invariably counterproductive. At best you will end up feeling confused and, at worst, your patient will end up being investigated and treated for the wrong condition. Using a sensitive test as part of the screening examination for a condition (a sensitive test performed well allows you to rule out a condition if the test is negative) and a highly specific test to confirm a suspected diagnosis (if this is positive you can be more confident that the condition is present) will help you target investigations and plan treatment.

4 *Use the same tests regularly.*

Practice makes perfect. The more exposure you get to a particular patient group or target condition, the more proficient you will become at performing the test and interpreting the results. Developing the technical skills necessary to perform the tests well will improve the intra-tester reliability and increase your confidence in the findings.

5 *Remember that no test is diagnostic.*

Of course, very few tests can be expected to conclusively rule in or rule out any particular condition but they should add to the index of suspicion which will inform your clinical reasoning process.

How to do the tests

Performing the tests accurately and consistently is vital, and again there are a few basic suggestions on how you can do this:

1 *Make sure the patient is comfortable.*

This will help minimize spasm, pain and voluntary muscle activity. If the patient is apprehensive and unable to relax, performing the test will be difficult and the result unreliable.

2 *Keep yourself relaxed and comfortable.*

Bony thumbs or an overly tight grip of the soft tissues is not a pleasant experience and this will prevent the patient from relaxing adequately. Wherever possible, keep your hands relaxed and use them not only to carry out the manoeuvre but also to feel the response of the tissues and patient. Ensure your position facilitates a mechanical advantage to enable you to provide appropriate support or resistance with the minimum effort.

3 *Interpret the findings correctly.*

Does the test replicate the patient's presenting symptoms, whether this is pain (site and nature), apprehension, clicking, locking or paraesthesia?

4 *Modify the technique depending on the condition.*

In an acutely painful, severe or recent injury, make sure you carefully apply passive or resisted stresses gradually to avoid unnecessary provocation of pain and possible disruption of the healing breach. In mild or chronic cases, if the initial test is pain-free, repeat the manoeuvre more strongly to replicate more vigorous functioning of the tissue.

5 *Modify the technique depending on the type of tissue.*

It may be appropriate when testing inert structures such as ligaments to start with a small amplitude movement so that an early response to the test (i.e. pain and/or apprehension) can be detected. Steadily increasing the amplitude, range and speed of the test will then ensure that the capacity of the structure(s) to restrict excessive joint play at the end-range of movement

has been properly evaluated. Normal ligament brings the movement to a firm 'stop' and loss of this, accompanied by increased range, is suggestive of joint instability. When testing contractile structures, resistance to movement should be increased slowly at first to allow assessment of the patient's pain and any apprehension to the test. The amount of resistance can then gradually be increased, allowing full strength to be assessed. Depending on the relative size and strength of the clinician and patient, the clinician can vary the resistance applied by using a short or long lever.

D CLINICAL CONTEXT

In presenting the clinical context for each test, the following search criteria were used, resulting in a number of considerations being made as we appraised and interpreted the evidence:

Searching the literature

Literature searches were conducted for articles in English using the National Library for Health, Google scholar, AMED (1985 to present), CINAHL (1982 to present), EMBASE (1974 to present) and MEDLINE (1966 to present). Keywords and combinations of keywords were used: diagnostic, diagnosis, examination, the joint or structure involved (e.g. shoulder), likelihood ratio, manoeuvre, name of test, probability, sensitivity, sign, specificity, test. A secondary search was completed from reference lists in published articles.

Appraising the evidence

My students are dismayed when I say to them 'half of what you are taught as medical students will in 10 years have been shown to be wrong. And the trouble is none of your teachers knows which half.'

Dr Sydney Burwell, Dean of Harvard Medical School (Sackett et al 2000)

As we read through the literature, it became apparent that the top hierarchy of evidence was lacking; with very few systematic reviews or prospective blind comparisons that used a relevant

reference standard or a consecutive series of patients from a relevant clinical population (Fritz & Wainner 2001). Of the available evidence, it was naturally difficult to work out whether we were looking at the half of the evidence which will have been proven correct in 10 years, or the half which will not!

There are several questions that can help to identify the validity of a study (Heneghan & Badenoch 2006, Jaeschke et al 1994, Sackett et al 2000), and examining the answers to these questions helped us to identify broad and repeated themes that influence the outcome of research studies examining the reliability of MSK special tests which deserve cognisance.

1 *Is there a clearly defined question?*

Most studies had a clearly defined research question as well as specifying the target condition, which is important given the propensity of some tests to stress more than one structure (e.g. the active compression test at the shoulder stresses both the acromioclavicular joint (ACJ) and the glenoid labrum but is more specific for ACJ lesions).

2 *Has the diagnostic test being examined been compared to an appropriate reference standard?*

A reference or gold standard provides confirmation that the condition in question is present or absent. It is the measure against which all other tests for that condition are evaluated and so in itself should have proven accuracy. Unfortunately, this does not exist uniformly in MSK medicine and the results of MRI or surgery are often as close to the gold standard as we can get.

In situations where the reference standard has demonstrated validity, and when it either forms part of the accepted diagnostic process or treatment, its use in research is fairly straightforward. A good example is the use of arthroscopy in meniscal lesions at the knee where it not only serves a purpose in delivering appropriate surgical treatment but coincidentally provides the most accurate way of diagnosing a meniscal lesion. It therefore provides an excellent reference standard against which preoperative physical tests (such as McMurray's) can be measured. However, other conditions and injuries provide a stiffer challenge. What would be a suitable reference standard in the case of grade I medial collateral ligament sprain at the knee? The valgus stress test is widely accepted as a reliable diagnostic test although using

arthroscopy in this instance would clearly be inappropriate and unlikely to make it past the ethics committee! As a result, the valgus stress test at the knee is a widely used and accepted test but has no evidence to support its use.

A further problem can be encountered if the reference standard selected has not itself been evaluated sufficiently before being used as a measure. For example, in early studies on femoro-acetabular impingement at the hip, physical MSK tests were measured against findings on MRI and MR arthrography, the results of which are now known to correlate only moderately with those of arthroscopy, the current, generally recognized gold standard for this condition (Malanga & Nadler 2006).

The lack of an appropriate and/or validated reference standard does appear to be a factor in the lack of evidence and this may be a reason why so many of the 'bread and butter' tests used in everyday practice have no evidence to support their use, for example tennis and golfer's elbow and simple ligament sprains at the knee and ankle.

3 *Has the diagnostic test been evaluated on a spectrum of patients?*

Ideally the patients studied should cover the full spectrum of the condition, replicating the range in the population on whom the test would be used in practice. However, the vast majority of studies on MSK tests are done in a hospital setting and are therefore likely to be carried out on subjects with more advanced pathology than that encountered in primary care. This may contribute towards a reduction in the number of false positives and true negatives in the sample, thereby over-estimating sensitivity and under-estimating specificity which, in turn, generates a spectrum bias.

Patients with co-morbidities that mimic the target condition should also be included, again replicating the circumstances in which the test is likely to be used, rather than evaluating the results against asymptomatic patients. The accuracy of the test varies significantly when tested in patients with other co-morbidities (e.g. the use of McMurray's test in patients with a history of a meniscal tear against those with underlying osteoarthritis).

4 *Has the reference standard been applied to all patients?*

To achieve stringent data on the accuracy of a test, the reference standard should be applied to all subjects, including those

who have a negative test (and are therefore considered unlikely to have the condition being targeted). Application of the reference standard, however, could carry unacceptable risk and cost. Thus, in many studies of diagnostic accuracy, patients with negative test results are subjected to alternative, less invasive but sub-optimal 'reference standards' or may not be subjected to a reference test at all, preventing true negatives and, therefore, specificity from being calculated.

- 5 *Have the intended use, the physical performance and the definition of a positive and negative test been explained?*

It is interesting to see how tests evolve over time and change from the original description. Adaptations of tests are often used in studies without making this explicit or describing the test adequately so that it can be replicated by other workers. The use of an adapted test means that comparison with other studies that used the original or other adaptations is not possible and these issues are rife in studies of MSK diagnostic tests.

- 6 *Is the test validated in independent groups of patients?*

It is worth checking whether the original description of a test's performance is validated by independent workers as the originator(s) of a test often report high levels of diagnostic accuracy that are not reproduced by independent researchers.

- 7 *How can you apply the evidence to your own patients?*

Applying the results of the test to your patient population needs to be done with caution as there are many variables to be taken into consideration: patient population, location of study (i.e. primary or secondary care), skill level of clinicians performing the test, etc. Will the test(s) assist in the management of your patient population and lead to improved diagnostic accuracy and treatment?

Interpreting the evidence

Essentially, we want to know whether a diagnostic test is *accurate* – i.e. that it is positive when a particular pathology is present (true positive) and negative when it is not (true negative). Unless the test is perfect (which none are), it will sometimes prove positive when pathology is not present (false positive) or fail to reveal pathology

when it is present (false negative). The propensity of a test to yield each of these findings can be tabulated as follows:

REFERENCE TEST			
		Target condition present	Target condition absent
Test result	Positive	a	b
	Negative	c	d

a true positive

b false positive

c false negative

d true negative

The accuracy of diagnostic tests can be represented by various statistics, among which are *sensitivity*, *specificity* and *likelihood ratios*:

1 Sensitivity

Sensitivity is the proportion of people with the condition of interest (target condition) who have a positive test. If 100 people have the condition, then a test that is 98% sensitive will detect 98 of those cases and miss two.

Sensitivity is calculated using the figures from the table above:

$$\text{Sensitivity} = \frac{a}{(a + c)}$$

The value of a very sensitive test is that, if negative, it will effectively rule the condition out. The mnemonic 'SnNout' (a highly **S**ensitive test when **N**egative rules the diagnosis **out**) may help as an aide-memoire (Sackett et al 2000).

It may help if we apply this to a real condition. When considering a diagnosis of carpal tunnel syndrome (CTS), the presence of paraesthesia in the hand would be considered to be a highly sensitive finding which would identify patients with the condition. However, among those identified would be patients with other causes of hand paraesthesia such as nerve entrapment in the neck or elbow. So this high level of sensitivity is most helpful, not in diagnosing the condition, but in excluding

it (i.e. if hand paraesthesia is absent CTS can be confidently ruled out).

2 *Specificity*

Specificity measures the proportion of people without the condition of interest (target condition) who have a negative test. If 100 people are free from the condition, then a test that is 98% specific will correctly exclude 98 of those cases but will incorrectly identify two people as having the condition.

Specificity is calculated using figures from the table opposite.

$$\text{Specificity} = \frac{d}{(b + d)}$$

A very specific test is useful at ruling in the target condition, as summarized by the mnemonic 'SpPin' (a highly **S**pecific test when **P**ositive will rule the diagnosis **i**n) (Sackett et al 2000).

Quite a number of special MSK tests are highly specific. For example, McMurray's test for meniscal lesions at the knee has a high specificity which means that a positive test makes a meniscal tear highly likely (ruling the condition in), but a negative test does not necessarily rule out the possibility of such a tear.

3 *Likelihood ratios*

Likelihood ratios (LR) are the best statistics to assess the clinical usefulness of a diagnostic test as they combine the sensitivity and specificity into a ratio that quantifies a shift in the probability of a condition being present or absent in the event of a negative or positive test.

As most musculoskeletal tests have two outcomes – positive or negative – we can talk about two ratios; one for a positive test outcome (LR+) and one for a negative outcome (LR-).

The LR+ indicates the increase in odds favouring the target condition being present when the test result is positive. A large LR+ indicates that the condition is more likely to be present. This can be calculated from the sensitivity and specificity values:

$$\text{LR+} = \frac{\text{sensitivity}}{(1 - \text{specificity})}$$

The LR⁻ is the probability of the target condition being present given a negative test result. A small LR⁻ indicates that the condition is less likely to be present:

$$\text{LR}^- = \frac{(1 - \text{sensitivity})}{\text{specificity}}$$

The further away from 1 a LR⁺ is and the nearer a LR⁻ is to 0, the more informative the test will be. A LR of 1 is as useful as tossing a coin to decide whether or not the condition is present; it indicates that the odds do not change whether the test is negative or positive.

We wanted primarily to present the underpinning evidence for each test in a format that provided the clinician with a quick and easy gauge of a test's clinical usefulness. In doing so, we have developed a scoring system based on the following table which summarizes the relative value of the LR scores.

LR ⁺	LR ⁻	Meaning	Clinical usefulness	Symbol
>10	<0.1	Generates a large and often conclusive shift in probability	Excellent	★★★
5–10	0.1–0.2	Generates a moderate shift in probability	Good	★★
2–5	0.2–0.5	Generates a small but sometimes important shift in probability	Fair	★
1–2	0.5–1	Alters probability to a small and rarely important degree	Poor	

Where some evidence exists, a table is used which clearly identifies the structure or lesion being targeted as well as the LR values. These values are then interpreted into symbols (as shown in the table above), enabling the clinician to quickly determine the relative

value of any particular test based on the available evidence. For example:

Author and year	LR+	LR–	Target condition
Kibler 1995	9.75 ★★	0.24 ★	Unstable SLAP lesion
Parentis et al 2002, 2006	0.81	1.04	Any SLAP lesion

SLAP = superior labral anterior posterior

There is no doubt that some people prefer a text that is more statistically heavy, but we make no apologies for gearing this book towards the busy clinician who wants a clinical guide and not a statistical one. Full references are given at the end of each chapter to point you to sources for further study and we would be delighted if this book prompted further research in this area – the work is certainly needed.

E VARIATIONS AND RELATED TESTS

Confining our search to the peripheral joints, we were surprised to find literally hundreds of tests, only a few of which were in common use. Our search at the knee, for example, yielded nearly 100 meniscal tests alone, comprising many variations and adaptations of the three core tests we have included in this book. It would be pointless to include every single one, not least because evidence to support their use is largely absent, but where there was supporting evidence, or we considered variations to add value, they have been included. We categorized any other physical test that could also be used to aid diagnosis of the target condition under ‘related tests’.

F CLINICAL TIPS/EXPERT OPINION

Where possible we have endeavoured to inject lots of clinical tips as well as expert opinion into the text. For this, we collaborated with

consultant orthopaedic surgeons and extended scope physiotherapists working in each sub-specialty and as a result have drawn together a wealth of expertise which serves as a substantial resource for the clinician. We have not attempted to validate this – it is purely *opinion* and we have illustrated this in the following way:

SYMBOL	DEFINITION
★★★	Really useful test commonly utilized in practice
★★	Useful in certain circumstances or in combination with other special tests for the target condition
★	Rarely used either because there are more reliable tests or the target condition is less common. May have limited use in certain circumstances

Combining this with the evidence that we have presented, the clinician should be well placed to form a judgement on the relative merits of each test and decide whether it deserves a place in his/her clinical examination.

References

- Fritz, J.M., Wainner, R.S., 2001. Examining diagnostic tests: an evidenced based perspective. *Phys. Ther.* 81 (9), 1546–1564.
- Heneghan, C., Badenoch, D., 2006. *Evidence Based Medicine Toolkit*, second ed. Blackwell, Oxford.
- Jaeschke, R., Guyatt, G.H., Sackett, D.L., 1994. Users guide to the medical literature VI: how to use an article about a diagnostic test. B: what are the results and will they help me in caring for my patients? *JAMA* 271 (5), 389–391.
- Malanga, G.A., Nadler, S., 2006. *Musculoskeletal physical examination: an evidence-based approach*. Elsevier Health Sciences, Philadelphia.
- Matteson, E., Woywodt, A., 2007. Head to head: should eponyms be abandoned? *Yes. Br. Med. J.* 335, 424.
- Sackett, D.L., Straus, S.E., Richardson, W.S., et al., 2000. *Evidence Based Medicine: How to Practice and Teach EBM*, second ed. Churchill Livingstone, Edinburgh.
- Whitworth, J.A., 2007. Head to head: should eponyms be abandoned? *No. Br. Med. J.* 335, 424.

Additional reading

- Deeks, J.J., Altman, D.G., 2004. Diagnostic tests 4: likelihood ratios. *Br. Med. J.* 329 (7), 168–169.
- Knottnerus, J.A., Buntinx, F., 2002. *The Evidence Base of Clinical Diagnosis*. Wiley Blackwell, Chichester.
- Moore, A., McQuay, H., 2006. *Bandolier's Little Book of Making Sense of the Medical Evidence*. Oxford University Press, Oxford.

This page intentionally left blank

SHOULDER

with contributions by Nigel Hanchard PhD MSc, MCSP
Senior Research Fellow, Teeside University,
Middlesbrough, UK.

A TENDON TESTS 19

Speed's test	19
Yergason's test	21
Empty/full can tests	24
External rotation lag sign	27
Lift-off sign	30

B IMPINGEMENT TESTS 34

Neer's sign	34
Hawkins-Kennedy impingement test	39
Internal rotation resistance strength test	42
Posterior impingement test	44

C LABRAL TESTS 46

Crank test	46
Biceps load II test	50
Anterior slide test	52
SLAP prehension test	54

D INSTABILITY TESTS 56**Apprehension and relocation test 56****Load and shift test 61****Norwood stress test 67****Sulcus sign 71****E ACROMIOCLAVICULAR JOINT (ACJ) TESTS 76****Active compression test 76****Scarf test 79****Shear test 81**

A TENDON TESTS

Speed's test

Aka

Biceps test

Straight arm test

Purpose

To identify biceps tendon pathology in the bicipital groove and unstable superior labral anterior posterior (SLAP) lesions.

Technique

Patient position

Sitting or standing with the affected shoulder in 60–90° of forward flexion. The elbow is fully extended and forearm supinated.

Clinician position

Standing on the affected side, one hand stabilizes the patient's shoulder while the other is placed on the anterior surface of the lower forearm.

Action

The patient is asked to maintain the start position as downward pressure on the lower forearm is applied by the clinician.

Positive test

Pain localized to the bicipital groove may indicate a tendinopathy or a true tenosynovitis of the long head of biceps. Deeper-seated pain may implicate biceps/labral complex injury.



Fig. 2.1 • Speed's test.

Clinical context

A number of studies (Bennett 1998, Guanche & Jones 2003, Parentis et al 2006) have evaluated the diagnostic accuracy of Speed's test for biceps, general labral and SLAP lesions against a reference standard of arthroscopy in secondary and tertiary care populations with shoulder pain of mixed causes. None have found Speed's test particularly useful at ruling biceps tendon pathology or unstable SLAP lesions either in or out (Table 2.1).

TABLE 2.1 SPEED'S TEST

Author and year	LR+	LR-	Target condition
Bennett 1998	1.38	0.96	Biceps or SLAP lesion
Guanche & Jones 2003	0.35	1.23	Any SLAP lesion
Kim et al 2003a	1.48	0.82	Any SLAP lesion
Parentis et al 2002, 2006	1.50	0.76	Any SLAP lesion

SLAP = superior labral anterior posterior

Clinical tip

It might be expected that a ruptured long head of biceps would result in painless weakness on Speed's test but a more obvious diagnostic indicator is the so-called *Popeye sign* where a marked bulge appears just above the elbow on contraction of the biceps. More proximally the muscle is notably absent.

EXPERT OPINION	COMMENTS
★★★	<p>Speed's test</p> <p>Used regularly if either a biceps or SLAP lesion is suspected.</p>

Variations

The first written description of Speed's test was by Crenshaw & Kilgore (1966), who cited as their source a personal communication with the test's originator. Their description implied, but did not explicitly state, that the test should be performed isotonicly

against the tester's resistance. The starting and finishing positions were not specified. Perhaps not surprisingly, interpretations have varied. The description used above mirrors that of Bennett (1998), which is clear and likely to be reproducible.

Yergason's test

Purpose

To identify a lesion of the long head of biceps tendon or an unstable superior labral anterior posterior (SLAP) lesion.

Technique

Patient position

Sitting or standing with the arm in the anatomical position.

Clinician position

Standing on the affected side, the examiner takes the forearm and flexes the elbow to 90° leaving the forearm in a pronated position. The elbow is stabilized with one hand, keeping the upper arm adjacent to the patient's side. The heel of the hand is placed over the dorsal surface of the lower radius with fingers wrapped around the lateral aspect of the forearm in preparation to provide resistance.

Action

The patient moves the forearm into supination against resistance.

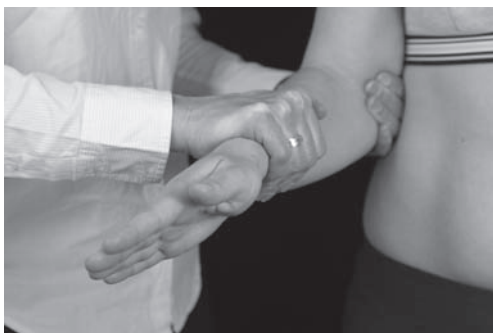Positive test

Reproduction of the patient's pain suggests the presence of a lesion of the long head of biceps or a SLAP lesion. If during the test the biceps tendon is felt to reproduce a 'clicking' sensation familiar to the patient, laxity or a tear of the transverse humeral ligament (that contains the tendon in the groove) should be suspected (see Fig. 2.2).

Clinical context

Yergason originally devised this manoeuvre for detecting bicipital tendinitis (Yergason 1931) but it is now apparent that all parts of the tendon complex are loaded and pain may emanate from a genuine tenosynovitis (as the tendon passes through the bicipital groove), tendinopathy or a SLAP lesion (as the long head of biceps attaches to its glenoid-labral origin). It also tests the ability of the transverse humeral ligament to maintain the tendon in the groove. The biceps tendon can be involved in an isolated overuse injury in the younger population

Fig. 2.2 • Yergason's test showing resisted supination.



although it is most commonly associated with rotator cuff disease in the older patient.

This test has found increasing acceptance in diagnosing SLAP lesions (see labral tests, p. 46). So much so, that studies exploring its diagnostic value have all measured its ability to detect labral injury rather than biceps pathology (Guanche & Jones 2003; Oh et al 2008; Parentis et al 2002, 2006; Table 2.2).

TABLE 2.2 YERGASON'S TEST

Author and year	LR+	LR-	Target condition
Guanche & Jones 2003	3.00 ★	0.92	Any SLAP lesion
Oh et al 2008	0.92	1.01	Any SLAP lesion
Parentis et al 2002, 2006	1.86	0.94	Any SLAP lesion

SLAP = superior labral anterior posterior

Clinical tip

As an alternative, providing the elbow is fixed adequately between the waist/hips of the examiner and patient, the free hand can palpate over the bicipital groove at the shoulder to detect any abnormal subluxation or 'snapping' during the test.

EXPERT OPINION	COMMENTS
★★	<p>Yergason's test</p> <p>Used if instability of the biceps tendon in the groove or a SLAP lesion is suspected.</p>

Variations

A commonly used variation of the original test has been described where the patient simultaneously moves the shoulder into external rotation and forearm supination against resistance. This is a more complex movement for patients to perform and getting them to rehearse it without resistance initially may help to elicit an effective test when resistance is added. Elbow flexion can also be added to the combined movement. As it was the original version of the test utilized in all the studies, any perceived additional benefit of using this variation must therefore be speculative.

Related tests

Moving the biceps tendon from side to side in the bicipital groove (*Lippman's test*) may expose localized tenderness or more usefully identify excess movement of the tendon, suggesting laxity or a tear of the transverse humeral ligament. The tendon is easily palpated between the greater and lesser tuberosities with the shoulder in the anatomical position and the elbow flexed to 90°; however, *many* of the tendons around the shoulder are tender on palpation and, where tenderness is used as a primary indicator, the possibility of recording false positives is very high.

Gilchrest's sign is positive when pain and/or snapping over the bicipital groove is elicited as the affected shoulder is lowered from a fully elevated position, through abduction, with the arm externally rotated and holding a 2 kg weight. This finding also points towards a bicipital lesion. The pain and snapping are most likely to appear when the arm is in the mid-position.

Injury to the biceps insertion on the radial tuberosity can be detected by resisting elbow flexion with the forearm in a pronated position. Normally the biceps would assist brachialis in flexing the elbow and generate some *supination of the forearm* in the process – a feature known as *Heuter's sign*. A biceps insertional tear will inhibit the extent of the flexion/supination contraction, leaving brachialis

to generate the bulk of flexion power and resulting in an obvious absence of supination, i.e. a negative Heuter's sign.

Ludington's test requires the patient to place both hands on top of the head with the fingers interlocked. The patient then contracts and relaxes the biceps on both sides as the clinician attempts to palpate the biceps tendon proximally. If it is not possible to palpate the tendon on the affected side, a complete rupture of the long head is possible.

Empty/full can tests

Aka

Supraspinatus strength test
Jobe's test
Scaption test

Purpose

To detect the presence of supraspinatus tendinopathy, a partial/complete tear or neurogenic weakness of supraspinatus.

Technique

Patient position

Standing or sitting on the edge of a treatment couch.

Clinician position

Standing on the affected side facing the patient.

Action

The shoulder is passively elevated to 90° in the scapular plane and taken into full internal rotation with the forearm in pronation so that the thumb is pointing to the floor (empty can test, Fig. 2.3). The clinician stabilizes the scapula with one hand and places the other on the upper surface of the patient's forearm. Downward pressure is then applied to the arm while the patient maintains this position. The test is then repeated with the arm externally rotated so that the thumb points upwards (full can test, Fig. 2.4).

Positive test

Reproduction of the patient's pain without weakness is suggestive of supraspinatus impingement or tendinopathy while painful weakness may indicate a partial or complete tear.

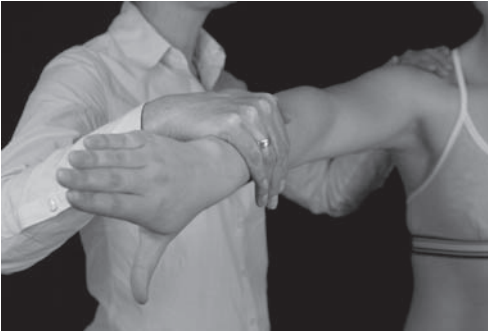

Fig. 2.3 • Empty can test.

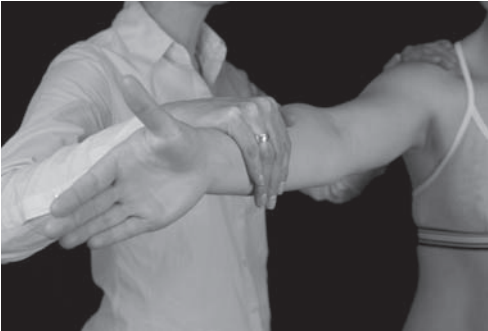

Fig. 2.4 • Full can test.

Clinical context

In an EMG study of normal subjects, the empty can and full can tests were shown to preferentially activate supraspinatus with the least co-activation of other muscles. The full can test was originally described in the context of strength assessment, not pain provocation (Kelly et al 1996). Itoi et al (1999) compared the tests' accuracy in diagnosing full thickness tears of supraspinatus and found them to be broadly equivalent. For strength assessment, however, the full can test is probably preferable, because its position is less likely to cause painful impingement and consequent inhibition (Itoi et al 1999) (Tables 2.3–2.5).

TABLE 2.3 PAIN ON THE TEST

Author and year	Empty can		Full can		Target condition
	LR+	LR-	LR+	LR-	
Leroux et al 1995	1.72	2.8			Shoulder impingement syndrome
Itoi et al 1999	1.40	0.67	1.83	0.53	Full thickness tear of supraspinatus

TABLE 2.4 WEAKNESS ON THE TEST

Author and year	Empty can		Full can		Target condition
	LR+	LR-	LR+	LR-	
Hertel et al 1996	2.00 ★	0.38 ★			Partial or full thickness tear of the postero superior rotator cuff
Itoi et al 1999	2.40 ★	0.34 ★	2.96 ★	0.31 ★	Full thickness tear of supraspinatus

TABLE 2.5 PAIN OR WEAKNESS OR BOTH

Author and year	Empty can		Full can		Target condition
	LR+	LR-	LR+	LR-	
Holtby & Razmjou 2004	1.36	0.84			Full thickness tear of supraspinatus
Itoi et al 1999	1.78	2.2	2.00 ★	0.25 ★	Full thickness tear of supraspinatus

Clinical tip

Weakness in the absence of any pain may result from a C5 palsy, suprascapular neuropathy or Parsonage–Turner syndrome, a viral neuritis affecting the brachial plexus.

EXPERT OPINION	COMMENTS
★★★	Empty/full can test Gives a good indication of a cuff tear or impingement.

Related tests

In his seminal book on the shoulder, Codman (1934) vaguely described a test which has since become known as *Codman's test* or the *drop arm test*. If positive it is suggestive of a full thickness tear of the rotator cuff with the supraspinatus tendon the most likely culprit. Conventionally, the patient is asked to actively lower the arm, under control, from above 90° in the sagittal plane. He or she will be unable to do so if supraspinatus is completely ruptured; instead, the arm will drop.

External rotation lag sign

Aka

Infraspinatus spring back test

Purpose

To assess the integrity of the infraspinatus tendon and expose weakness associated with suprascapular neuropathy.

Technique

Patient position

Sitting or standing with the affected arm in a dependent position with the elbow flexed to 90°.

Clinician position

The clinician stands adjacent to the affected side, using one hand to support the patient's elbow and the other to take hold of the patient's arm just above the wrist. The shoulder is passively elevated 20° in the scapular plane, then taken to about 5° short of full external rotation (Fig. 2.5A).

Action

Still supporting the patient's elbow, the tester asks the patient to maintain the external rotation, and then releases the wrist (Fig. 2.5B).

Positive test

A positive test is recorded if the patient is unable to maintain the rotated position and there is a 'lag' or 'spring back' towards the start position.

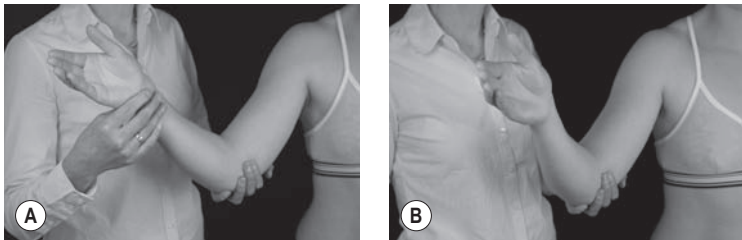


Fig. 2.5 • Starting position of external rotation lag sign with the shoulder held passively in position (A). A positive test is indicated by the arm 'springing back' towards the neutral position as the clinician releases the wrist (B).

Clinical context

A lag of 5–10° may indicate a complete tear of infraspinatus or supraspinatus. A 10–15° lag is strongly suggestive of a tear of both tendons or may result from neuropathy. This sign is one of several lag signs used to identify and evaluate rotator cuff tears as opposed to painful tendinopathies (Hertel et al 1996).

The diagnostic accuracy of the external rotation lag sign (ERLS) was evaluated in 87 patients with either a partial or complete rupture of supraspinatus, infraspinatus, a combination of both or a massive cuff tear (also involving the subscapularis) and a sensitivity of 70% and a specificity of 100% were reported (Hertel et al 1996; Table 2.6).

TABLE 2.6 EXTERNAL ROTATION LAG SIGN

Author and year	LR+	LR–	Target condition
Hertel et al 1996	>70.00 ★★★	0.30 ★	Partial or full thickness tear of the postero superior rotator cuff

Clinical tip

According to the test's originators, a lag as small as 5° may be detectable with practice, especially on the basis of a contralateral

comparison. However, they caution against false positive and negative results due to reduced (e.g. capsular limitation) or increased (e.g. supraspinatus rupture) range of movement. Suprascapular palsy would also give a false positive result for cuff rupture.

The mechanism of rotator cuff degeneration is such that the presence of an infraspinatus tear is very likely to be accompanied by a rupture to the supraspinatus tendon. It is therefore necessary to fully evaluate the integrity of the whole rotator cuff using the associated special tests and further investigations if appropriate.

EXPERT OPINION	COMMENTS
★★★	<p>External rotation lag sign</p> <p>Used regularly to assess the rotator cuff providing the patient has enough range of external rotation to adopt the start position without pain.</p>

Variations

The *drop sign* repeats the ERLS in 90° of abduction in the scapular plane (Hertel et al 1996). Again, an inability to maintain the position signifies an infraspinatus tear or neuropathy. This test is unsuitable for patients with stiff shoulders (Table 2.7).

TABLE 2.7 DROP SIGN

Author and year	LR+	LR-	Target condition
Hertel et al 1996	>21.00 ★★★	0.79	Partial or full thickness tear of the postero superior rotator cuff

The '*signe de Clairon*' or *Patte's test* is a variation of the drop sign and is intended to isolate lesions of the smaller external rotator of the shoulder, teres minor. The patient's shoulder is placed in the same start position but the examiner, standing on the affected side and slightly behind the patient, stabilizes the flexed elbow and adds resistance to external rotation by placing the other hand on the posterior aspect of the lower forearm. A positive test, pain and/or weakness, is thought to indicate a tear of teres minor although,

because infraspinatus is largely inseparable anatomically and functionally, an isolated tear is improbable.

The *hornblower's sign* is an indication of major posterior cuff disruption, i.e. a tear of infraspinatus and teres minor. The patient is unable to externally rotate the abducted arm so when asked to take both hands simultaneously to the mouth (as if holding a wind instrument) the position cannot be maintained on the affected side and the shoulder falls into an internally rotated position. The same demands on the rotator cuff are made by the professional darts player, who requires a combination of abduction and external rotation to position the shoulder in preparation for throwing a dart.

Lift-off sign

Aka

Gerber's test

Gerber's lift-off test

Internal rotation lag sign

Medial rotation 'spring back' test

Purpose

To test for a partial or complete tear of subscapularis.

Technique

Patient position

Standing or sitting on the edge of a treatment couch with the shoulder internally rotated so that the dorsum of the hand rests against the mid-lumbar spine.

Clinician position

Standing behind the patient, the distal end of the patient's forearm is lifted away from the lumbar spine, so that the shoulder is fully internally rotated.

Action

With the arm passively 'lifted off', the patient is asked to maintain the position without extending the elbow as the support of the clinician's hand is removed.

Positive test

An inability to maintain the lifted-off position signifies a complete tear of the subscapularis tendon.

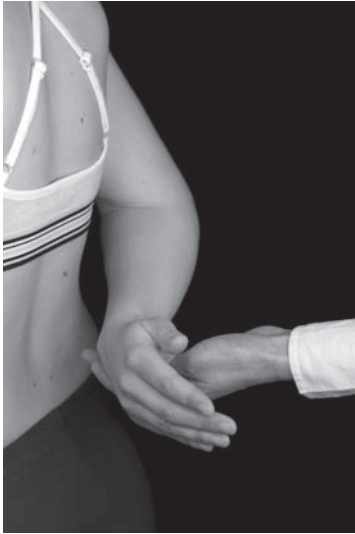

Fig. 2.6 • Starting position of the lift-off sign.

Clinical context

Kelly et al (1996) reported Gerber's 'lift-off' position (Gerber & Krushell 1991) to be optimal for subscapularis contraction and this was supported by another study which demonstrated that the upper and lower subscapularis could produce a 70% maximal voluntary contraction when tested in this position while the other muscles (posterior deltoid, pectoralis major, infraspinatus, latissimus dorsi, teres major and serratus anterior) showed significantly lower levels of activity ($P_{0.05}$). The test performed with the hand in the mid-lumbar spine produced one third more EMG activity than with the hand over the sacrum. When resistance was added to the standard test (see Gerber push-off test below), there was an increase in the activity of all muscles, though only a small increase in the activity of the pectoralis major muscle (which was significantly more active during resisted internal rotation with the arm at the front of the body) (Greis et al 1996).

In contrast, however, EMG and nerve block analysis were used to evaluate the activity of the subscapularis tendon in four positions (of increasing degrees of internal rotation), although none of these tested positions were the same as that originally defined by Gerber. EMG activity was identified in latissimus dorsi, posterior deltoid, the rhomboids as well as subscapularis in what was described inaccurately

as the conventional test position. With a subscapular nerve block in place the subjects were still able to perform the 'lift-off' sign, casting doubt over the validity of the test. The only tested position that could not be maintained with the nerve block in place was in maximum internal rotation, leading the authors to propose the *maximum internal rotation lift-off test* to be optimum for the detection of subscapularis tears (Stefko et al 1997). However, the original test position (with the hand at the mid-lumbar level) was not evaluated and, when taken alongside the fact that the maximum internal rotation position is unattainable for many patients, the clinician should be wary about discarding the original test in favour of this variant.

The original study that reported the *lift-off sign* demonstrated high levels of sensitivity and specificity although the authors conceded that the validity of the test is reliant on the existence of full passive internal rotation and that active range is not significantly limited by pain. An inability to 'lift-off', increased external rotation range and weakness of internal rotation were all reported to be indicative of a full thickness tear of subscapularis (Gerber & Krushell 1991). In contrast, an independent evaluation of its diagnostic accuracy in a larger population, reported lower levels of sensitivity and specificity (Kim et al 2003b). This highlights a tendency in the literature for originators of diagnostic tests to report higher levels of sensitivity and specificity than independent assessors; this may be due to various factors including differing levels of technical proficiency in applying and interpreting the test.

TABLE 2.8 LIFT-OFF SIGN

Author and year	LR+	LR-	Target condition
Hertel et al 1996	62 ★★★	0.38 ★	Any lesion (including ruptures, whether partial or complete) of subscapularis
Gerber & Krushell 1991	88 ★★★	0.12 ★★	Full thickness tear of subscapularis
Kim et al 2003b	1.70	0.92	Full thickness tear or joint side partial thickness tear of subscapularis
Leroux et al 1995	0.00	1.64	Any lesion of subscapularis

Clinical tip

A partial tear is denoted by a limited ability to maintain the lifted-off position, such that the arm drops back less than 5° (Gerber et al 1996, Hertel et al 1996).

If there is inadequate range to perform the *lift-off sign*, the alternative *belly-press test* (see Variations) may be used to identify weakness of the subscapularis tendon.

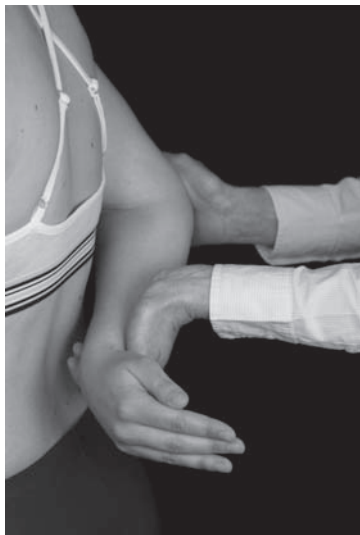EXPERT OPINION	COMMENTS
★★★	<p>Lift-off sign</p> <p>Gives a good indication of a subscapularis tear, particularly if there are only subtle signs on examination. However, many patients with impingement and cuff pathology find the degree of internal rotation painful, which limits its usefulness in patients with significant/acute pain or with limited shoulder range.</p>

Variations

The *belly-press test* or *Napoleon test* has the patient seated with the palm of the hand pressing against the abdomen while keeping the shoulder in full internal rotation. The test is positive if this position cannot be maintained and the elbow swings posteriorly as the patient attempts to compensate by pulling the hand against the abdomen (Gerber et al 1996). In a study of 25 patients listed for surgical repair of the subscapularis tendon, the findings of the *belly-press test* pre-operatively were compared with the findings in theatre (Burkhart & Tehrany 2002). Of nine patients with positive tests, eight had complete tears. Positive tests correlated with full thickness, full-width tears of the tendon while negative tests were recorded in patients whose tears only involved the upper half of the tendon. As a modification, the clinician interposes one hand between the patient's hand and the abdomen so that the amount of pressure the patient is able to exert can be gauged, although its value is speculative. Some clinicians modify further by bringing the elbow forward into the scapular plane, thereby increasing the degree of internal rotation while ensuring the patient keeps the wrist in a neutral position.

The *Gerber push-off test* (Kelly et al 1996) may be used if the patient is able to maintain the 'lift-off' position. The patient is asked to maintain the lift-off position while the clinician applies an anteriorly directed force against the lower forearm (Fig. 2.7). This

Fig. 2.7 • Gerber push-off test: isometric contraction of subscapularis.



supplementary isometric action preferentially activates subscapularis (Kelly et al 1996) and is a pain-provocative manoeuvre.

B IMPINGEMENT TESTS

Neer's sign

Aka

Forward flexion impingement test

Purpose

The primary purpose of the sign is to identify symptomatic subacromial impingement involving the rotator cuff, subacromial bursa and long head of biceps.

Technique

Patient position

Sitting or standing with the arm in the anatomical position.

Clinician position

The clinician stands on the affected side and stabilizes the scapula with one hand and grasps the arm below the elbow with the other hand.

Action

The arm is then passively elevated into full flexion with the scapula stabilized.

Positive test

Pain is reproduced at the end of the passive elevation movement.

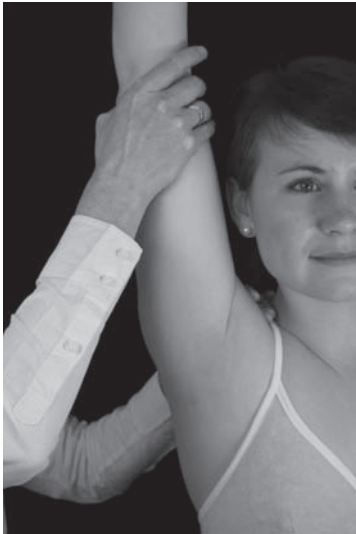

Fig. 2.8 • Neer's sign.

Clinical context

In a cadaveric study, Neer (1972) noted a potential for impingement between the acromion and supraspinatus, infraspinatus and the long head of biceps with the arm in the test position in approximately 10% of specimens. He cautioned that while his sign could signify impingement, there were many other conditions that could also provoke pain during the manoeuvre and that full elevation and external rotation range should be present to eliminate the presence of capsulitis and reduce the possibility of recording false positive findings (Neer 1983, Neer & Welsh 1977). Neer recommended that the sign was re-evaluated after subacromial injection of local anaesthetic and, if the pain was relieved (a positive *Neer's test*), a diagnosis of subacromial impingement could be made.

In a much more detailed cadaveric study (Valadie et al 2000), Neer's manoeuvre was also shown to consistently bring the subacromial soft tissues, including the long head of biceps, into contact with the coraco-acromial arch (subacromial impingement) and the internal aspects of supraspinatus and infraspinatus into contact with the glenoid rim (internal impingement), a finding confirmed in a large arthroscopic study which identified internal impingement in 74% of shoulders that had tested positive to Neer's sign (Kim & McFarland 2004). According to other cadaveric studies (Flatow et al 1994, Jobe 1997) and an MRI evaluation of normal subjects (Roberts et al 2002), performing Neer's sign in the scapular plane appears to cause more internal impingement, although clinically no study has demonstrated higher levels of sensitivity or specificity in the diagnosis of subacromial impingement by altering the plane of elevation (Kim & McFarland 2004, Naredo et al 2002, Parentis et al 2002, 2006).

Neer himself regarded his eponymous sign as uninformative unless it was abolished by injection of local anaesthetic under the acromial arch. Several studies have evaluated the diagnostic accuracy of Neer's sign (Kim & McFarland 2004, MacDonald et al 2000, Parentis et al 2002, 2006) for a range of shoulder pathology, overlooking its origin as an impingement test as well as failing to evaluate *Neer's confirmatory test*. The work done by Suder et al (1994), however, allowed head to head comparison of both sign and test in the same sample of patients. For each target condition of interest, performing the test *after* the sign resulted in decreased sensitivity and increased specificity, however, it was only in relation to full thickness tears that a positive sign and test provided sufficiently strong evidence to rule in the diagnosis with some degree of confidence.

Types of impingement (Magee 2008)

Primary (outlet)

Mechanical compression of the bursal/superior side of the rotator cuff mainly involving the supraspinatus tendon. Because the impingement occurs anteriorly around the supraspinatus outlet region, primary impingement is sometimes known as anterior or outlet impingement syndrome

Intrinsic

e.g. degeneration of the cuff

Extrinsic

e.g. where the shape of the acromion negatively impacts on the ability of

Neer described three stages of primary impingement characterised by:

Stage I reversible oedema and haemorrhage of the rotator cuff often seen in the younger patient.

Stage II fibrosis occurring as a result of the ageing and degenerative process, and,

Stage III bone spur development & tendon rupture

the greater tuberosity and cuff tendons to navigate under the coraco-acromial arch without impingement

Secondary (outlet)

Caused by weak or imbalanced muscles leading to instability of the scapulohumeral complex which in turn results in abnormal movement patterns and anterior impingement

Internal (non-outlet)

Results from injury to the undersurface of the rotator cuff or the glenoid labrum caused by impingement of the supraspinatus and infraspinatus tendons between the posterosuperior aspect of the glenoid rim and the humeral head. The impingement occurs posteriorly and is sometimes known as non-outlet impingement

TABLE 2.9 NEER'S SIGN

Author and year	LR+	LR-	Target condition
Suder et al 1994	2.5 ★	0.19 ★★	Full thickness tear of rotator cuff
Suder et al 1994	0.73	1.27	Labral tear
Suder et al 1994	1.93	0.51	Joint side partial thickness tear of rotator cuff

TABLE 2.10 NEER'S TEST

Author and year	LR+	LR-	Target condition
Suder et al 1994	0.00	1.11	Labral tear
Suder et al 1994	7.50 ★★	0.89	Full thickness tear of rotator cuff

Clinical tip

Having established the presence of impingement at the shoulder, the clinician can then evaluate further to establish whether this is an internal or primary impingement (see posterior impingement test, p. 44, internal rotation resistance strength test, p. 42) as well as ascertaining any predisposing factors such as abnormal kinematics resulting from poor muscle control or labral injury (see crank test, p. 46).

EXPERT OPINION	COMMENTS
★★	<p>Neer's sign/test</p> <p>This helps to form part of the total picture but is non-specific. If other tests, including ultrasonography, have been inconclusive, using local anaesthetic as a confirmatory test can be useful.</p>

Variations

Many clinicians modify Neer's manoeuvre by maintaining internal rotation at the shoulder throughout elevation (*flexion-internal rotation test*). Although the intention is to position the insertions of both supraspinatus and infraspinatus so that they are more vulnerable to subacromial compression, an open MRI study of normal subjects showed that this position consistently resulted in internal rather than subacromial impingement (Jobe 1996).

Although speculative, further differential testing can be used to make a distinction between pain predominantly emanating from the cuff or bursa. Given their anatomical intimacy this is challenging, but pain arising from isometric testing of the supraspinatus and infraspinatus may lessen when the tests are repeated under distraction if the bursa is the main culprit due to the decompression effect in the subacromial area. For resisted abduction (supraspinatus) the patient is supine, distraction is applied in a neutral position, counterpressure applied on the opposite hip while resistance to isometric abduction of the shoulder is applied at the elbow (Fig. 2.9). For resisted external rotation (infraspinatus) the same principles are applied; the upper arm is wedged between the patient's waist and the examiner's thigh and the elbow flexed to 90°. The examiner then interlocks the elbow with the patient's to apply the distraction, while the outer hand is placed on the lateral border of the lower forearm to provide resistance (Fig. 2.10).

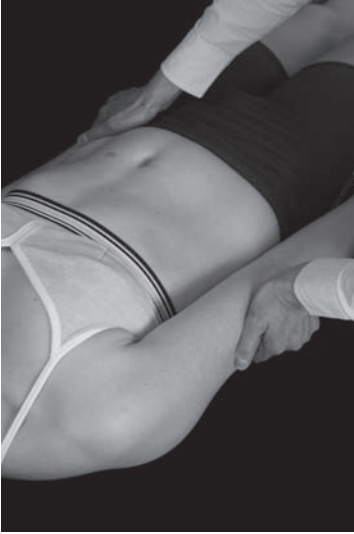

Fig. 2.9 • Resisted shoulder abduction under distraction.

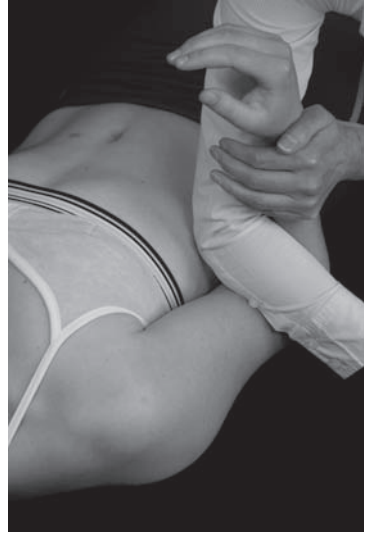

Fig. 2.10 • Resisted shoulder external rotation under distraction.

Hawkins–Kennedy impingement test

Aka

Hawkins impingement test

Purpose

The primary purpose of the test is to identify subacromial or internal impingement.

Technique

Patient position

Sitting or standing with the arm relaxed in the anatomical position.

Clinician position

Standing adjacent to the patient on the affected side, one hand is placed under the elbow, the other holds just above the wrist. The elbow is flexed to 90° and the shoulder taken passively into 90° of forward flexion.

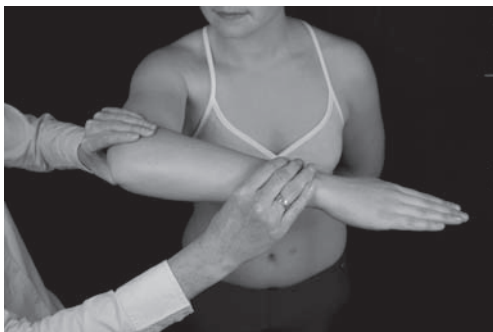Action

The shoulder is passively taken into internal rotation thereby rotating the greater tuberosity under the coracoacromial arch.

Positive test

Pain is reproduced increasingly towards the end of the rotation movement and indicates rotator cuff pathology involving the cuff itself, the adjacent bursa or the long head of biceps. The glenoid labrum is also vulnerable in this test.

Fig. 2.11 • Hawkins–Kennedy impingement test.



Clinical context

MRI analysis shows that the Hawkins–Kennedy impingement test brings the rotator cuff insertions against the acromion (Roberts et al 2002) so the subacromial bursa, overlying the tendons, must also be compressed in this position. A cadaveric study also showed that the bursal side of the cuff is very likely to contact the acromion or coraco-acromial ligament. In two of four specimens the bursal side of the cuff contacted the acromion; in all four the bursal side of the cuff or the long head of biceps contacted the coraco-acromial ligament; and in one of the four, subscapularis was distorted by the coracoid (Valadie et al 2000).

The Hawkins–Kennedy test may also have a role in identifying internal impingement, as it has been shown to cause pinching of the internal aspect of the damaged rotator cuff (particularly subscapularis) against the glenoid labrum (Struhl 2002, Valadie et al 2000).

TABLE 2.11 HAWKINS-KENNEDY IMPINGEMENT TEST

Author and year	LR+	LR–	Target condition
MacDonald et al 2000	1.65	0.19 ★★	Subacromial bursitis
Naredo et al 2002	2.38 ★	0.48 ★	Subacromial impingement and subacromial bursitis
Kim & McFarland 2004	0.97	1.10	Internal impingement in flexion
Kim et al 2003a	1.14	0.77	Any SLAP lesion
Parentis et al 2002, 2006	0.94	1.15	Unstable SLAP lesion
Kim et al 2003b	0.88	1.20	Full thickness tear or joint side tear of subscapularis

SLAP = superior labral anterior posterior

Clinical tip

A positive result is highly likely in the presence of a capsulitis which should therefore be excluded to avoid a false positive result.

EXPERT OPINION	COMMENTS
★★★	<p>Hawkins-Kennedy impingement test</p> <p>Used regularly but its lack of specificity means it can be positive not only in impingement problems but also acromioclavicular joint pathology and even posterior instability.</p>

Related tests

The *coracoid impingement sign* is a modification of this test and is thought to increase the contact between the lesser tuberosity and the coracoid process during the manoeuvre. The arm is taken into the same start position but 10–20° of horizontal adduction is added before applying the internal rotation component.

Internal rotation resistance strength test

Purpose

To distinguish between primary impingement and internal impingement following a positive Neer's sign/test.

Technique

Patient position

Standing or sitting.

Clinician position

The clinician stands adjacent to and slightly behind the patient. The patient's elbow is flexed to 90°, the shoulder abducted to 90° and externally rotated to approximately 80°. The weight of the arm is supported throughout the test by the clinician's hand placed under the patient's elbow. The free hand is placed over the dorsum of the lower forearm in order to apply resistance to external rotation.

Action

An isometric test to external rotation is first carried out by the patient with resistance applied by the clinician (Fig. 2.12). The clinician's hand then swaps onto the palmar aspect of the wrist and isometric internal rotation is performed (Fig. 2.13). This is a test of *comparative* strength of internal and external rotation and so the unaffected arm does not need to be tested.

Positive test

Comparative weakness of internal rotation represents a positive test and is suggestive of internal impingement. If internal rotation is stronger, primary impingement should be suspected.

Clinical context

Primary impingement occurs as a result of mechanical compression of the bursal/superior side of the rotator cuff, mainly involving the supraspinatus tendon. Internal impingement results from injury to the undersurface of the rotator cuff or the glenoid labrum caused by impingement of the supraspinatus and infraspinatus tendons between the posterosuperior part of the glenoid rim and the humeral head when the arm is abducted to 90° and fully externally rotated. The condition is most common in the athlete involved in overhead throwing events (see Fig. 2.8).



Fig. 2.12 • Isometric external rotation.

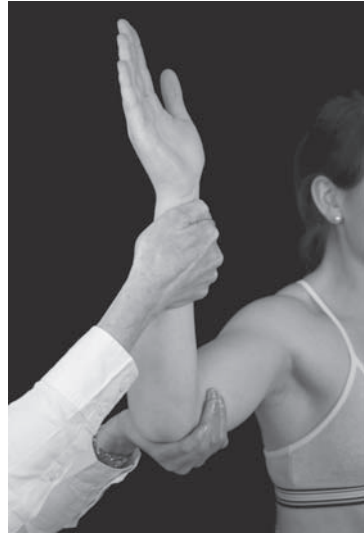

Fig. 2.13 • Isometric internal rotation.

A group of 115 patients, all of whom had a positive Neer's sign, were secondarily tested using the internal rotation resistance strength test (IRRST) prior to arthroscopy. Patients with confirmed internal impingement on arthroscopy who had a positive IRRST gave a sensitivity of 88% and those with primary impingement on arthroscopy with a negative IRRST showed a specificity of 96%, suggesting that a positive test provides strong evidence for the presence of internal impingement with a negative test indicating its absence (Zaslav 2001).

TABLE 2.12 INTERNAL ROTATION RESISTANCE STRENGTH TEST

Author and year	LR+	LR-	Target condition
Zaslav 2001	22.25 ★★★	0.11 ★★	Internal vs subacromial impingement

Clinical tip

The test is easy to perform although further investigations may be required to assist the clinician in differentiating the type of impingement.

Posterior impingement test

Purpose

To test for internal impingement between the undersurface of the rotator cuff and the posterosuperior part of the glenoid labrum.

Technique

Patient position

Lying supine towards the edge of the couch.

Clinician position

Standing adjacent to the patient, the clinician takes the affected shoulder passively to approximately 100° of abduction and about 10° extension, supporting the elbow with one hand and the lower forearm with the other.

Action

The shoulder is passively taken into full external rotation.

Fig. 2.14 • Posterior impingement test.



Positive test

Pain felt deeply in the posterior aspect of the shoulder may indicate posterior impingement.

Clinical context

Posterior internal impingement can occur in people who repeatedly position their arm in a combination of 90° abduction and external rotation (e.g. swimmers, throwers, painters and decorators), particularly where high load and velocity are involved. This position causes the articular aspect of the rotator cuff tendons to become pinched between the humeral head and the posterosuperior part of the glenoid labrum. The internal rotation resistance strength test (see p. 42) can help in making a distinction between internal and primary impingement.

Clinical tip

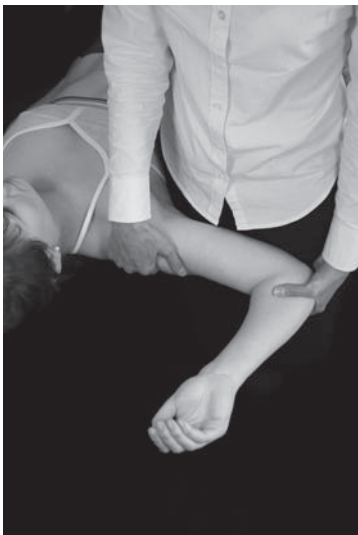Internal impingement can occur in conjunction with shoulder instability, the test position being very similar to the apprehension test (see p. 56) (Jobe et al 1989), so a positive test should be interpreted in the light of the patient's history and other examination findings.

EXPERT OPINION	COMMENTS
★★	<p>Posterior impingement test</p> <p>Diagnosis of internal impingement based on clinical examination alone is difficult and MRI/arthroscopy are usually required to make a definitive diagnosis.</p>

Variations

The *modified subluxation/relocation test* for posterosuperior glenoid impingement (Hamner et al 2000) is conducted in three positions of abduction: 90°, 100° and 120°. In each position the clinician applies an anterior, then a posterior force to the patient's upper humerus. A positive response for posterosuperior glenoid impingement is pain (not apprehension) on the anteriorly directed force, which is relieved when the force is directed posteriorly (Fig. 2.15).

Fig. 2.15 • Modified subluxation/relocation test with an anteriorly directed force in 90° abduction.



C LABRAL TESTS

Crank test

Aka

Labral crank test

Compression rotation test

Purpose

To assess for an unstable superior labral anterior posterior (SLAP) lesion.

Technique

Patient position

Supine or sitting with the elbow flexed to 90°.

Clinician position

Standing adjacent to the affected shoulder, holding the patient's flexed elbow and forearm.

Action

The patient's arm is passively elevated in the scapular plane to full range. While applying a gentle axial load through the longitudinal axis of the humerus, the shoulder is taken into full external (Fig. 2.16A) and then internal (Fig. 2.16B) rotation using the forearm as a lever.

Positive test

The patient's pain, a catching sensation, painful clicking or a combination of these are considered positive indicators of a labral tear and are most likely to be elicited during the external rotation part of the test.

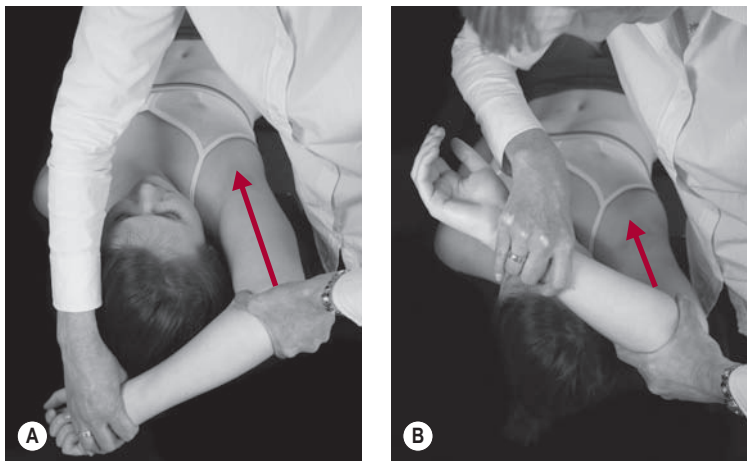


Fig. 2.16 • Crank test in external rotation (A) and internal rotation (B). Arrows indicate direction of axial compression.

Clinical context

The glenoid labrum can be damaged at various parts of its circumference. Bankart lesions occur anteriorly as a result of anterior dislocations of the shoulder, GLAD (gleno-labral articular disruption) lesions occur antero-inferiorly through a forced adduction injury from an abducted and externally rotated position (Nevasier 1993) and the commonly reported SLAP lesions involve the superior labrum. Advances in imaging and arthroscopic techniques have improved the accuracy of labral injury identification, even allowing natural

variants of the labrum to be distinguished from true tears (Liu et al 1996). SLAP lesions have been graded as follows (Snyder et al 1990):

Type	SLAP definition
I	There is fraying of the superior labrum which is probably degenerative and usually asymptomatic
II	The superior labrum and attached long head of biceps have become detached from the glenoid
III	There is a bucket-handle tear of the superior labrum, and the 'handle' can fold in on itself and displace into the joint
IV	Similar to type III, except that the long head of biceps is attached to the 'handle'; consequently, when the handle displaces into the joint, the proximal end of the biceps tendon goes in with it

A tear in the glenoid labrum is the most frequent cause of the 'clicking' shoulder, when accompanied by pain and a loss of function, particularly in the younger patient. The onset of symptoms often occurs as a result of repeated overarm sporting activities causing fatigue of the stabilizing cuff muscles, which then allows excessive translation of the humeral head over the labrum, resulting in a tear. The forceful eccentric contraction of the biceps during throwing (in which the biceps is attempting to decelerate the rapidly extending elbow) is also a known mechanism of injury (Andrews et al 1985). Trauma, such as a fall on an outstretched arm where the superior labrum becomes 'trapped', can also generate symptoms.

There is a strong correlation between labral tears and other symptoms at the shoulder (Liu et al 1996). In an arthroscopic study of 100 shoulders, 68% of patients with impingement symptoms were found to have superior labral tears whereas 92% of patients with recurrent anterior instability had antero-inferior tears identified (Hurley & Anderson 1990).

Patients with functional instability report catching and locking of the shoulder during movement and feel unable to 'trust' their shoulder, particularly when loading the arm in elevated positions. It is thought that these symptoms result from the partially attached labral fragment becoming temporarily interposed between the articulating surfaces of the glenoid and humeral head, thereby

giving the transient but functionally impairing symptoms (Pappas et al 1983).

The crank test combines axial loading with rotation movements and is broadly analogous to McMurray's test at the knee. The first researchers to evaluate it were its originators (Liu et al 1996), who reported a very high sensitivity and specificity, commensurate with impressive positive and negative likelihood ratios. On this basis, the crank test would be a very useful clinical tool, both in terms of a positive result ruling a SLAP lesion in and of a negative result ruling one out. Unfortunately these promising results have not been replicated in subsequent, independent studies (Guanche & Jones 2003, Parentis et al 2006, Stetson & Templin 2002). In spite of this, the crank test remains popular among clinicians.

For the purposes of reporting, the following distinctions have been made in order to accurately represent the research relating to labral testing:

Type	Labral injury definition
Labral injury	The study specifies a labral lesion but not a SLAP lesion specifically as the target condition
Unstable SLAP lesion	The study specifies type II, III or IV or any combination of these as the target condition
Any SLAP lesion	The study specifies SLAP lesions as the target condition, but does not specify a type

TABLE 2.13 CRANK TEST

Author and year	LR+	LR-	Target condition
Liu et al 1996	13.00 ★★★	0.10 ★★	Labral injury
Stetson & Templin 2002	0.96	1.04	Labral injury
Guanche & Jones 2003	1.18	0.91	Any SLAP lesion
Parentis et al 2002, 2006	0.53	1.10	Any SLAP lesion

SLAP = superior labral anterior posterior

Clinical tip

Controlling the compression element of the test is likely to be easier with the patient supine.

EXPERT OPINION	COMMENTS
★★	<p>Crank test</p> <p>Taken in the context of the patient's history and other physical findings, this test is helpful, although MRI or arthroscopy is usually needed to identify the type of SLAP lesion.</p>

Variations

The *clunk test* predated the crank and has subsequently been superseded by this more reliable variation. Descriptions of the clunk test varied widely, making reliable reproduction and analysis difficult. With the patient lying supine, the shoulder is abducted to about 160° ensuring that the upper arm is supported on the couch in order to help control the movement. An anterior force is applied on the posterior aspect of the humeral head as external and internal rotation movements are gently applied using the flexed elbow as a lever. As the rotation movement is applied the patient may feel a 'clunk' as the humeral head rotates over the disrupted or detached labrum and this may elicit pain and/or apprehension. Different sections of the labrum can be stressed by altering the degree of abduction during the test and although this cannot accurately localize a tear, a positive finding at any point through this range would increase the index of suspicion for a labral injury.

The *compression/circumduction test* keeps the shoulder at 90° abduction with the elbow flexed to 90°. A compressive force is applied along the line of the humerus while circumduction is carried out, producing a scouring action on the labrum. A positive test reproduces the patient's familiar pain and/or a clunk.

Biceps load II test

Purpose

To assess for an unstable superior labral anterior posterior (SLAP) lesion.

Technique

Patient position

Lying supine towards the side of the couch.

Clinician position

Standing adjacent to the affected shoulder, the patient's elbow is flexed to 90° and with one hand placed just above the elbow joint and the other supporting the lower forearm, the arm is abducted to 120° before full external rotation is applied. The forearm is positioned in as much supination as possible in order to achieve maximum stress on the long head of biceps tendon during testing.

Action

Isometric resistance is given to elbow flexion in this position.

Positive test

Shoulder pain provoked by resisted elbow flexion.

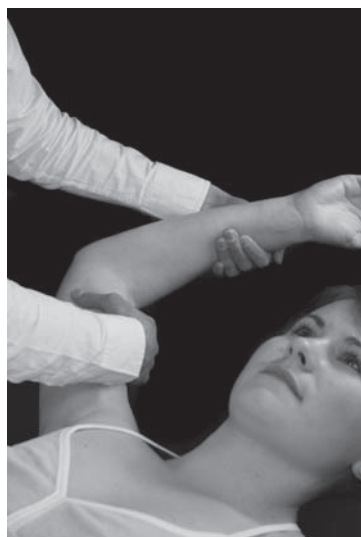

Fig. 2.17 • Biceps load II test.

Clinical context

According to Kim et al (2001), the starting position for the biceps load II test creates an oblique angle between the long head of biceps

tendon and the posterosuperior glenoid labrum, accentuating the pain caused when the muscle contracts and simultaneously pulls on its attachment at the labrum. Indeed, the test replicates the winding up action prior to a throw, one of the mechanisms by which SLAP lesions are believed to be produced (Burkhart & Morgan 1998).

See the crank test for further labral clinical context (p. 46).

TABLE 2.14 BICEPS LOAD II TEST

Author and year	LR+	LR–	Target condition
Kim et al 2001	30.00 ★★★	0.10 ★★	Any SLAP lesion

SLAP = superior labral anterior posterior

EXPERT OPINION	COMMENTS
★★	<p>Biceps load II test</p> <p>The labral tests can only be used accurately if the patient is able to relax sufficiently to attain the starting position of the test.</p>

Anterior slide test

Purpose

To assess for an unstable superior labral anterior posterior (SLAP) lesion.

Technique

Patient position

Standing or sitting with the hand resting on the waist (iliac crest) with the thumb directed backwards.

Clinician position

Standing behind the patient, one hand is placed over the top of the scapula to stabilize while the other hand cups the elbow.

Action

The patient is instructed to keep the arm exactly where it is and resist the pressure applied by the examiner which comes from a

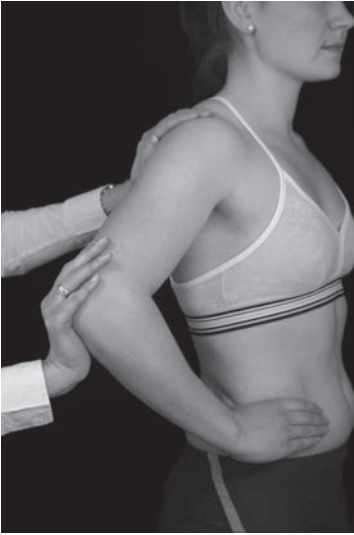

Fig. 2.18 • Anterior slide test.

combined anterior and superiorly directed force applied by the hand on the patient's elbow.

Positive test

If torn, the superior labrum is unable to resist forward displacement of the humerus as the force is applied and either apprehension is evoked or the humeral head shifts anteriorly causing pain and/or a click at the front of the shoulder as it rides over the labral tear. This will be reminiscent of the symptoms provoked by functional movements such as overarm activity.

Clinical context

In studies where the test was evaluated pre-arthroscopically, it was found to be highly specific for superior labral lesions (Kibler 1995, Parentis et al 2006). Overhead athletes often have reduced active and passive internal rotation of the shoulder. This limitation enhances the anterior translation of the humeral head during the test, which then exposes the superior labrum and biceps origin to further stress, making it a useful additional test for this category of patient.

Its originator (Kibler 1995) recommended against relying on its findings completely and suggested that it should be used in

TABLE 2.15 ANTERIOR SLIDE TEST

Author and year	LR+	LR–	Target condition
Kibler 1995	9.75 ★★	0.24 ★	Unstable SLAP lesion
Parentis et al 2002, 2006	0.81	1.04	Any SLAP lesion

SLAP = superior labral anterior posterior

conjunction with other special tests (crank, p. 46; active compression, p. 76; SLAP prehension, p. 54; and biceps II load, p. 50, tests) and in the light of the patient's history.

See the *crank test* for further labral clinical context (p. 46).

Clinical tip

According to its originator, this test is not difficult to learn, because it does not require accurate positioning (Kibler 1995).

SLAP prehension test

Aka

Slapper test

Purpose

To assess for an unstable superior labral anterior posterior (SLAP) lesion.

Technique

Patient position

Standing or sitting.

Clinician position

Standing adjacent to the affected arm and observing the patient's response to the test. The clinician can place their hand over the shoulder to palpate for a click.

Action

The patient elevates the affected shoulder in the scapular plane to 90°, with the elbow extended and the forearm fully pronated, and

horizontally adducts the arm across the chest (Fig. 2.19A). The presence of pain is noted and the arm is returned to the abducted start position. The same movement is then repeated with the forearm in supination and any pain noted (Fig. 2.19B).

Positive test

Localized anterior shoulder pain, sometimes combined with an audible or palpable click that is *more* pronounced during the first test, is suggestive of an unstable SLAP lesion.

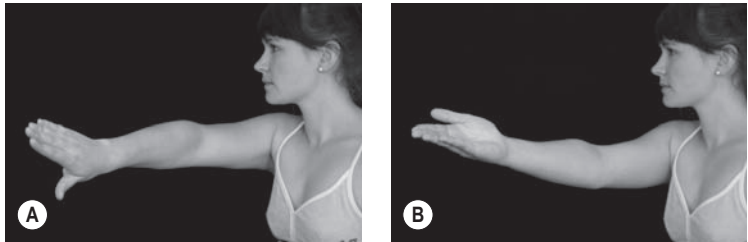


Fig. 2.19 • SLAP prehension test in pronation (A) and supination (B).

Clinical context

This test supposedly replicates the action of turning a steering wheel—the activity two patients reported as reproducing their shoulder pain (Berg & Ciullo 1998). Their shoulders were evaluated further in theatre and both were found to have unstable SLAP lesions. The test was seen to cause the proximal part of the long head of biceps, and the labral fragment to which it was connected, to flip into the joint. This caused the test's originators to postulate that the horizontal adduction movement has the capacity to trap an unstable biceps tendon and its labral fragment between the glenoid fossa and the head of the humerus. The pronation component increases the strain (and therefore pain) through the long head of biceps tendon with supination having the opposite effect (Berg & Ciullo 1998).

See the crank test for further labral clinical context (p. 46).

Clinical tip

The functional nature of this test (turning a steering wheel) makes it an easy one for the clinician to remember!

D INSTABILITY TESTS

Apprehension and relocation test

Aka

Subluxation/relocation test

Jobe relocation test

Fowler's sign

Apprehension test

Apprehension crank test

Purpose

To detect anterior instability of the glenohumeral joint.

Technique

This test has two distinguishable components: apprehension and relocation.

1 Apprehension

Patient position

Lying supine with the elbow flexed to 90°.

Clinician position

Standing by the couch on the affected side, one hand holds the lower forearm while the other supports above the elbow.

Action

The arm is abducted to 90° and the shoulder is then slowly externally rotated to 90° (Fig. 2.20A). This position may be enough to make the shoulder feel unstable and elicit a positive response from the patient, negating the need to proceed with the test further. If a positive response is not given, the hand supporting the elbow is then moved to the posterior aspect of the humeral head and an anteriorly directed force can then be applied to further challenge the stability of the shoulder (Fig. 2.20B).

Positive test

The test is considered positive for anterior glenohumeral instability if the patient registers *apprehension* during the manoeuvre or resists attempts to move the shoulder further. The patient may also recognize the sensation as being similar to the original injury or episodes subsequently.

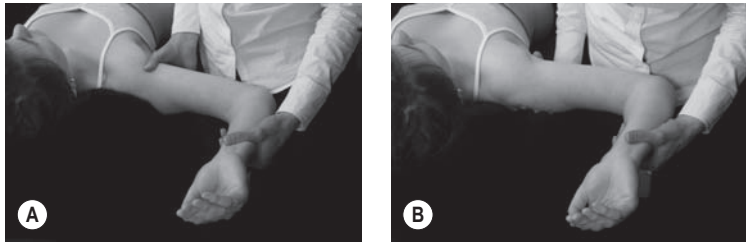


Fig. 2.20 • If a positive test is not elicited by the combined action of abduction and external rotation (A), an anteriorly directed force can be applied to the humeral head (B).

2 Relocation

Action

The patient's shoulder position of 90° abduction and external rotation is maintained and the clinician re-positions the heel of their hand over the anterior aspect of the humeral head and applies a firm posteriorly directed force (Fig. 2.21).

Positive test

With the relocation, the feeling of apprehension lessens and the degree of external rotation available usually increases before further apprehension is provoked.

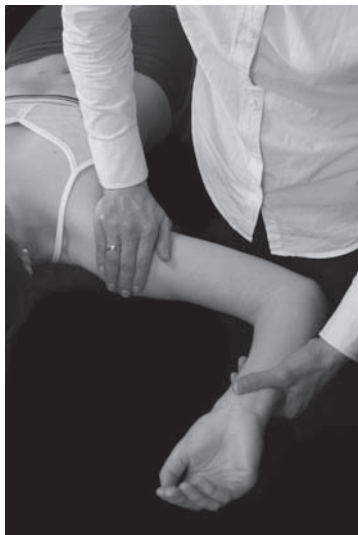

Fig. 2.21 • Posteriorly directed (relocation) force over the anterior aspect of the humeral head.

Clinical context

The apprehension component of the test, which is often considered as a separate test in itself, mimics the position most likely to cause acute shoulder dislocation (i.e. abduction, extension and external rotation), although more prolonged or habitual exposure to the same position in swimmers and plasterers, for example, can cause more subtle glenohumeral instability.

As the name implies, apprehension is the key finding for this test and a number of studies have shown that the diagnostic accuracy for shoulder instability improves if apprehension, rather than pain, is considered to be positive (Farber et al 2006, Hegedus et al 2008, Liume et al 2004, Lo et al 2004, Speer et al 1994). Interestingly, inter-rater reliability is also greater when apprehension, not pain, is assessed by clinicians (Tzannes et al 2004). The anteriorly directed force on the humerus during the subluxation part of the test has also been reported to increase the specificity and sensitivity of the test (Jobe & Bradley 1989, Speer et al 1994).

The test position also stresses numerous other structures and a primary report of pain, rather than apprehension, should cast suspicion on other possible lesions. Patients with rotator cuff pathology are more likely to report increased *pain* in the apprehension position than patients with an instability problem and this would be expected to diminish when taken into the relocation position (Speer et al 1994). Further, the test has also been reported to be 44% sensitive and 87% specific in diagnosing labral tears (Guanche & Jones 2003).

Clinical tip

Because pain may be the primary finding due to rotator cuff or labral involvement, it is essential that the clinician questions the patient carefully to establish whether it is pain or apprehension that is reproduced during the test, apprehension being a significant pointer to instability.

It may be necessary to repeat the test in varying degrees of external rotation and abduction, particularly if the patient is excessively mobile or habitually uses their shoulder in extreme positions of abnormal range.

Eliciting a positive response to all three components of this test – apprehension, relocation and the ‘surprise’ element (see Surprise test) – increases the probability of anterior instability being present (Hegedus et al 2008, Lo et al 2004).

TABLE 2.16 APPREHENSION & RELOCATION TEST

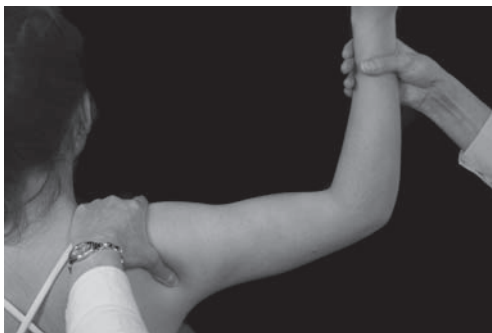Author and year	Finding	Apprehension test		Relocation test		Surprise test		Target condition
		LR+	LR-	LR+	LR-	LR+	LR-	
Speer et al 1994	Apprehension			57 ★★★	0.33 ★			Anterior glenohumeral instability
	Pain			0.71	1.2			
Farber et al 2006	Apprehension	20.2 ★★★	0.29 ★	10.4 ★★★	0.2 ★			Anterior glenohumeral instability
	Pain	1.14	0.8	3.02 ★	0.77			
Lo et al 2004	Pain + Apprehension	53 ★★★	0.99	1.0	0.99	58 ★★★	0.37 ★	Anterior glenohumeral instability
Liume et al 2004	Unspecified			6.5 ★★	0.18 ★★	8.3 ★★	0.09 ★★★	Anterior glenohumeral instability
Gross & Distefano 1997	Pain					8.3 ★★	0.09 ★★★	Anterior glenohumeral instability

EXPERT OPINION	COMMENTS
★★★	Apprehension & Relocation test Helpful when used in combination with the sulcus and Rowe tests to assess for shoulder instability. In addition, glenohumeral abduction in excess of 120° with the scapula fixed can also indicate instability.

Variations

The *apprehension/crank/fulcrum test* can be performed for convenience in sitting or standing (Fig. 2.22). The examiner stands adjacent to the affected side and slightly behind the patient. The arm is taken into 90° of abduction and full external rotation with one hand while the thumb of the other hand applies the anterior pressure on the back of the humeral head. The fingers are positioned anteriorly to assess the extent of anterior translation and to provide some restraint in the event of a sudden shift forwards.

Fig. 2.22 • Apprehension/crank/fulcrum test.



The *surprise test* can be included as part of the apprehension and relocation manoeuvre. The patient's arm is taken into the test start position and a posteriorly directed pressure on the front of the shoulder is applied with the heel of the hand. With the arm abducted and fully externally rotated, the stabilizing hand is then suddenly released, eliciting significant apprehension, pain and rapid anterior translation of the humeral head. It has been described as the single most accurate test for anterior instability (Lo et al 2004), although caution and clinical judgement regarding the suitability of

using this element of the test must be employed as the manoeuvre could well result in dislocation if the shoulder is very unstable.

The *Rowe test* (Fig. 2.23) for anterior instability has the patient lying supine with the hand behind the head. The clinician places a clenched fist under the posterior aspect of the shoulder, causing an anteriorly directed pressure through the head of the humerus, while the other hand applies pressure to the anterior aspect of the elbow, causing further shoulder external rotation and abduction. Pain and/or apprehension is indicative of anterior glenohumeral instability.

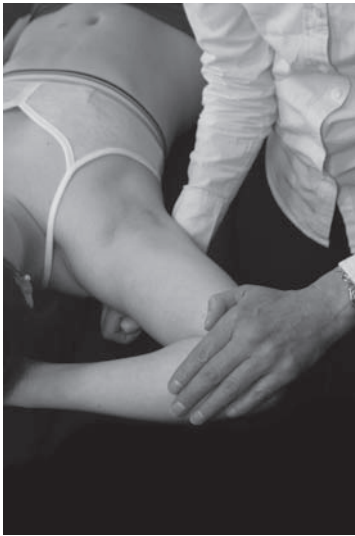

Fig. 2.23 • Rowe test.

Load and shift test

Purpose

To detect anterior and posterior instability of the glenohumeral joint.

Technique

Patient position

Sitting with the hand resting on the thigh. The patient's position is crucial (see clinical tip).

Clinician position

The examiner stands just behind the patient on the affected side. One hand stabilizes the shoulder by fixing the spine of the scapula with the thumb and the clavicle with the fingers. The other hand is placed over the humeral head, the thumb posterior and fingers wrapped around the anterior aspect of the head.

Action

The hand around the upper humerus then pushes the humeral head into the glenoid, thereby generating the 'load'. The humeral head is then moved anteriorly and posteriorly ('shift') to assess the extent of translation (Fig. 2.24A and B).

Positive test

Apprehension or reproduction of the patient's familiar sensation of instability is the most common positive finding, although an increase in anterior or posterior excursion of the humeral head compared to the unaffected side in a symptomatic patient, could also confirm a degree of instability.

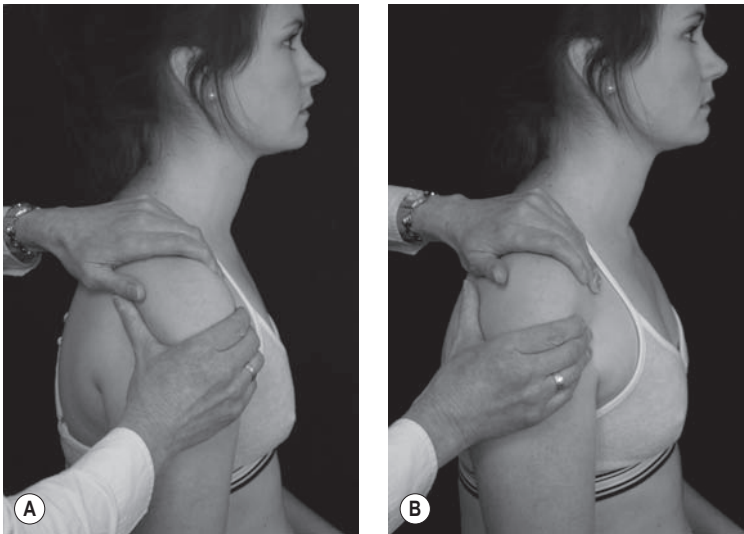


Fig. 2.24 • Compression of the humeral head against the glenoid, combined with anterior (A) and posterior humeral glide (B).

Clinical context

The range of anterior/posterior humeral translation varies significantly in the adult population and asymmetry has been noted in the shoulders of normal volunteers, leading to a lack of consensus on what should be considered 'normal' (Ellenbecker 2004). In the presence of anterior instability, however, there is a significant increase in anterior translation, and where there is multidirectional instability, both anterior and posterior translation will be greater than the unaffected side (Hawkins et al 1996).

TABLE 2.17 LOAD AND SHIFT TEST

Author and year	Finding	LR+	LR–	Target condition
Farber et al 2006	Apprehension	3.6 ★	0.55	Traumatic anterior shoulder instability
	Pain	0.97	1.01	Traumatic anterior shoulder instability
	Laxity	2.28 ★	0.54	Traumatic anterior shoulder instability
Tzannes & Murrell 2002	Not specified	50 ★★★	0.51	Anterior shoulder instability
Tzannes & Murrell 2002	Not specified	14 ★★★	0.87	Posterior shoulder instability

Using a modified version of the test with the shoulder in 60–80° abduction, eliciting apprehension was found to be a more accurate predictor of anterior instability than either pain or laxity (Farber et al 2006), although in a review of special tests at the shoulder, the load and shift test was considered to be less accurate than the apprehension and relocation test when testing for instability (Luime et al 2004).

Clinical tip

The patient needs to be sitting in a relaxed, upright, 'posture neutral' position where possible, so that the starting position of the humeral

head in relation to the glenoid can be gauged. A protracted shoulder girdle results in anterior translation of the humeral head and if this position is considered to be the 'neutral', a much greater degree of posterior translation is likely to be found during the 'shift' manoeuvre, giving a misleading false negative finding. There is a useful analogy at the knee (see anterior drawer test, p. 191), where an increase in anterior drawer may not be due to an anterior cruciate ligament injury but caused by posterior displacement of the tibia resulting from posterior cruciate ligament rupture, which leads to an abnormal starting position and the appearance of excessive anterior translation.

The test does rely on the subjective assessment of movement by the examiner although there is evidence from a small study that inter-examiner reliability ranges from good to excellent for most variations of the load and shift test in patients with shoulder instability (Tzannes et al 2004).

The following grading system can be used to try to establish the severity of anterior instability (Magee 2008).

Grade	Characteristics
Normal	The humeral head translates anteriorly between 0–25% of its diameter
Grade I	The head translates up to 50% of its diameter and can be felt to 'butt up' against the glenoid rim before spontaneously reducing
Grade II	The head translates anteriorly more than 50% and can be felt to move over the glenoid rim but is still able to reduce spontaneously
Grade III	The head translates over the rim and cannot reduce spontaneously

Variations

The *load and shift test* can be adapted to more specifically isolate and test different parts of the glenohumeral capsule. Starting with the patient in a supine position, the integrity of the *inferior capsule* is assessed (Fig. 2.25A). For the anterior shift, the arm is elevated in the scapular plane to 60° with 0° of external rotation. The heel of one hand is placed over the deltoid muscle with the thumb positioned anteriorly over the humeral head and the fingers wrapped around the back. The other hand supports the lower forearm and applies an

axial load while an anteriorly directed force is provided by the fingers posteriorly. The amount of anterior translation is then assessed with palpation. By incrementally adding external rotation during the 'shift' manoeuvre, if the *anterior* part of the inferior capsule is intact, anterior translation will reduce (Fig. 2.25B). With an anteriorly displaced humerus, the amount of external rotation needed to reduce the head back into position can be a useful measure of the degree of capsular laxity. Similarly, performing the posterior shift in lying can also assess the integrity of the *posterior* element of the inferior capsule. The arm is elevated in the scapular plane to 60° with 45° of external rotation. This time the thumb provides the backward force applied to the humeral head as axial loading is applied and increasing movement towards internal rotation should reduce the extent of posterior translation provided the postero-inferior capsule is intact.

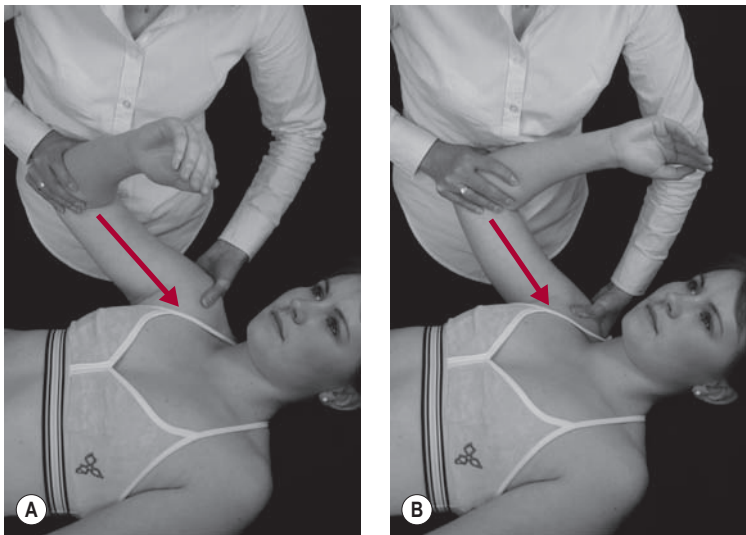


Fig. 2.25 • Load and shift variation selectively stressing the inferior (A) and anterior (B) capsules. Arrows show the direction of axial compression.

The *anterior and posterior drawer tests* can also be used to assess the amount of humeral head translation. The patient lies supine with the arm initially in neutral. The clinician stands adjacent to the patient and gently places one hand in the patient's axilla

wrapping the fingers around the humerus while the other hand is placed over the lateral aspect of the upper arm. The patient's forearm is supported between the clinician's elbow and waist. An anterior glide of the humerus on the glenoid is performed by pulling the humerus anteromedially and a posterior glide by pushing posterolaterally (Figs 2.26 and 2.27). Increased range of movement, pain and/or apprehension may indicate laxity of the capsule (Ellenbecker 2004) or a labral tear. The extent of anterior translation can also be assessed in increasing positions of abduction indicating:

- 0°–30° laxity of the superior glenohumeral ligament
- 45°–60° laxity of the middle glenohumeral ligament
- 90° laxity of the inferior glenohumeral ligament.

Fig. 2.26 • Anterior drawer test. Showing an anteromedially directed glide of the humerus.

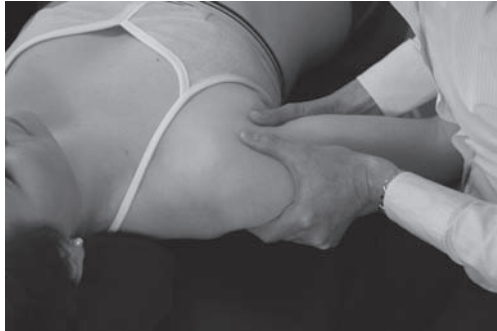
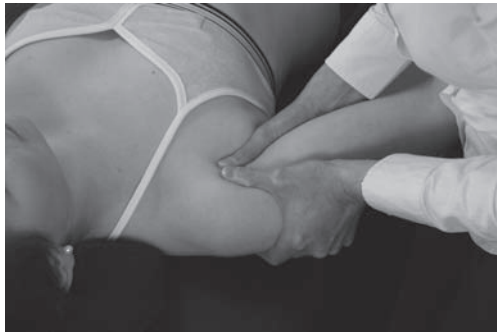
Fig. 2.27 • Posterior drawer test. Showing a posterolaterally directed glide of the humerus.



Norwood stress test

Purpose

To test the integrity of the posterior capsule in order to detect posterior instability at the shoulder.

Technique

Patient position

Lying supine with the shoulder positioned in 90° of abduction and some external rotation so that the upper arm lies horizontally and the forearm is vertical. The elbow is flexed to 90° (Fig 2.28A).

Clinician position

The clinician stands on the affected side and places one hand over the shoulder with the thumb positioned anteriorly and the fingers around the back of the humeral head. The other hand grasps the forearm just proximal to the wrist in order to control movement of the arm.

Action

Using the fingers around the back of the humeral head to detect any posterior translation, the arm is then passively adducted until the upper arm is vertical (Fig. 2.28B).

Positive test

Recognition by the patient of their familiar sensation of instability, apprehension or pain would all indicate a positive finding but posterior subluxation *may* occur before the patient responds in any way. This excess translation is sometimes accompanied by a click as the humeral head rides over the glenoid labral rim.

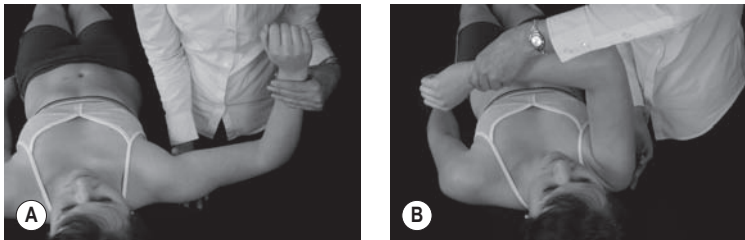


Fig. 2.28 • Start (A) and end (B) positions of the Norwood stress test.

Clinical context

Posterior instability is the least common form of shoulder instability, representing only 2% of cases (Cicak 2004, Robinson & Aderinto 2005). Traumatic posterior shoulder *dislocation* may be a precursor to recurrent posterior instability but this predisposition is less common than the anterior instability seen as a result of an anterior dislocation (Robinson & Aderinto 2005). Most patients who experience recurrent episodes of frank dislocation have previously experienced an initial traumatic dislocation (e.g. patients with epilepsy whose shoulders dislocate during seizures). Chronic posterior dislocation of the shoulder is commonly missed (Cicak 2004).

Recurrent posterior *subluxation* is a distinct and separate entity. The patient may recall a discrete traumatic injury (e.g. a fall on the outstretched arm or a direct blow to the anterior aspect of the shoulder) or a more insidious onset of symptoms resulting from microtrauma caused by repetitive shoulder flexion, adduction and internal rotation movements. Young, physically active men in their twenties are most commonly affected, particularly those involved in overhead or contact sports. Symptoms of poorly localized posterior shoulder pain and a sensation of instability are most often reproduced with the shoulder in flexion, adduction and internal rotation. In some patients this position will cause subluxation, which is followed by visible and audible relocation (a 'clunk' is usually evident) once the shoulder is moved back into abduction (Robinson & Aderinto 2005). Many patients are able to reproduce this subluxation at their own volition and in a small subgroup of habitual or wilful dislocators (who often present bilaterally) this *may* manifest as part of a wider psychological problem (Robinson & Aderinto 2005).

In the normal shoulder, the test position of flexion and adduction causes tightening of the posterior capsule and this restricts posterior humeral translation. If excessive movement is detected, significant capsular and/or labral injury should be suspected (Ellenbecker 2004).

Clinical tip

This test can be enhanced by either applying a posteriorly directed force with the thumb of the stabilizing hand in the test position (Magee 2008) or by adding a small degree of internal rotation. Because of the tendency for this test to cause posterior subluxation without any prior warning, care should be taken when performing the test and the sensitizing elements only added if necessary.

Additional tests should be used to support the diagnosis of instability such as the load and shift test (see p. 60) and the posterior drawer test (see p. 65) (Robinson & Aderinto 2005).

Variations

The *jerk test/posterior glide test/90° flexion test* is very similar and performed with the patient in a sitting position. With the elbow flexed to 90° and the arm internally rotated across the waist, the shoulder is taken into 90° of forward flexion. With one hand around the elbow and the other providing some stabilization around the shoulder girdle, a load along the longitudinal axis of the humerus back towards the shoulder is applied as the arm is horizontally adducted (Fig. 2.29). Instability leads to a pronounced and sudden shift or jerk as the humeral head slips off the glenoid followed by a similar sensation as the joint reduces. The glenoid labrum provides some restraint to the posterior shift but, unable to prevent the movement in the unstable shoulder, will usually cause a click as the humeral head rides over the rim.

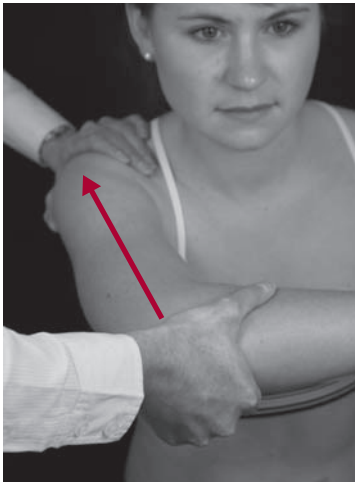

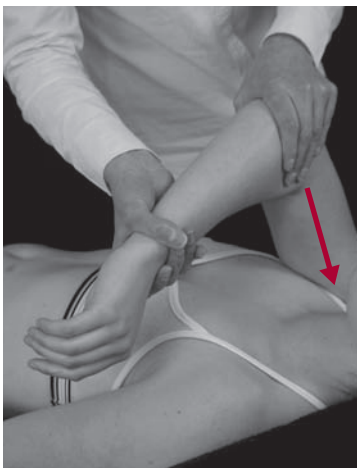Fig. 2.29 • Jerk test. Arrow shows the direction of axial compression.

EXPERT OPINION	COMMENTS
★★	<p>Jerk test</p> <p>Useful in combination with the other instability tests.</p>

Related tests

The *posterior apprehension stress test* is also used to detect posterior instability. With the patient lying supine and the elbow flexed, the clinician passively elevates the arm through the scapular plane to about 90°. One hand holds the elbow joint while the other supports the forearm just above the wrist. Axial compression is then added and maintained while the arm is simultaneously adducted and internally rotated (Fig. 2.30). Pain is the most common positive response although apprehension may initially be noted, particularly if the stress is applied gradually. The movement may be accompanied by a click as the humeral head over-rides the labral rim of the glenoid. Ultimately, if the patient permits, an increase in posterior translation will be evident with a shift of over 50% of the humeral head diameter considered to represent instability.

Fig. 2.30 • Posterior apprehension stress test. Arrow shows the direction of axial compression.



The *push-pull test* has the patient lying supine towards the edge of the couch. The arm is taken into 90° of abduction and externally rotated so that the forearm is vertically orientated. One hand is placed over the upper humerus which produces a firm downward (or posterior) pressure ('push') while the other grasps the forearm just proximal to the wrist and 'pulls' in an upward direction (Fig. 2.31). The resultant effect is a posterior translation which would not normally

exceed 50% of the humeral head's diameter. Excursion greater than this is suggestive of posterior instability.

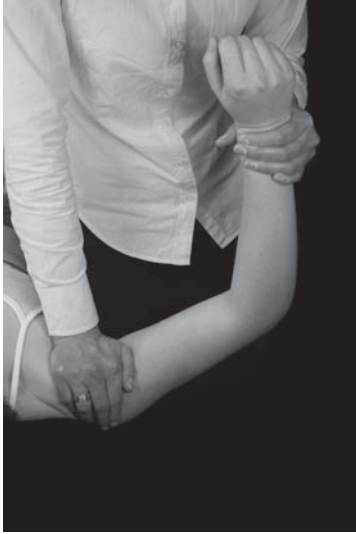

Fig. 2.31 • Push-pull test.

Sulcus sign

Aka

Inferior humeral head translation test

Purpose

To detect the presence of inferior instability and the possibility of multidirectional instability (MDI) of the glenohumeral joint.

Technique

Patient position

Sitting on a couch, elevated so that the examiner has a clear view of the lateral aspect of the shoulder with the arm dependent over the side of the couch.

Clinician position

Standing on the affected side, the middle finger and thumb of one hand are placed on the anterior and posterior angles of the acromion,

leaving the index finger free to palpate the gap between the middle of the acromion and the humeral head. The other hand comfortably grasps the arm just above the elbow in readiness to apply distraction.

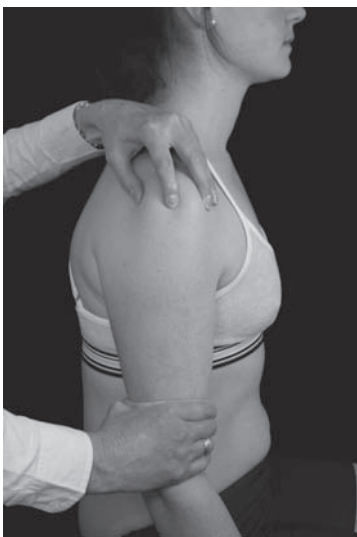Action

The patient is instructed to relax the shoulder. A firm downward distraction is exerted gradually.

Positive test

A sulcus (a deep groove) develops between the lateral edge of the acromion and upper humerus with tautening of the overlying skin suggesting physiological glenohumeral laxity which can be assessed further with directional instability tests.

Fig. 2.32 • Sulcus test.



Clinical context

The significance of inferior instability is that it invariably partners anterior and/or posterior instability to create MDI.

Over the years attempts have been made to classify shoulder instabilities to aid the condition's diagnosis and management. One recent method avoids classification in terms of direction of instability, preferring instead to examine the underlying cause of the problem (Lewis et al 2004).

Type I	Traumatic instability – usually unilateral with an underlying Bankart's defect but normal muscle control
Type II	Atraumatic instability – commonly bilateral with capsular dysfunction, structural damage to the articular surfaces but normal muscle control
Type III	Habitual or non-structural instability – often bilateral, with abnormal muscle control but no capsular dysfunction or structural damage to the articular surfaces

Bilateral laxity is not always clinically relevant as significant levels of asymptomatic shoulder laxity have been found in the general population (Bigliani et al 1997, Emery & Mullaji 1991, Lintner et al 1996, McFarland et al 1996). Once benign laxity has been discovered, some patients are able to create the sulcus themselves with a downward distraction of the upper arm (a worthy 'party piece' for some). Laxity *not* accompanied by symptoms can therefore be considered 'normal' but if accompanied by pain, apprehension and a loss of functional movement, the shoulder clearly deserves further evaluation.

While doubt exists over its usefulness in evaluating shoulder instabilities (Luime et al 2004), the test can be made more objective by the use of an approximate grading system where the distance between the inferior margin of the acromion and the upper part of the humeral head is measured as follows (Mallon & Speer 1995):

Grade	Distance between inferior margin of acromion and humeral head
1	Less than 1 cm
2	1.0–1.5 cm
3	More than 1.5 cm

MDI can cause considerable pain and loss of function, resulting in an inability to use the arm usefully in positions of elevation *or* to carry loads with the shoulder. Associated neurological symptoms may also be reported as the nerve trunks become temporarily compressed during the abnormal shoulder movement patterns

but any paraesthesiae (and in some cases weakness) are usually short-lived.

In a review article, Tzannes & Murrell (2002) reported that the presence of a sulcus of 2 cm or more was highly predictive of MDI (specificity 97%). However, the associated sensitivity was low, meaning that a significant majority of patients with clinical instability would be missed if they did not exhibit this degree of sulcus. Sensitivity increased if a 1 cm sulcus was taken to indicate MDI but, unsurprisingly, specificity decreased.

TABLE 2.18 SULCUS SIGN

Author and year	LR+	LR–	Target condition
Tzannes & Murrell 2002	9 ★★	0.74	MDI if sulcus >2 cm
Tzannes & Murrell 2002	4.8 ★	0.3 ★	MDI if sulcus >1 cm

MDI = multidirectional instability

Clinical tip

It is necessary to try to eliminate rotation of the humerus while performing this test as internal rotation tightens the posterior capsule and external rotation the anterior capsule – either of these positions will reduce the degree of sulcus attained. However, performing the test in about 20° of abduction and slight internal rotation allows maximum inferior movement of the humerus (Helmig et al 1990).

A positive sulcus test usefully directs the clinician to a likely diagnosis of MDI without triggering pain or significant apprehension and this induces trust from the patient and a willingness to permit further directional instability testing (apprehension/relocation, p. 55; load and shift, p. 60; Norwood stress, p. 65, tests).

EXPERT OPINION	COMMENTS
★★	<p>Sulcus sign</p> <p>As a default assumption, patients under the age of 40 years presenting with impingement signs are assumed to have some kind of underlying instability until proven otherwise.</p>

Related tests

A variation of the *sulcus sign*, *Feagin's test* assesses the integrity of the inferior glenohumeral ligaments (Ellenbecker 2004). With the patient sitting on an elevated couch or in standing, the arm rests on the clinician's shoulder ensuring the arm is abducted to around 80°. The clinician interlocks both hands and positions them over the proximal humerus and applies a downward and slightly forwards force on the upper humerus (Fig. 2.33). Again, apprehension is a tell-tale sign when performing this test.



Fig. 2.33 • Feagin's test.

The *Rowe test* for multidirectional instability aims to assess all planes of movement for the usual signs of apprehension, pain, evidence of the sulcus, excess movement and a possible clunk. In standing, the patient places the unaffected hand on an adjacent treatment couch or table for support as they flex forwards to about 45°. The clinician stands adjacent to the affected shoulder and, with one hand, fixes the humeral head so that the fingers are positioned anteriorly

and the thumb is placed on the posterior aspect. The other hand holds the lower forearm. To test for:

<i>inferior instability</i>	the arm is allowed to 'dangle' vertically and a downward force applied
<i>anterior instability</i>	the arm is held in 20° of extension (from the starting position) and distraction added (in the line of the humerus) as the thumb of the other hand pushes the back of the humeral head anteriorly, encouraging a forward shift of the head in relation to the glenoid
<i>posterior instability</i>	the arm is positioned in about 20° of flexion (from the starting position) and distraction added (along the line of the humerus) as the fingers of the other hand pull back on the anterior surface of the humeral head to engineer a posterior shift of the head against the glenoid.

E ACROMIOCLAVICULAR JOINT (ACJ) TESTS

Active compression test

Aka

O'Brien's test

Purpose

To identify a symptomatic acromioclavicular joint (ACJ) and/or a superior labral anterior posterior (SLAP) lesion.

Technique

Patient position

Standing.

Clinician position

Standing adjacent to the affected arm and stabilizing the scapula with one hand.

Action

The patient adopts the starting position for this test by actively elevating the arm through flexion to 90° and adducting 10–15°,

keeping the elbow fully extended throughout. In this position, the patient internally rotates the shoulder and fully pronates the forearm, so that the thumb points downwards. The examiner places one hand over the superior aspect of the patient's distal forearm and exerts a uniform downward pressure, instructing the patient to resist this (Fig. 2.34). The test is then repeated with the patient's palm facing upwards (Fig. 2.35).

Positive test

SLAP lesion: pain felt deep inside the shoulder, with or without a click, on testing with the thumb pointing down, relieved when repeated with the palm facing upwards.

ACJ disorder: pain felt on top of the shoulder, with or without a click, on testing with the thumb pointing down, relieved when repeated with the palm facing upwards.



Fig. 2.34 • Active compression test in internal rotation.



Fig. 2.35 • Active compression test in external rotation.

Clinical context

A patient with ACJ pain invented this test after noticing the position was provocative. O'Brien et al (1998) reportedly evaluated it on a number of other patients before noticing its efficacy in diagnosing labral lesions. In cadaveric studies, high pressure in the ACJ was reported in the pronated position (thumb down) which did not occur when the test was repeated in the supinated position (palm upwards). The mechanism proposed for this was speculative and less than clear. Arthroscopically, again in cadavers, O'Brien et al (1998) observed that the test position displaced the long head of biceps medially, causing it to pull on the upper glenoid labrum.

Subsequent, more detailed, cadaveric work (Parentis et al 2004) has shown that in the starting position for the test, the lesser tuberosity consistently contacts the superior labrum providing some

TABLE 2.19 ACTIVE COMPRESSION TEST

Author and year	LR+	LR-	Target condition
Chronopoulos et al 2004	8.20 ★★	0.62	ACJ pathology
O'Brien et al 1998	29.41 ★★★	0.00 ★★★	ACJ pathology
Walton et al 2004	1.60	0.93	ACJ pathology
Guanche & Jones 2003	1.02	0.98	Any SLAP lesion
McFarland et al 2002	1.04	0.96	Any SLAP lesions
O'Brien et al 1998	66.67 ★★★	0.00 ★★★	Labral injury
Parentis et al 2006	1.25	0.75	Any SLAP lesion
Stetson & Templin 2002	0.78	1.48	Labral injury

SLAP = superior labral anterior posterior

ACJ = acromioclavicular joint

basis for SLAP lesion provocation. The resistive component of the test could increase stress on the superior labrum via the long head of biceps. Because the lesser tuberosity has been shown not to contact the superior labrum in the second part of the test, a reduction in symptoms would be expected if labral in origin.

As is often the case, the sensitivity and specificity reported by the test's originators have not been reproduced by other researchers. Hegedus et al (2008) suggest that joint line tenderness is a sensitive initial screening test when considering the possibility of ACJ pathology, with the active compression test providing useful confirmation because of its high specificity. The addition of a positive scarf test (see p. 78) provides further confirmation of ACJ pathology (Powell & Huijbregts 2006).

Clinical tip

On a technical note, the test's originators emphasized that the patient should resist the clinician's downward force, not vice versa; and that for the test to be considered positive, there must be reduction or elimination of pain in the test's second phase.

The starting position for the test has also been shown to force the supraspinatus tendon into contact with the lateral acromion (Parentis et al 2004) and this mechanism is also likely to trigger primary impingement symptoms. Given that a positive test can indicate rotator cuff pathology, a labral or ACJ lesion, the findings need to be verified in the light of the patient's history and overall clinical presentation.

If a labral injury is suspected further evaluation is necessary (see crank and associated labral tests, p. 46).

Scarf test

Aka

- Crossover impingement test
- Horizontal adduction impingement test
- Cross arm adduction test
- Cross arm adduction impingement test

Purpose

To test primarily for acromioclavicular joint (ACJ) lesions.

Technique

Patient position

Sitting or standing.

Clinician position

Standing adjacent to the patient, one hand is placed on the upper scapula of the unaffected side to provide counter-pressure during the test. The other hand supports the flexed elbow of the affected arm and passively takes the shoulder into 90° of forward flexion, ensuring the shoulder is held in internal rotation and the palm of the hand faces the floor.

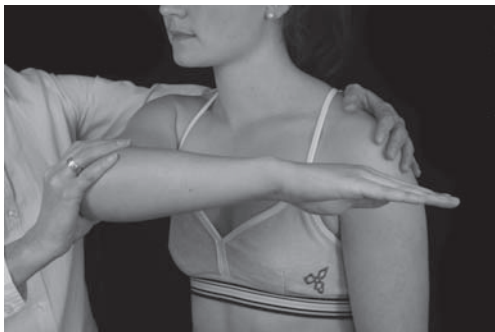Action

From the starting position, the shoulder is horizontally adducted passively across the patient's body to the end of available range.

Positive test

Localized pain over the joint line or the C4 (epaulette area) dermatome is a positive finding and indicates ACJ injury or pathology.

Fig. 2.36 • Scarf test.



Clinical context

The scarf test is used primarily as a test for the ACJ although other anterior structures, notably the lower fibres of the subscapularis tendon and its bursa, the subacromial bursa and the sternoclavicular joint, are also vulnerable to compression in the test position (Atkins et al 2010). Any tightness of the posterior capsule of the glenohumeral joint will be distinguishable by poorly localized discomfort over the posterior aspect of the shoulder, rather than the more specific localized pain arising from an ACJ lesion.

In a small study of patients with chronic ACJ pathology the accuracy of the scarf test was found to have a greater sensitivity when compared with the active compression test (see p. 75), but the latter was the more specific. Using the tests in combination leads to increased diagnostic accuracy (Chronopoulos et al 2004).

TABLE 2.20 SCARF TEST

Author and year	LR+	LR–	Target condition
Chronopoulos et al 2004	3.67 ★	0.29 ★	ACJ pathology

ACJ = acromioclavicular joint

Clinical tip

The addition of palpation for joint line tenderness is a further useful physical test for diagnosing lesions of the joint. A cohort of patients with pain over the upper arm and superior aspect of the shoulder underwent a selection of ACJ tests prior to diagnostic joint injection. ACJ tenderness was the most sensitive measure but it lacked specificity (Walton et al 2004).

EXPERT OPINION	COMMENTS
★★	<p>Scarf test</p> <p>Useful as a non-specific test. The position adopted may also induce pain and/or apprehension in the presence of posterior instability.</p>

Shear test

Aka

Acromioclavicular passive mobility test

Purpose

To test for acromioclavicular joint (ACJ) pathology or injury.

Technique

Patient position

Sitting or standing with the arm dependent or in a neutral position on the lap.

Clinician position

Standing adjacent to the patient. The heel of one hand is placed posteriorly over the spine of the scapula with the fingers pointing upwards; the other hand is positioned in a similar fashion anteriorly over the mid section of the clavicle. The fingers of both hands are then interlocked over the upper trapezius area of the shoulder.

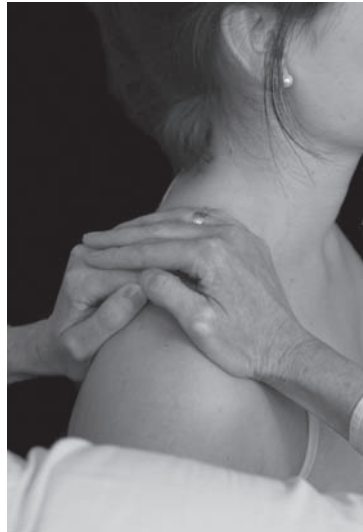Action

The hands are gradually squeezed together, imparting a shear stress through the ACJ created by the approximation of the clavicle and scapula.

Positive test

Localized pain over the ACJ or increased joint excursion are considered to be positive findings and are indicative of ACJ pathology or injury.

Fig. 2.37 • AC shear test.

***Clinical context***

Pain from the ACJ is characteristically well localized to the region of the joint but can spread across the C4 dermatome – over the epaulette area of the shoulder. A fall on the hand or a direct blow of the

kind commonly sustained in contact sports can cause ACJ injury which can be classified as follows:

Type I	ACJ ligaments are partially torn but remain intact
Type II	Minor subluxation due to more significant tearing of the ACJ ligaments but the coracoclavicular ligament remains intact
Type III	Complete dislocation of the ACJ

The degenerative process commonly afflicts the ACJ, with changes noted in the fibrocartilaginous disc as early as the second decade of life. X-rays are accurate in diagnosing ACJ osteoarthritis (OA) but should always be interpreted in the light of the patient's clinical history and findings, as false positives have been reported in asymptomatic patients with radiologically confirmed OA (Walton et al 2004).

Clinical tip

No single test has been found to accurately diagnose ACJ pathology but a combination of tests (see active compression, p.76 and scarf tests, p. 79) increases the diagnostic certainty (Hegedus et al 2008).

EXPERT OPINION	COMMENTS
★★	Shear test Useful as a screening test

Variations

The *Paxinos test* (Fig. 2.38A and B) is a further shear type test for the ACJ. The clinician's hand rests over the top of the shoulder with the thumb under the posterolateral aspect of the acromion and the index and middle fingers resting on top of the lateral third of the clavicle. The thumb applies an anterior and superior pressure to the acromion, and the fingers push the clavicle inferiorly. A positive test for ACJ pathology or injury is indicated by an increase in ACJ pain. This test was evaluated by its originator and only shown to have moderate to low sensitivity and specificity which, given the propensity for these figures to be high in such circumstances, suggests that other tests should be used in preference (Walton et al 2004).

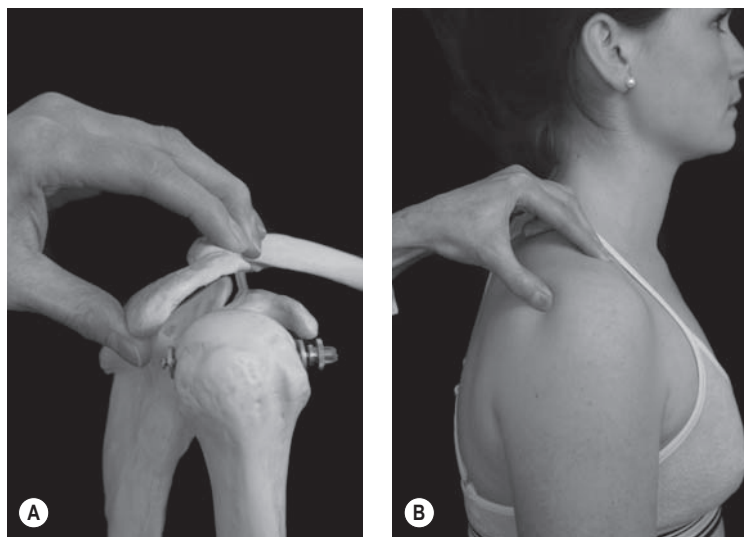


Fig. 2.38 • (A,B) Paxinos test showing the position of the thumb on the posterior angle of the acromion and fingers over the outer clavicle.

TABLE 2.21 PAXINOS TEST

Author and year	LR+	LR–	Target condition
Walton et al 2004	1.58	0.42 ★	ACJ pathology

ACJ = acromioclavicular joint

References

- Andrews, J.R., Carson, W.G., McLeod, W.D., 1985. Glenoid labrum tears related to the long head of the biceps. *Am. J. Sports Med.* 13, 337–341.
- Atkins, E., Kerr, E., Goodlad, J., 2010. *A Practical Approach to Orthopaedic Medicine*, third ed. Churchill Livingstone, Edinburgh.
- Bennett, W.F., 1998. Specificity of the Speed's test: arthroscopic technique for evaluating the biceps tendon at the level of the bicipital groove. *Arthroscopy* 14 (8), 789–796.
- Berg, E.E., Ciullo, J.V., 1998. A clinical test for superior glenoid labral or 'SLAP' lesions. *Clin. J. Sports Med.* 8 (2), 121–123.

- Bigliani, L.U., Codd, T.P., Connor, P.M., et al., 1997. Shoulder motion and laxity in the professional baseball player. *Am. J. Sports Med.* 25 (5), 609–613.
- Burkhart, S.S., Morgan, C.D., 1998. The peel-back mechanism: its role in producing and extending posterior type II SLAP lesions and its effect on SLAP repair rehabilitation. *Arthroscopy* 14 (6), 637–640.
- Burkhart, S.S., Tehrany, A., 2002. Arthroscopic subscapularis tendon repair: technique and preliminary results.. *Arthroscopy* 18 (5), 454–463.
- Chronopoulos, E., Kim, T.K., Park, H.B., et al., 2004. Diagnostic value of physical tests for isolated chronic acromioclavicular lesions. *Am. J. Sports Med.* 32 (3), 655–661.
- Cicak, N., 2004. Posterior dislocation of the shoulder. *J. Bone Joint Surg. Br.* 86 (3), 324–332.
- Codman, E.A., 1934. Rupture of the supraspinatus tendon and other lesions in or about the subacromial bursa. Boston, privately printed [Reprinted, Kreiger, Malabar, Florida, 1965]
- Crenshaw, A.H., Kilgore, W.E., 1966. Surgical treatment of bicapital tenosynovitis. *J. Bone Joint Surg. Br.* 48 (8), 1496–1502.
- Ellenbecker, T.S., 2004. *Clinical Examination of the Shoulder*. Elsevier, St Louis.
- Emery, R.J., Mullaji, A.B., 1991. Glenohumeral joint instability in normal adolescents: incidence and significance. *J. Bone Joint Surg. Br.* 73 (3), 406–408.
- Farber, A.J., Castillo, R., Clough, M., et al., 2006. Clinical assessment of three common tests for traumatic anterior shoulder instability. *J. Bone Joint Surg. Br.* 88 (7), 1467–1474.
- Flatow, E.L., Soslowky, L.J., Ticker, J.B., et al., 1994. Excursion of the rotator cuff under the acromion: patterns of subacromial contact. *Am. J. Sports Med.* 22 (6), 779–788.
- Gerber, C., Krushell, R.J., 1991. Isolated rupture of the tendon of the subscapularis muscle: clinical features in 16 cases. *J. Bone Joint Surg. Br.* 73 (3), 389–394.
- Gerber, C., Hersche, O., Farron, A., 1996. Isolated rupture of the subscapularis tendon. *J. Bone Joint Surg. Br.* 78 (7), 1015–1023.
- Greis, P.E., Dean, M., Hawkins, R.J., 1996. Subscapularis tendon disruption after Bankart reconstruction for anterior instability. *J. Shoulder Elbow Surg.* 5 (3), 219–222.
- Gross, M.L., Distefano, M.C., 1997. Anterior release test: a new test for occult shoulder instability. *Clin. Orthop. Relat. Res.* 339, 105–108.
- Guanche, C.A., Jones, D.C., 2003. Clinical testing for tears of the glenoid labrum. *Arthroscopy* 19 (5), 517–523.
- Hamner, D.L., Pink, M.M., Jobe, F.W., 2000. A modification of the relocation test: arthroscopic findings associated with a positive test. *J. Shoulder Elbow Surg.* 9 (4), 263–267.
- Hawkins, R.J., Schutte, J.P., Janda, D.H., et al., 1996. Translation of the glenohumeral joint with the patient under anaesthesia. *J. Shoulder Elbow Surg.* 5 (4), 286–292.
- Hegedus, E.J., Goode, A., Campbell, S., et al., 2008. Physical examination tests of the shoulder: a systematic review with meta-analysis of individual tests. *Br. J. Sports Med.* 42 (2), 80–92.

- Helmig, P., Sojbjerg, J.O., Kjaersgaard-Andersen, P., et al., 1990. Distal humeral migration as a component of multidirectional shoulder instability: an anatomical study in autopsy specimens. *Clin. Orthop. Relat. Res.* 252, 139–143.
- Hertel, R., Ballmer, F.T., Lombert, S.M., et al., 1996. Lag signs in the diagnosis of rotator cuff rupture. *J. Shoulder Elbow Surg.* 5 (4), 307–313.
- Holtby, R., Razmjou, H., 2004. Validity of the supraspinatus test as a single clinical test in diagnosing patients with rotator cuff pathology. *J. Orthop. Sports Phys. Ther.* 34 (4), 194–200.
- Hurley, J.A., Anderson, T.E., 1990. Shoulder arthroscopy: its role in evaluating shoulder disorders in the athlete. *Am. J. Sports Med.* 18 (5), 480–483.
- Itoi, E., Kido, T., Sano, A., et al., 1999. Which is more useful, the 'full can test' or the 'empty can test', in detecting the torn supraspinatus tendon? *Am. J. Sports Med.* 27 (1), 65–68.
- Jobe, C.M., 1996. Superior glenoid impingement: current concepts. *Clin. Orthop. Relat. Res.* 330, 98–107.
- Jobe, C.M., 1997. Superior glenoid impingement. *Orthop. Clin. North Am.* 28 (2), 137–143.
- Jobe, F.W., Bradley, J.P., 1989. The diagnosis and non-operative treatment of shoulder injuries in athletes. *Clin. Sports Med.* 8 (3), 419–438.
- Jobe, F.W., Kvitne, R.S., Giangarra, C.E., 1989. Shoulder pain in the overhand or throwing athlete: the relationship of anterior instability and rotator cuff impingement. *Orthop. Rev.* 18 (9), 963–975.
- Kelly, B.T., Kadrmaz, W.R., Speer, K.P., 1996. The manual muscle examination for rotator cuff strength: an electromyographic investigation. *Am. J. Sports Med.* 24 (5), 581–588.
- Kibler, W.B., 1995. Specificity and sensitivity of the anterior slide test in throwing athletes with superior glenoid labral tears. *Arthroscopy* 11 (3), 296–300.
- Kim, T.K., McFarland, E.G., 2004. Internal impingement of the shoulder in flexion. *Clin. Orthop. Relat. Res.* 421, 112–119.
- Kim, S.H., Ha, K.I., Ahn, J.H., et al., 2001. Biceps load test II: a clinical test for slap lesions of the shoulder. *Arthroscopy* 17 (2), 160–164.
- Kim, T.K., Queale, W.S., Cosgarea, A.J., et al., 2003a. Clinical features of the different types of SLAP lesions: an analysis of one hundred and thirty-nine cases. Superior labrum anterior posterior. *J. Bone Joint Surg. Br.* 85 (1), 66–71.
- Kim, T.K., Rauh, P.B., McFarland, E.G., 2003b. Partial tears of the subscapularis tendon found during arthroscopic procedures on the shoulder: a statistical analysis of sixty cases. *Am. J. Sports Med.* 31 (5), 744–750.
- Leroux, J.L., Thomas, E., Bonnel, F., et al., 1995. Diagnostic value of clinical tests for shoulder impingement syndrome. *Rev. Rhum. English edn* 62 (6), 423–428.
- Lewis, A., Kitamura, T., Bayley, J., 2004. The classification of shoulder instability: new light through old windows! *Curr. Orthop.* 18 (2), 97–108.
- Lintner, S.A., Levy, A., Kenter, K.P., et al., 1996. Glenohumeral translation in the asymptomatic athlete's shoulder and its relationship to other clinically measurable anthropometric variables. *Am. J. Sports Med.* 24 (6), 716–720.

- Liu, S.H., Henry, M.H., Nuccion, S.L., 1996. A prospective evaluation of a new physical examination in predicting glenoid labral tears. *Am. J. Sports Med.* 24 (6), 721–725.
- Lo, I.K.Y., Nonweiler, B., Woolfrey, M., et al., 2004. An evaluation of the apprehension, relocation, and surprise tests for anterior shoulder instability. *Am. J. Sports Med.* 32 (2), 301–307.
- Luime, J.J., Verhagen, A.P., Miedema, H.S., et al., 2004. Does this patient have an instability of the shoulder or a labrum lesion? *J. Am. Med. Assoc.* 292 (16), 1989–1999.
- MacDonald, P.B., Clark, P., Sutherland, K., 2000. An analysis of the diagnostic accuracy of the Hawkins and Neer subacromial impingement signs. *J. Shoulder Elbow Surg.* 9 (4), 299–301.
- McFarland, E.G., Campbell, G., McDowell, J., 1996. Posterior shoulder laxity in asymptomatic athletes. *Am. J. Sports Med.* 24 (4), 468–471.
- McFarland, E.G., Kim, T.K., Savino, R.M., 2002. Clinical assessment of three common tests for superior labral anterior-posterior lesions. *Am. J. Sports Med.* 30 (6), 810–815.
- Magee, D.J., 2008. *Orthopaedic Physical Assessment*, fifth ed. Saunders, Philadelphia.
- Mallon, W.J., Speer, K.P., 1995. Multidirectional instability: current concepts. *J. Shoulder Elbow Surg.* 4 (1), 54–64.
- Naredo, E., Aguado, P., De Miguel, E., et al., 2002. Painful shoulder: comparison of physical examination and ultrasonographic findings. *Ann. Rheum. Dis.* 61 (2), 132–136.
- Neer, C.S., 1972. Anterior acromioplasty for the chronic impingement syndrome in the shoulder: a preliminary report. *J. Bone Joint Surg. Br.* 54 (1), 41–50.
- Neer, C.S., 1983. Impingement lesions. *Clin. Orthop. Relat. Res.* 173, 70–77.
- Neer, C.S., Welsh, R.P., 1977. The shoulder in sports. *Orthop. Clin. North Am.* 8 (3), 583–591.
- Neviaser, T.J., 1993. The GLAD lesion another cause of anterior shoulder pain. *Arthroscopy* 9 (1), 22–23.
- O'Brien, S.J., Pagnani, M.J., Fealy, S., et al., 1998. The active compression test: a new and effective test for diagnosing labral tears and acromioclavicular joint abnormality. *Am. J. Sports Med.* 26 (5), 610–613.
- Oh, J.H., Kim, J.Y., Kim, W.S., et al., 2008. The evaluation of various physical examinations for the diagnosis of type II superior labrum anterior and posterior lesion. *Am. J. Sports Med.* 36 (2), 353–359.
- Pappas, A.M., Goss, T.P., Kleinman, P.K., 1983. Symptomatic shoulder instability due to lesions of the glenoid labrum. *Am. J. Sports Med.* 11 (5), 279–288.
- Parentis, M.A., Mohr, K.S., ElAttrache, N.S., 2002. Disorders of the superior labrum: review and treatment guidelines. *Clin. Orthop. Relat. Res.* 400, 77–87.
- Parentis, M.A., Jobe, C.M., Pink, M.M., 2004. An anatomic evaluation of the active compression test. *J. Shoulder Elbow Surg.* 13 (4), 410–416.

- Parentis, M.A., Glousman, R.E., Mohr, K.S., et al., 2006. An evaluation of the provocative tests for superior labral anterior posterior lesions. *Am. J. Sports Med.* 34 (2), 265–268.
- Powell, J.W., Huijbregts, P.A., 2006. Concurrent criterion-related validity of acromioclavicular joint physical examination tests: a systematic review. *J. Man. Manip. Ther.* 14 (2), E19–E29.
- Roberts, C.S., Davila, J.N., Hushek, et al., 2002. Magnetic resonance imaging analysis of the subacromial space in the impingement sign positions. *J. Shoulder Elbow Surg.* 11 (6), 595–599.
- Robinson, C.M., Aderinto, J., 2005. Recurrent posterior shoulder instability. *J. Bone Joint Surg. Br.* 87 (4), 883–892.
- Snyder, S.J., Karzel, R.P., Del Pizzo, W., et al., 1990. SLAP lesions of the shoulder. *Arthroscopy* 6 (4), 274–279.
- Speer, K.P., Hannafin, J.A., Altchek, D.W., et al., 1994. An evaluation of the shoulder relocation test. *Am. J. Sports Med.* 22 (2), 177–183.
- Stefko, J.M., Jobe, F.W., VanderWilde, R.S., et al., 1997. Electromyographic and nerve block analysis of the subscapularis lift-off test. *J. Shoulder Elbow Surg.* 6 (4), 347–355.
- Stetson, W.B., Templin, K., 2002. The crank test, the O'Brien test, and routine magnetic resonance imaging scans in the diagnosis of labral tears. *Am. J. Sports Med.* 30 (6), 806–809.
- Struhl, S., 2002. Anterior internal impingement: an arthroscopic observation. *Arthroscopy* 18 (1), 2–7.
- Suder, P.A., Hougaard, K., Frich, L.H., et al., 1994. Intraarticular findings in the chronically painful shoulder: a study of 32 post-traumatic cases. *Acta Orthop. Scand.* 65 (3), 339–343.
- Tzannes, A., Murrell, G.A., 2002. Clinical examination of the unstable shoulder. *Sports Med.* 32 (7), 447–457.
- Tzannes, A., Paxinos, A., Callanan, M., et al., 2004. An assessment of the inter-examiner reliability of tests for shoulder instability. *J. Shoulder Elbow Surg.* 13 (1), 18–23.
- Valadie, A.L., Jobe, C.M., Pink, M.M., et al., 2000. Anatomy of provocative tests for impingement syndrome of the shoulder. *J. Shoulder Elbow Surg.* 9 (1), 36–46.
- Walton, J., Mahajan, S., Paxinos, A., et al., 2004. Diagnostic values of tests for acromioclavicular joint pain. *J. Bone Joint Surg. Br.* 86 (4), 807–812.
- Yergason, R.M., 1931. Supination sign. *J. Bone Joint Surg. Br.* 13, 160.
- Zaslav, K.R., 2001. Internal rotation resistance strength test: a new diagnostic test to differentiate intra-articular pathology from outlet (Neer) impingement syndrome in the shoulder. *J. Shoulder Elbow Surg.* 10 (1), 23–27.

ELBOW

A TENDON TESTS 90

Tennis elbow test 90

Golfer's elbow test 93

B LIGAMENT/INSTABILITY TESTS 95

Valgus test 95

Varus test 97

Posterolateral pivot shift test 98

Chair push-up test 101

C NEUROLOGICAL TESTS 103

Tinel's test 103

Pressure provocation test 105

Ulnar nerve flexion test 107

Pinch grip test 109

A TENDON TESTS

Tennis elbow test

Purpose

To test for a contractile lesion of the wrist extensor tendons most commonly involving the common extensor origin (CEO).

Technique

Patient position

Standing with the affected elbow fully extended and the forearm pronated.

Clinician position

Standing on the affected side, the clinician supports the patient's arm by allowing it to rest on his or her own upper arm. Both the clinician's arms are then extended and pronated so that the thumbs can be placed on the palmar aspect of the patient's wrist to provide support and counter-pressure while the fingers are placed over the dorsum of the extended wrist.

Fig. 3.1 • Tennis elbow test.



Action and positive test

The patient contracts the wrist extensors isometrically as strongly as possible against resistance. A positive test is indicated by reproduction of pain over the lateral aspect of the elbow.

Clinical context

Tennis elbow is the most commonly encountered lesion at the elbow. It affects 1–3% of the population with prevalence peaking between the ages of 40 and 50 years, particularly among men, who are twice as likely to present with the condition (Bulstrode et al 2002). The common view is that it is a self-limiting condition with natural resolution within a year, but in a substantial number of cases the condition persists and can cause pain and disability for much longer (Bulstrode et al 2002), a scenario commonly encountered in clinical practice. Such a chronic presentation is usually associated with degenerative tendinopathy resulting in a reduction in tensile strength and tendon extensibility. Patients often report more diffuse pain and tenderness, functional weakness and limitation of elbow extension, particularly on waking.

There are a multitude of other similar isometric resisted tests which are generally accepted among clinicians as being diagnostic for tennis elbow, with provocation of lateral elbow pain signifying a positive test. The basic provocative test can be sensitized by adding resistance to third finger extension which intensifies the action of extensor carpi radialis brevis (ECRB) or resisted radial deviation of the wrist with the elbow in full extension which also targets the tendons of extensor carpi radialis longus and brevis. *Cozen's test* is a further variation where the affected elbow is fully extended while the clinician applies pressure over the CEO with a thumb. The patient pronates the forearm and makes a fist while the clinician provides resistance over the radial aspect of the patient's hand so that isometric extension and radial deviation is resisted.

There is little evidence to support the use of any particular diagnostic test for tennis elbow, although provocation of lateral elbow pain on resisted wrist extension and tenderness over the lateral epicondyle were found to be the most commonly used indicators among a sample of Scottish physiotherapists (Greenfield & Webster 2002), and, given the predictable history and well-localized pain, the clinician can be reasonably confident that positive findings to the provocative tests point strongly to a contractile lesion of the common extensor tendon.

Clinical tip

Rarely, the condition may be complicated by compression of the posterior interosseous branch of the radial nerve, either as a primary lesion or secondary to a tendinopathy at the CEO. Distinctively, this may result in paraesthesiae in the forearm, tenderness over the course of the nerve in the forearm, as well as the more common findings of pain on resisted third finger extension and limitation to passive elbow extension (Roles & Maudsley 1972). Care should therefore be taken in the differential diagnosis of atypical or resistant cases as radial nerve compression has the capacity to mimic tennis elbow presentation (Stanley 2006).

EXPERT OPINION	COMMENTS
★★★	<p>Tennis elbow test</p> <p>The most common site for the condition to present is at the teno-osseous junction where the CEO (composed of ECRB, extensor carpi ulnaris, extensor digitorum and extensor indicis) attaches to the small anterior facet of the lateral epicondyle. The other potential sites to exclude are the attachment of extensor carpi radialis longus on the lower third of the lateral supracondylar ridge, the body of the common extensor tendon (approximately 2 cm distal to the CEO) and the muscle belly lying deep to the brachioradialis muscle in the forearm.</p>

CEO = common extensor origin

ECRB = extensor carpi radialis brevis

Related tests

While the majority of tests aim to test the contractile unit by generating a contraction, the *Mills' test* (Fig. 3.2) involves the application of a passive longitudinal stretch to the tendon. The patient sits with the shoulder slightly abducted, elbow flexed to 90°, forearm pronated and wrist flexed so that the palm of the hand is facing the ceiling. Standing behind the patient on the affected side, one hand cups the upper arm for support and takes the arm into about 70° of abduction. The thumb of the other hand is then placed in the patient's palm between the index finger and thumb and the fingers wrapped around the dorsum of the wrist, which enables the forearm to be maintained in full pronation and the wrist in flexion. While maintaining this position, the elbow is extended slowly

(see Fig. 3.2A and Fig. 3.2B). A positive test is indicated by reproduction of the patient's pain over the common extensors and, depending on the chronicity and severity, will occur in varying degrees of terminal extension. This test can also place considerable stress on the radial nerve and careful discrimination should therefore be exercised to exclude neural involvement. Stress on the nerve can be minimized by any or all of the following: reducing the degree of shoulder abduction, avoiding taking the shoulder into extension, allowing some elevation of the shoulder girdle, and placing the cervical spine in a degree of side-flexion towards the painful elbow.

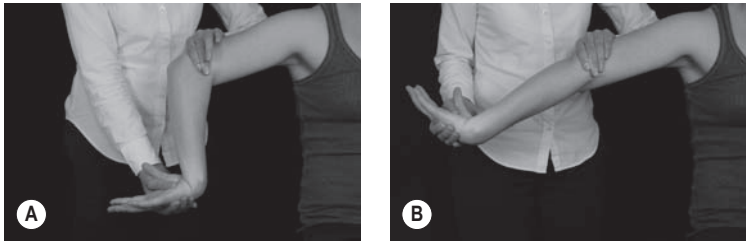

Fig. 3.2 • Mills' test, start position (A) and end position (B).

Golfer's elbow test

Purpose

To test for a contractile lesion of the wrist flexor tendons most commonly involving the common flexor origin (CFO).

Technique

Patient position

Sitting or standing with the elbow fully extended and the forearm pronated.

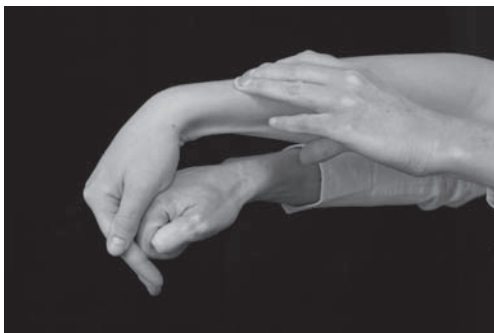Clinician position

Standing adjacent to the patient's affected side using the hand nearest the patient, the clinician fixes the lower forearm while supporting the patient's upper arm over the crook of the elbow. The other hand is formed into a fist and placed in the palm of the patient's flexed wrist.

Action and positive test

The patient contracts the wrist flexors isometrically as strongly as possible against resistance. A positive test is indicated by reproduction of pain over the medial aspect of the elbow.

Fig. 3.3 • Golfer's elbow test



Clinical context

The term medial epicondylitis implies that the process is purely inflammatory but golfer's elbow is more accurately described as a degenerative tendinopathy involving the common flexor tendons at their attachment on the anterior aspect of the medial epicondyle of the humerus. The underlying pathology is similar in both tennis and golfer's elbow where collagen formation becomes disordered with increased fibroblast and vascular content apparent (Atkins et al 2010). In tennis elbow, this process has been associated with tendon tears, although such significant breakdown of the tendon is uncommon at the CFO (Bulstrode et al 2002). The muscles most commonly contributing to unaccustomed or overuse loading of the CFO are pronator teres and flexor carpi radialis, with the others (palmaris longus, flexor carpi ulnaris and flexor digitorum superficialis) less commonly involved (Bulstrode et al 2002). Because of the close proximity of the ulnar nerve to the CFO, ulnar nerve symptoms may co-exist in some patients with golfer's elbow (Bulstrode et al 2002) and the presence of paraesthesiae distal to the site of compression would require further evaluation (see Tinel's test, p. 103, and the ulnar nerve flexion test, p. 107).

There is no evidence on the accuracy of this test although, given the very specific presentation of this condition, the clinician can be reasonably confident that a positive test is diagnostic.

Clinical tip

Once found to be positive, the clinician will then need to establish the exact site of the lesion by palpation in order to deliver effective treatment. The whole tendon is usually tender on palpation but the primary site is commonly located at the teno-osseous junction on the anterior facet of the medial epicondyle. The musculotendinous junction, located approximately a thumb's width distally, is less frequently encountered.

Variations

The CFO can also be stressed by applying static resistance to pronation or resistance through the full range of wrist flexion. Passive supination of the forearm with full wrist extension provides a longitudinal stress to the tendon and may also elicit pain.

B LIGAMENT/INSTABILITY TESTS

Valgus test

Aka

Jobe's test

Purpose

To test the integrity of the medial collateral ligament (MCL) of the elbow.

Technique

Patient position

Standing with the elbow flexed to 20–30° and fully supinated.

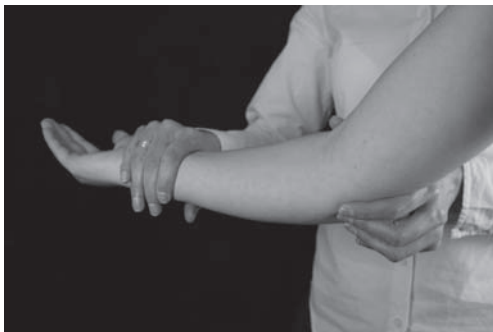Clinician position

Standing on the affected side, one hand stabilizes the humerus by holding it in external rotation above the lateral aspect of the elbow, while being able to palpate the joint line medially with the fingers. The other hand wraps around the medial aspect of the lower forearm.

Action and positive test

A valgus stress is applied to the elbow by abducting the forearm on the humerus. Tension in the ligament can often be felt as the stress is applied. Pain, excessive valgus movement or loss of the normal ligamentous end-feel indicate a positive test.

Fig. 3.4 • Elbow valgus test.



Clinical context

Valgus instability can occur following an acute injury or as a result of chronic strain. Rupture of the MCL following trauma may be associated with injury to other medial structures such as the common flexor origin (CFO) and ulnar nerve. Repeated high-speed overhead activities associated with throwing sports can also result in microtrauma and chronic strain. If other medial structures are affected, the patient may complain of pain, weakness, neurological symptoms or flexion contracture secondary to posteromedial olecranon impingement (Lee & Rosenwasser 1999).

A study examining the range of valgus movement in cadavers where the MCL was compromised by a surgical incision found that complete release was required for between 4 and 10mm of ulno-humeral joint gapping to be noted arthroscopically. The maximum opening was seen with the radio-ulnar joint positioned in pronation with between 60° and 75° of elbow flexion (Field & Altchek 1996), which suggests that in order to stress the ligament comprehensively the test should be repeated in this position (see variations). In a study of normal elbows, significant gapping was noted under radiographic examination when 25N of valgus stress was applied; this degree of 'normal' gapping may lead the clinician to falsely identify instability unless comparison with the opposite limb is made (Lee et al 1998).

Clinical tip

Because of the possibility of concurrent injury to the CFO and the ulnar nerve resulting from valgus injury or strain, further evaluation of these structures may be necessary (see golfer's elbow test, p. 93; ulnar nerve flexion test, p. 107; pressure provocation test, p. 105; Tinel's test, p. 103).

Variations

The ligament can be tested through range with the *moving valgus stress test*. The examiner applies a constant valgus stress to the fully flexed elbow which is then passively extended while maintaining the valgus stress. A positive test is indicated by medial elbow pain between 120° and 70° of elbow flexion.

TABLE 3.1 MOVING VALGUS STRESS TEST

Author and year	LR+	LR –	Target condition
O' Driscoll et al 2005	4 ★	0 ★★★	Medial collateral ligament pathology

Varus test

Purpose

To test the integrity of the lateral collateral ligament of the elbow.

Technique

Patient position

Standing with the elbow flexed to 20–30° and fully supinated.

Clinician position

Standing in front of the patient, one hand stabilizes the humerus at the elbow by gently gripping above the medial aspect of the elbow while being able to palpate the radiohumeral joint line laterally. The other hand wraps around the lateral aspect of the lower forearm.



Fig. 3.5 • Elbow varus test.

Action and positive test

A varus stress is applied to the elbow by adducting the forearm on the humerus. Tension in the ligament can often be felt as the stress is applied. Pain, excessive varus movement or loss of the normal ligamentous end-feel indicates a positive test.

Clinical context

The normal valgus carrying angle at the elbow means that varus instability in isolation is not commonly encountered and is more likely to be found in posterolateral rotatory instability (see posterolateral pivot shift test, p. 98; posterolateral rotatory drawer test, p. 100; chair push-up test, p. 101). This occurs as a result of lateral collateral ligament disruption which can be associated with acute elbow dislocation, chronic instability following trauma *or* excessive use of the arms for weight-bearing purposes (e.g. crutch use) (O' Driscoll 2000).

Posterolateral pivot shift test

Aka

Lateral pivot shift apprehension test

Purpose

To test for posterolateral rotatory instability (PLRI) of the elbow and the integrity of the lateral collateral ligament (LCL).

Technique

Patient position

Lying supine with the forearm supinated, the shoulder is elevated to 180° and the elbow flexed to approximately 20°. The arm is thus above the head with the palm of the hand facing the floor and the olecranon pointing to the ceiling.

Clinician position

Standing at the affected side of the patient, one hand holds the outer aspect of the forearm just distal to the elbow while the other hand holds just above the wrist, wrapping the fingers around the palmar aspect and the thumb over the dorsal aspect.

Action

The forearm is maintained in full supination while an axial compression is applied through the radius and ulna towards the humerus, followed by a valgus stress to the forearm.

Positive test

If performed on a conscious patient, a positive test is indicated by pain and apprehension as, sensing that the elbow could dislocate, the patient is unlikely to relax sufficiently to allow completion of the test. The remaining component, therefore, can only be performed under anaesthesia. The elbow is taken into further flexion and at between 40° and 70° the radius and ulna sublux posterolaterally from the humerus, a movement often accompanied by a palpable click. This may produce both a visible prominence where the radial head subluxes and an associated skin dimple in the gap between the radial head and humerus. Reduction occurs as the elbow is flexed beyond 90° or returned to the start position of extension.

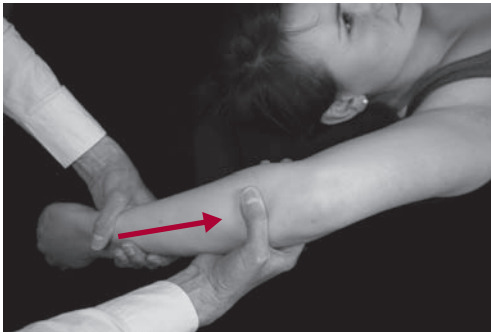


Fig. 3.6 • Posterolateral pivot shift test, prior to further elbow flexion being added. The arrow indicates the direction of axial compression.

Clinical context

A history of elbow dislocation or other significant trauma will guide the clinician to consider the possibility of PLRI and should also be considered if the patient complains of symptoms of recurrent pain, catching, clicking or locking. The mechanism of injury is often a fall on an outstretched hand and the posterolateral pivot shift test reproduces similar but more controlled stress to the joint. At the moment of impact, axial compression drives the radius and ulna against the humerus with the elbow in a semi-flexed position. The forearm supinates on the fixed hand, and this, combined with a valgus stress, causes the ulna (and radius) to externally rotate away from the trochlea of the humerus. A spectrum of soft tissue injury occurs, starting with disruption of the ulnar portion of the LCL. This may cause only momentary subluxation but is sufficient to give rise to positive instability testing on examination. If the

bony displacement is more marked, frank dislocation occurs with concurrent injury to the other portions of the LCL and the elbow joint capsule. Finally the medial collateral ligament is injured. Associated fractures and injuries to the common extensor and flexor origins can also accompany the dislocation injury.

Where PLRI is present the symptoms occur most commonly when the elbow is extended with the forearm in supination. Recurrent frank re-dislocation is rare but the incidence of instability symptoms following simple elbow dislocation is reported to lie somewhere between 15% and 35% (Bulstrode et al 2002). PLRI can also occur as a consequence of connective tissue disorders causing laxity or as a result of chronic overuse (e.g. prolonged use of elbow crutches) (O'Driscoll 2000). Although not extensively evaluated, this test was shown to be more sensitive for PLRI than the posterolateral rotatory drawer test (see below) and the chair push-up test (see p. 101) (O'Driscoll 2000). In a small study of patients with known elbow instability, it was found to be 100% sensitive when performed under anaesthesia but this dropped to only 38% in the conscious patient (Regan & Lapner 2006).

Clinical tip

Further investigation including plain and stress X-rays, MRI, CT arthrography, examination under anaesthesia and arthroscopy are likely to be indicated if a diagnosis of PLRI is suspected (Bulstrode et al 2002).

EXPERT OPINION	COMMENTS
★★	The <i>posterolateral rotatory apprehension test</i> is a variation where the axial compression component is removed. A positive test is indicated by apprehension rather than visible or palpable subluxation and may serve as a useful starting point if PLRI is suspected.

Related test

The *posterolateral rotatory drawer test* (Fig. 3.7) can also be used to assess for PLRI of the elbow. The patient lies supine with the forearm supinated, the shoulder elevated and the elbow flexed to approximately 60°. The arm is therefore above the head with the palm of the hand facing the floor and the olecranon pointing towards the ceiling. Standing adjacent to the affected side, one hand

stabilizes the humerus just above the elbow joint. The other hand wraps around the proximal aspect of the radius and ulna from the radial side, so that the thumb lies on the posterior surface with the fingers lying anteriorly. Stabilization of the humerus is maintained while gliding the radius and ulna posteriorly from the humerus with some supination of the forearm. During the test the radius and ulna will rotate around an intact medial collateral ligament with excess movement, elbow pain, clicking and/or apprehension indicating a tear of the lateral collateral ligament and associated posterolateral rotatory instability. An additional finding may be the appearance of a dimple behind the radial head (O'Driscoll 2000). This test is comparable in action to the drawer test or Lachman's test at the knee.

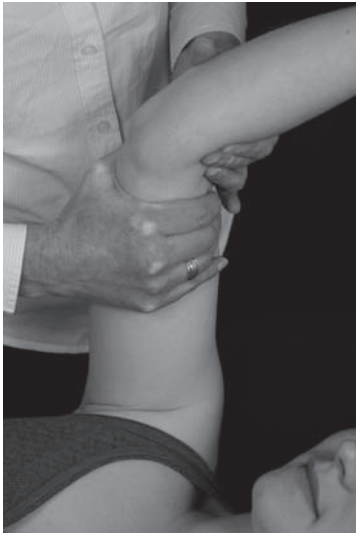

Fig. 3.7 • Posterolateral rotatory drawer test.

Chair push-up test

Aka

Stand-up test

Chair sign

Purpose

To test for posterolateral rotatory instability (PLRI) of the elbow and the integrity of the lateral collateral ligament.

Technique

Patient position

The patient sits on a chair with the hands resting on the sides of the seat or on the chair arms.

Action and positive test

The patient takes their weight through their arms and actively pushes up to assist the transition into a standing position. Reproduction of the pain, apprehension, clicking or locking are suggestive of lateral collateral ligament failure and PLRI instability.

Fig. 3.8 • Chair push-up test.



Clinical context

Because PLRI diagnostic testing has not been thoroughly evaluated, using a variety of tests is more likely to direct the clinician to consider PLRI as a possible diagnosis (see posterolateral pivot shift test, p. 98; posterolateral rotatory drawer test, p. 100) (O'Driscoll 2000). The chair push-up test was evaluated in a small study of patients

undergoing surgery for recurrent dislocation and was found to be sensitive in 87.5% of patients but, due to the absence of true negative cases, specificity could not be calculated (Regan & Lapner 2006).

See posterolateral pivot shift test (p. 98) for further clinical context.

Clinical tip

The *chair push-up test* reproduces the functional movement most likely to reproduce PLRI symptoms, i.e. elbow extension and forearm supination. Anticipating the outcome, the patient is unlikely to be enthusiastic about this test and apprehension or an unwillingness to perform it are the most likely outcomes.

Variations

The *active floor push-up test* has the patient lying prone with their hands resting flat on the floor, approximately level with their head. The patient then attempts to do a push-up using their arms only. A positive test is indicated by apprehension, dislocation or guarding as end-range extension is reached. In a small study the sensitivity of this test for PLRI was reported to be 87.5% which rose to 100% when the results of this test and the *chair push-up test* were combined (Regan & Lapner 2006). This is obviously a test requiring significant upper body strength and will not, therefore, be suitable for all patients.

C NEUROLOGICAL TESTS

Tinel's test

Purpose

To test for compression neuropathy of the ulnar nerve at the elbow (cubital tunnel syndrome).

Technique

Patient position

The patient sits or stands.

Clinician position

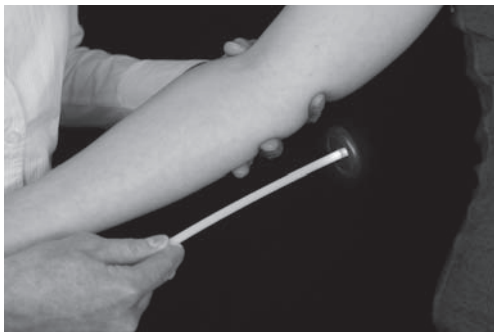The arm is taken away from the patient's side to expose the medial aspect of the elbow to enable the clinician to identify and palpate

the 'cord-like' ulnar nerve just proximal to the cubital tunnel (see clinical tip), where it lies in a groove on the posterior aspect of the medial epicondyle.

Action and positive test

The area immediately proximal to the cubital tunnel is identified with palpation and then tapped using a reflex hammer a few times. A positive sign is indicated by paraesthesiae in the distribution of the ulnar nerve (little finger, ulnar half of the ring finger and the medial aspect of the hand).

Fig. 3.9 • Tinel's test.



Clinical context

The pathophysiology of compressive neuropathy is thought to have a bearing on the outcome of Tinel's test, as a positive finding is usually only found in the presence of regenerating axons distal to the compression site. In the early stages of the condition, the compression has not been severe or prolonged enough to cause significant Wallerian degeneration and the test is therefore negative. In more advanced cases, Tinel's may be negative because, after prolonged compression, there is no further axonal regeneration taking place. Tinel's is therefore most useful in the middle stages of the condition, where some axonal recovery is underway (Kuschner et al 2006).

In a study of 200 asymptomatic individuals, the test triggered symptoms in 36% of the population (Kuschner et al 2006), confirming the propensity for false positives exposed in an earlier study (Rayan et al 1992). In a small population of patients with proven cubital tunnel syndrome, Tinel's test demonstrated 70% sensitivity and 98% specificity (Novak et al 1994). Generally there is wide

agreement in the literature that clinical examination combined with the patient history is sufficiently sensitive and specific to diagnose cubital tunnel syndrome and may be more valuable than electrodiagnostics which, in the early stages of the condition or in mild cases, is not sufficiently sensitive or specific to detect a lesion (Dellon 1989, Greenwald et al 2006, McPherson & Meals 1992, Novak et al 1994).

TABLE 3.2 TINEL'S TEST

Author and year	LR+	LR-	Target condition
Novak et al 1994	35 ★★★	0.3 ★	Ulnar nerve entrapment

Clinical tip

The cubital tunnel is formed by the bony walls of the olecranon and the medial epicondyle of the humerus. The roof is formed by the overlying fascial bands of flexor carpi ulnaris and the medial ligament of the elbow. The ulnar nerve is vulnerable as it enters, traverses and exits the tunnel.

There is no standardized method of applying Tinel's test but the technique described above produced relatively favourable results (Novak et al 1994) although the attendant problems of generating a false-positive with Tinel's test should not be underestimated (Gerr & Letz 1998).

The ulnar nerve is also vulnerable to compression as it passes through the tunnel of Guyon at the wrist but at this point it has only a sensory function. More proximally at the elbow, compression may compromise motor function and assessment for weakness of the muscles supplied by the nerve distal to this point (i.e. medial side of flexor digitorum profundus, flexor carpi ulnaris, the hypothenar muscles and the third and fourth lumbricals) may help to make a distinction.

Pressure provocation test

Purpose

To test for compression neuropathy of the ulnar nerve at the elbow (cubital tunnel syndrome).

Technique

Patient position

Sitting with the elbow flexed to approximately 20° and the forearm supinated.

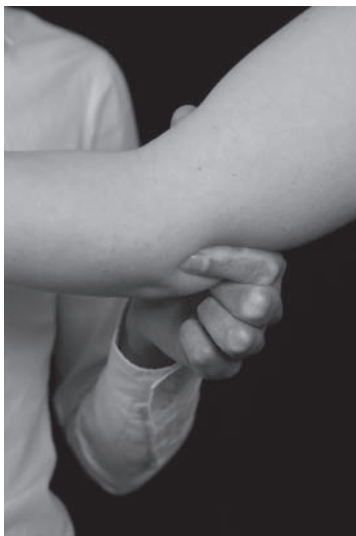Clinician position

The clinician places an index finger over the ulnar nerve just proximal to the cubital tunnel (see clinical tip Tinel's test, p. 103)

Action and positive test

The pressure is maintained over the ulnar nerve for 60 seconds. A positive test is indicated by an increase in pain, paraesthesiae or numbness in the distribution of the ulnar nerve over the little finger, ulnar half of the ring finger and medial aspect of the hand.

Fig. 3.10 • Pressure provocation test.



Clinical context

Cubital tunnel syndrome is the second most frequent entrapment neuropathy in the upper limb. A comprehensive history and physical examination is generally considered more valuable in the diagnosis of the condition than electrodiagnostics, particularly in early or mild cases (Dellon 1989, Greenwald et al 2006, Kushner et al 2006, McPherson & Meals 1992). When the elbow is fully flexed, the cubital

tunnel narrows by approximately 55% as the flexor carpi ulnaris aponeurosis and the arcuate ligament tighten, causing an increase in pressure on the ulnar nerve, and this corresponds to the position most likely to reproduce the patient's symptoms (Kuschner et al 2006).

A controlled study compared responses to provocative tests for ulnar nerve entrapment in symptomatic and asymptomatic subjects. The pressure provocation test was maximally sensitive when maintained for 60 seconds but this dropped if the pressure was only applied for 30 seconds; specificity remained high regardless (Novak et al 1994).

TABLE 3.3 PRESSURE PROVOCATION TEST

Author and year	LR+	LR-	Target condition
Novak et al 1994	44.5 ★★★	0.1 ★★	Ulnar nerve entrapment

Ulnar nerve flexion test

Aka

Elbow flexion test

Purpose

To test for compression neuropathy of the ulnar nerve at the elbow (cubital tunnel syndrome).

Technique

Patient position

The patient sits with the elbow fully flexed with the forearm supinated and wrist in neutral for 1 minute.

Positive test

A positive test is indicated by symptoms of paraesthesiae or numbness in the little finger, ulnar half of the ring finger and medial aspect of the hand.

Clinical context

Cubital tunnel syndrome at the elbow may be caused by obvious extrinsic factors such as arthritis or a previous fracture or, more commonly, by the intrinsic factors associated with compression neuropathies. The patient may complain of pain, numbness and paraesthesiae in the ulnar nerve distribution of the hand. Weakness in the muscles innervated by the ulnar nerve (flexor carpi ulnaris and medial portion

Fig. 3.11 • Ulnar nerve flexion test.



of flexor digitorum profundus, the hypothenar muscles and the third and fourth lumbricals) will only become apparent in long-standing or severe cases. Variations exist in both the test position and the length of hold recommended, although sustained full elbow flexion is universally included (Kuschner et al 2006). In a controlled study comparing responses in symptomatic and asymptomatic subjects, this test demonstrated a good degree of both sensitivity and specificity when the position was held for 1 minute (Novak et al 1994). The risk of a false positive result increased from a reported 3.6% of normal subjects when the position was held for 1 minute (Rosati et al 1998) to 20.5% if sustained for 3 minutes (Kuschner et al 2006), with paraesthesiae reproduced in the asymptomatic population – providing a good rationale for not maintaining the test position for longer than a minute. In subjects with proven electrophysiological evidence of cubital tunnel syndrome, the incidence of a positive test at 3 minutes increases to 86% (Buehler & Thayer 1988).

It is also possible to generate ulnar nerve paraesthesiae in an asymptomatic patient by adding neural sensitization (i.e. any of the following components: scapular retraction and depression, shoulder abduction, elbow flexion, forearm pronation and wrist extension) to

the test. In a study of normal subjects ulnar nerve paraesthesiae were reproduced in 10% of the sample with the wrist and shoulder held in a neutral position and this rose marginally to 13% with the addition of shoulder abduction and wrist extension (Rayan et al 1992).

TABLE 3.4 ULNAR NERVE FLEXION TEST

Author and year	LR+	LR–	Target condition
Novak et al 1994	75 ★★★	0.25 ★	Ulnar nerve entrapment

Variations

The *combined pressure provocation and flexion test* is a variation of the ulnar nerve flexion test. Full elbow flexion is maintained while the clinician applies pressure over the ulnar nerve just proximal to the cubital tunnel for 30 seconds. A positive test is indicated by reproduction of the patient's symptoms in the distribution of the ulnar nerve.

TABLE 3.5 COMBINED PRESSURE PROVOCATION AND FLEXION TEST

Author and year	LR+	LR–	Target condition
Novak et al 1994	30 ★★★	0.09 ★★★	Ulnar nerve entrapment

Pinch grip test

Aka

'OK' sign

Purpose

To test for compression of the anterior interosseous branch of the median nerve.

Technique

Patient position

This is an active test performed by the patient who is asked to approximate the tips of the thumb and index finger together in a pinch grip position.

Action and positive test

The clinician checks to assess that the patient has flexed the distal interphalangeal (IP) joint of the index finger and IP joint of the thumb (Fig. 3.12A). A positive test is indicated by the patient being unable to approximate the tips of the thumb and index fingers and instead the pads of the digits are pinched together (Fig. 3.12B).

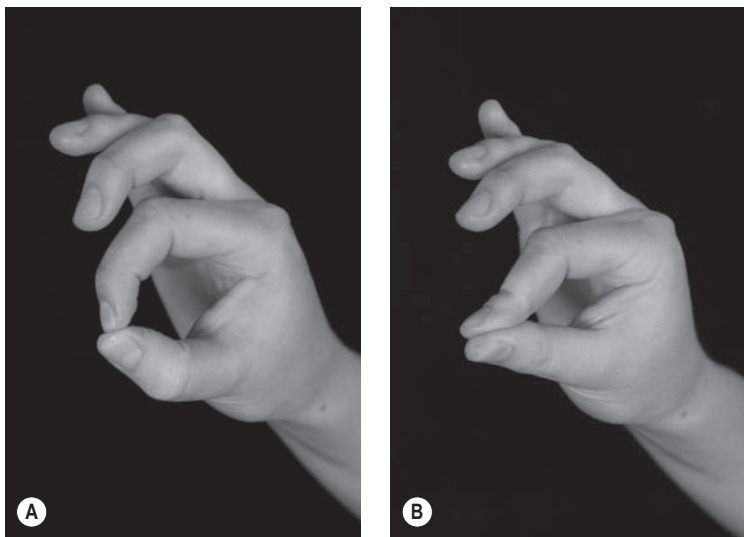


Fig. 3.12 • A normal pinch grip test response (A). A positive test indicated by an inability to approximate the thumb and finger tips (B).

Clinical context

The anterior interosseous nerve branches posteriorly from the median nerve approximately 2–8 cm below the medial epicondyle, running between the two heads of pronator teres to supply pronator quadratus, flexor pollicis longus and the lateral part of flexor digitorum profundus.

The nerve does not provide sensory innervation so external pressure or compression caused by fascial bands within pronator teres or flexor digitorum superficialis (Standing 2005) results in weakness, a condition known as Kiloh–Nevin syndrome (Farber & Bryan 1968). External pressure more proximally on the main branch of

the median nerve ('Saturday night palsy') will also cause sensory symptoms, epitomized by significant paraesthesiae on waking.

References

- Atkins, E., Kerr, E., Goodlad, J., 2010. *A Practical Approach to Orthopaedic Medicine*, third ed. Churchill Livingstone, Edinburgh.
- Buehler, M.J., Thayer, D.T., 1988. The elbow flexion test: a clinical test for the cubital tunnel syndrome. *Clin. Orthop. Relat. Res.* 233, 213–216.
- Bulstrode, C., Buckwalter, J., Carr, A., et al., 2002. *Oxford Textbook of Orthopaedics and Trauma*. Oxford University Press, Oxford.
- Dellon, A.L., 1989. Review of treatment results for ulnar nerve entrapment at the elbow. *J. Hand Surg. Am.* 14 (4), 688–700.
- Farber, J.S., Bryan, R.S., 1968. The anterior interosseous nerve syndrome. *J. Bone Joint Surg.* 50, 521–523.
- Field, L.D., Altchek, D.W., 1996. Evaluation of the arthroscopic valgus instability test of the elbow. *Am. J. Sports Med.* 24 (2), 177–181.
- Gerr, F., Letz, R., 1998. The sensitivity and specificity of tests for carpal tunnel syndrome vary with the comparison subjects. *J. Hand Surg. Br.* 23 (2), 151–155.
- Greenfield, C., Webster, V., 2002. Chronic lateral epicondylitis: a survey of current practice in the outpatient departments in Scotland. *Physiotherapy* 88 (10), 578–594.
- Greenwald, D., Blum, L., Adams, D., et al., 2006. Effective surgical treatment of cubital tunnel syndrome based on provocative clinical testing without electrodiagnostics. *Plast. Reconstr. Surg.* 117 (5), 87–91.
- Kuschner, S.H., Ebramzadeh, E., Mitchell, S., 2006. Evaluation of elbow flexion and Tinel tests for cubital tunnel syndrome in asymptomatic individuals. *Orthopaedics* 29 (4), 305–308.
- Lee, M.L., Rosenwasser, M.P., 1999. Chronic elbow instability. *Orthop. Clin. North Am.* 30 (1), 81–89.
- Lee, G.A., Katz, S.D., Lazarus, M.D., 1998. Elbow valgus stress radiography in an uninjured population. *Am. J. Sports Med.* 26 (3), 425–427.
- McPherson, S.A., Meals, R.A., 1992. Cubital tunnel syndrome. *Orthop. Clin. North Am.* 23 (1), 111–123.
- Novak, C.B., Lee, G.W., Mackinnon, S.E., et al., 1994. Provocative testing for cubital tunnel syndrome. *J. Hand Surg.* 19 (5), 817–820.
- O'Driscoll, S.W., 2000. Classification and evaluation of recurrent instability of the elbow. *Clin. Orthop. Relat. Res.* 370, 34–43.
- O'Driscoll, S.W., Lawton, R.L., Smith, A.M., 2005. The moving valgus stress test for medial collateral ligament tears of the elbow. *Am. J. Sports Med.* 33 (2), 231–239.
- Rayan, G.M., Jensen, C., Duke, J., 1992. Elbow flexion test in the normal population. *J. Hand Surg.* 17 (1), 86–89.

- Regan, W., Lapner, P.C., 2006. Prospective evaluation of two diagnostic apprehension signs for posterolateral instability of the elbow. *J. Shoulder Elbow Surg.* 15 (3), 344–346.
- Roles, N.C., Maudsley, R.H., 1972. Radial tunnel syndrome: resistant tennis elbow as a nerve entrapment. *J. Bone Joint Surg.* 54 (3), 499–508.
- Rosati, M., Martignoni, R., Spagnoli, G., et al., 1998. Clinical validity of the elbow flexion test for the diagnosis of ulnar nerve compression at the cubital tunnel. *Acta Orthop Belg* 64 (4), 366–370.
- Standring, S., 2005. *Gray's Anatomy*, thirty-ninth ed. Elsevier Churchill Livingstone, Edinburgh.
- Stanley, J., 2006. Radial tunnel syndrome: a surgeon's perspective. *J. Hand Ther.* 19 (2), 180–185.

WRIST AND HAND

A	LIGAMENT/INSTABILITY TESTS	114
	Piano key test	114
	Radial collateral ligament stress test	115
	Ulnar collateral ligament stress test	117
	Scaphoid shift test	119
	Lunotriquetral shear test	122
	Capitate apprehension test	124
B	TRIANGULAR FIBROCARILAGE COMPLEX (TFCC) TESTS	127
	TFCC load test	127
C	THUMB TESTS	129
	Axial compression test	129
	Finkelstein's test	131
	Ulnar collateral ligament laxity test	133
D	CARPAL TUNNEL TESTS	135
	Phalen's test	135
	Tinel's test	141
	Carpal compression test	145

A LIGAMENT/INSTABILITY TESTS

Piano key test

Purpose

To detect the presence of instability at the inferior radio-ulnar joint (IRUJ).

Technique

Patient position

Sitting with the forearm fully pronated and supported on a table.

Clinician position

Sitting facing the patient, one hand stabilizes the patient's hand in a neutral position while, approaching from the radial aspect, the index and middle fingers of the other hand are placed over the head of the ulna with the thumb providing some counterpressure under the base of the radius.

Action

Downward pressure is applied by the fingers on the distal ulna, mimicking the action of pressing down a piano key.

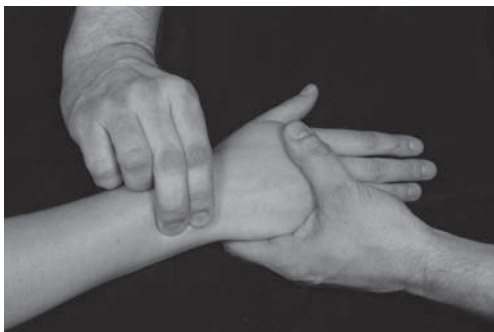Positive test

Pain accompanied by excess movement and a loss of the normal ligamentous end-feel is noted.

Clinical context

Isolated involvement of the IRUJ is rare and is usually associated with more significant injury at the wrist (i.e. fracture or dislocation).

Fig. 4.1 • Piano key test.



Minor disruption may cause pain as the primary sign and this would be well localized with tenderness easily elicited by palpation (see clinical tip). Pain at the end of passive pronation and supination would also be provocative. Where ligament disruption has occurred, excess movement will be accompanied by apprehension during certain activities, particularly in weight-bearing positions where its lack of stability is more seriously tested.

The IRUJ is often involved in inflammatory arthritis and in more severe cases, the synovitis afflicting the joint causes a destructive process resulting in pronounced loss of rotation, dorsal prominence and instability of the ulna, as well as localized swelling and loss of the normal function of the adjacent extensor carpi ulnaris, a condition known as *caput ulnae syndrome* (Brown & Neumann 2004). Given the associated joint stiffness, despite the instability at the IRUJ, the piano key test may not yield a positive result.

Clinical tip

The joint line is easily palpable on the dorsum of the lower forearm. The width of the wrist dorsally can be divided into three equal portions, making the joint line the marker between the most medial and middle sections.

If the result of this test is ambiguous further accessory testing of the IRUJ can be done to detect changes in range and end-feel.

EXPERT OPINION	COMMENTS
★★★	<p>Piano key test</p> <p>Especially useful to determine level of instability – only a very unstable joint will behave like a true ‘piano key’.</p>

Radial collateral ligament stress test

Aka

Wrist adduction test

Purpose

To stress the radial collateral ligament (RCL) and lateral capsule of the wrist in order to detect pain and/or laxity.

Technique

Patient position

Sitting with the wrist supported on a table.

Clinician position

One hand fixes the distal forearm by wrapping the fingers around the radius and ulna while the other grasps the hand, taking care not to involve the fingers or thumb.

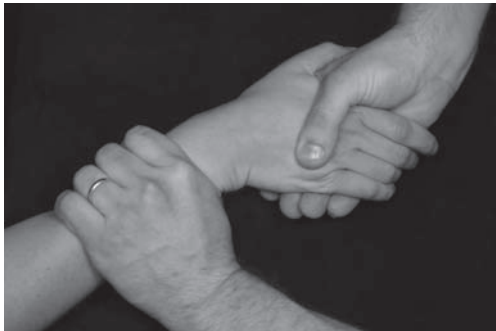Action

With the forearm fixed, the distal hand takes the wrist into ulnar deviation (wrist adduction) where normal range is between 30° and 45°.

Positive test

Pain is the most likely outcome but further evaluation would be needed if excessive range was noted suggesting significant disruption to the joint.

Fig. 4.2 • Radial collateral ligament stress test.



Clinical context

This test is most likely to identify an isolated sprain of the RCL where localized pain around the anatomical snuffbox would be the primary complaint. Depending on the severity of the trauma, a varying but equal degree of flexion/extension restriction may also be

present at the wrist as the ligament blends with, and reinforces, the lateral joint capsule, thereby causing capsular limitation. As the history is usually traumatic, careful screening is necessary (including X-ray evaluation in most cases) to eliminate fracture of the carpus – the scaphoid being the usual culprit. With pain reported in this area, osteoarthritis of the trapeziofirstmetacarpal joint (basal joint of the thumb; see axial compression test, p. 129) and de Quervain’s tenosynovitis (see Finkelstein’s test, p. 131) are other possible diagnoses to consider.

Clinical tip

The RCL can be found by identifying the radial styloid at the base of the anatomical snuffbox and moving the finger slightly distally with the wrist in a degree of radial deviation. The ligament and capsule are relaxed in this position. Keeping the finger in place, the RCL tautens (if intact) and becomes easily palpable as the wrist is passively taken into ulnar deviation.

Make sure the patient’s thumb is not involved in this movement in order to avoid stress being placed on the thumb abductor and extensor tendons which may result in a false positive finding being recorded.

EXPERT OPINION	COMMENTS
★	<p>Radial collateral ligament stress test</p> <p>Usually included as part of radiocarpal assessment without specifically testing the ligaments as they are rarely injured in isolation.</p>

Ulnar collateral ligament stress test

Aka

Wrist abduction test

Purpose

To stress the ulnar collateral ligament (UCL) and medial capsule of the wrist in order to detect pain and/or laxity.

Technique

Patient position

Sitting with the wrist supported on a table.

Clinician position

One hand fixes the distal forearm by wrapping fingers around the radius and ulna while the other grasps the hand, taking care not to involve the fingers or thumb.

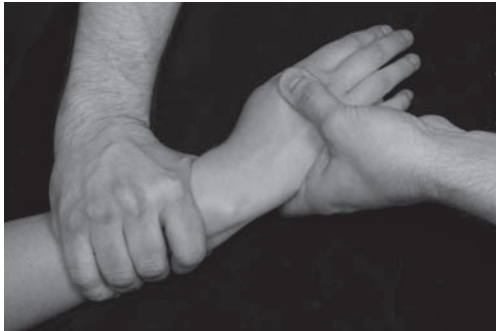Action

With the forearm fixed, the distal hand takes the wrist into radial deviation (wrist abduction) where normal range is around 15°.

Positive test

Pain is the most likely outcome but further evaluation would be needed if excessive range was noted, suggesting significant disruption to the joint.

Fig. 4.3 • Ulnar collateral ligament stress test.



Clinical context

The patient reports localized pain located at the inner, medial aspect of the wrist joint. If the UCL stress test is the only positive test, confirmation of the lesion can be made by palpation – tenderness is usually identifiable at its origin on the ulnar styloid. Isolated injury to the UCL is rare and, because of its anatomical connection, is more commonly associated with injury to the triangular cartilaginous complex (see TFCC test, p. 127). Medial wrist pain may also emanate from the inferior radio-ulnar joint (see piano key test, p. 114) and the extensor carpi ulnaris tendon.

Clinical tip

The ligament is most easily identified by finding the styloid with the wrist in ulnar deviation and then passively moving the wrist radially until the ligament can be felt tautening under the finger.

EXPERT OPINION	COMMENTS
★	Ulnar collateral ligament stress test Usually included as part of radiocarpal assessment without specifically testing the ligaments as they are rarely injured in isolation.

Scaphoid shift test

Aka

Watson test

Purpose

To establish the presence of abnormal movement of the scaphoid and lunate bones indicating instability or subluxation.

Technique

Patient position

The patient is seated with the flexed elbow resting on a table, the forearm vertically positioned and fully pronated so that the patient's palm faces the clinician.

Clinician position

Seated facing the patient, the examiner places the thumb in the palm and wraps the fingers around the metacarpals on the dorsum of the hand. The thumb of the second hand is placed over the tubercle of the scaphoid and counterpressure applied with the other fingers over the dorsum of the lower radius.

Action

Firm pressure is applied on the scaphoid while the hand is taken initially into ulnar deviation and slight extension to offload the scapholunate articulation (Fig. 4.4A). Maintaining the pressure on the scaphoid, the wrist is then taken slowly into radial deviation and slight flexion creating a subluxation force that stresses the articulation and exposes instability if present (Fig. 4.4B).

Positive test

Excessive movement of the scaphoid in relation to the lunate is detected along with some pain and/or apprehension. If subluxation occurs the proximal pole of the scaphoid shifts dorsally over the dorsal rim of the radius. Removing the pressure from the palmar aspect of the scaphoid and returning the wrist into some ulnar

deviation and extension will cause the scaphoid to shift back in a palmar direction to its reduced, normal position.

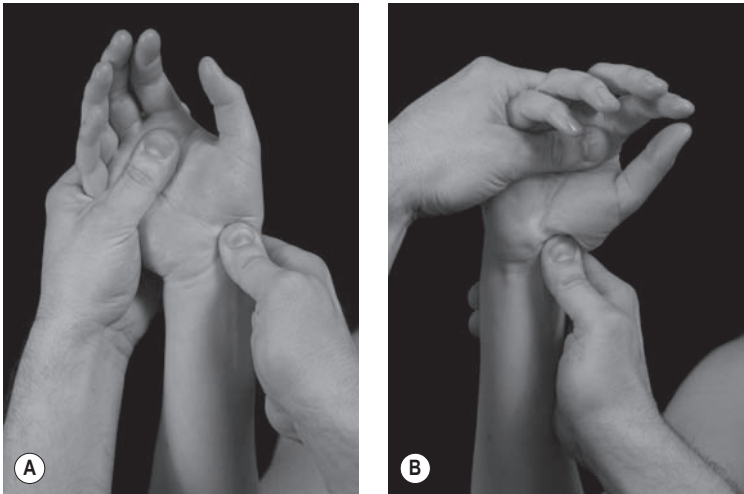


Fig. 4.4 • Scaphoid shift test: unloaded start position (A) and stress applied to the scapholunate joint (B).

Clinical context

Although comparatively rare, the instability that results from disruption of the scapholunate articulation is the most common carpal instability. A complete tear of the scapholunate ligaments, usually resulting from a severe hyperextension injury, will lead to significant scapholunate dissociation and disruption to the normal motion of the proximal carpal bones during wrist movement. Because of the loss of connection between the scaphoid and lunate, the scaphoid rotates into a degree of flexion leaving the lunate and triquetrum free to rotate into extension which causes pain, an inability to weight-bear on the wrist and an overall loss of function (Placzek & Boyce 2006). Chronic instability of the joint also strongly predisposes to a recognized sequence of osteoarthritis involving the unstable capitolunate and capitolunate articulations (particularly in the presence of a dorsally subluxed capitate) and, more latterly, the radioscaphoid and radiolunate joints, a sequence known as scapholunate advance collapse (SLAC) (Miller & Schweitzer 2005).

The normal extent of separation between the scaphoid and lunate bones should be less than 2mm (Gross et al 2002) but a diastasis of more than 3mm is pathognomonic of scapholunate dissociation and should be detectable on plain X-rays (McRae 1990). The evident space between the bones is known as the *Terry Thomas sign*, named after the 1960s comedian who famously had a gap between his two front teeth (Placzek & Boyce 2006).

Using a cadaver model where the wrist was progressively loaded in extension and ulnar deviation (the most common mechanism of injury), a sequential, four-staged pattern of injury was noted; scapholunate diastasis, dorsal subluxation of the capitate, disruption of the lunotriquetral ligament and complete dislocation of the scapholunate articulation (Brown & Neumann 2004). Subluxation of the capitate (see clinical tip) is therefore usually associated with injury to the proximal carpus although it does not have to involve catastrophic disruption of the scapholunate articulation (see capitate apprehension test, p. 124).

Clinical tip

It is not always necessary to reproduce subluxation with this test as it is usually painful for the patient and they are likely to indicate apprehension as the forces are gradually applied. The presence of pain and apprehension are good indicators of instability and, as an alternative, detecting increased excursion without causing subluxation can be achieved by applying an anterior/posterior glide to the scaphoid in a neutral position and comparing with the opposite side.

The possibility of capitate subluxation should be considered by observing the dorsum of the wrist in a flexed position where a bony prominence may be noted. Passive wrist extension will also be painfully blocked, particularly on weight-bearing.

Care should be taken when interpreting the findings as up to 30% of healthy wrists can give a false positive result due to general ligamentous laxity at the wrist. It is thought that repeating this dynamically (see variations), particularly when the patient makes a fist, reduces this tendency (Weiss & Finkelstein 2005).

EXPERT OPINION	COMMENTS
★★★	<p>Scaphoid shift test</p> <p>A tricky test to perform, as well as interpret, but very useful once perfected.</p>

Variations

The *scaphoid stress test* is a simple modification where the patient actively moves the wrist from ulnar to radial deviation while the scaphoid is stabilized by the examiner in the same way. Apprehension and/or a painful clunk during the movement demonstrates dynamic subluxation.

Lunotriquetral shear test

Aka

Ballottement test
Reagan's test
Shuck test

Purpose

To establish the presence of abnormal movement of the lunate and triquetral bones indicating instability or subluxation.

Technique

Patient position

The patient is seated with the forearm supinated and comfortably supported on a table.

Clinician position

Seated facing the patient, the clinician, using a pincer grip, stabilizes the lunate by placing a thumb on its palmar surface and fixes the dorsal surface with the index finger. The other hand grasps the combined bony mass of the pisiform and triquetral using the same pincer grip.

Action

With the lunate stabilized, the examiner moves the triquetral/pisiform in an anteroposterior direction. The test can be reversed by stabilizing the triquetral/pisiform and moving the lunate in the same plane.

Positive test

Excessive mobility of the triquetral in relation to the lunate when compared to the unaffected side is detected along with pain. Crepitus on movement is also sometimes noted.



Fig. 4.5 • Lunotriquetral shear test.

Clinical context

Differing descriptions for this test can be found in the literature and this has led to the same test being assigned several names. Injury to the lunotriquetral articulation is uncommonly encountered (see scaphoid shift test, p. 119) requiring impact in extension and radial deviation (Brown & Neumann 2004). A strain to the lunotriquetral ligament may be evident with localized tenderness and a positive test, but if the trauma has been sufficiently significant to cause disruption of the articulation, normal kinematics will be lost. The combined unit of the scaphoid and lunate rotate into flexion leaving the untethered triquetral to drift into extension. Pain, apprehension, a reluctance to move and weakness will all be reported by the patient, with a more significant injury likely to predispose to osteoarthritis (Placzek & Boyce 2006). Lunotriquetral ligament injury is often associated with triangular fibrocartilage complex (TFCC) tears (see TFCC test, p. 127) and MRI can therefore be helpful in making the distinction (Miller & Schweitzer 2005). There are no studies examining the reliability of this test and considerable skill is required to interpret the findings meaningfully.

Clinical tip

An isolated injury to the lunotriquetral ligament does not usually produce a static diastasis between the lunate and triquetral so there may be dynamic and functional instability present but a normal plain X-ray reported.

EXPERT OPINION	COMMENTS
★★	<p>Lunotriquetral shear test</p> <p>It is important to establish what is normal excursion on the unaffected side as differences in range can be subtle.</p>

Related tests

Murphy's sign may also indicate the presence of lunate dislocation. The patient is asked to make a fist and the relationship between the heads of the 2nd, 3rd and 4th metacarpals is examined. Normally the head of the 3rd metacarpal extends more distally but where the lunate has dislocated, it remains in line with the heads of the other two metacarpals.

Capitate apprehension test

Aka

Capitate displacement test

Purpose

To determine the presence of capitate instability.

Technique

Patient position

The patient sits with the forearm supinated and supported on a table.

Clinician position

Facing the patient, one of the examiner's thumbs is placed over the palmar aspect of the capitate bone reinforced with the thumb of the other hand. The fingers of both hands are then wrapped around the dorsum of the patient's hand ensuring the wrist is supported in a neutral position and taking care with the handhold not to involve the patient's thumb.

Action

The examiner pushes the capitate posteriorly with both thumbs, ensuring the hand is stabilized by the fingers placed around the dorsum of the wrist.

Positive test

Pain and/or apprehension is reproduced as the posterior pressure is applied and this is sometimes accompanied by a click.



Fig. 4.6 • Capitate apprehension test.

Clinical context

Capitate subluxation is most commonly associated with instability at the scapholunate articulation (see scaphoid shift test, p. 119), usually resulting from a fall on an outstretched hand. Laxity or rupture of the scapholunate ligaments creates a static or dynamic diastasis that leaves the proximal capitate vulnerable to dorsal subluxation, either at the time of the injury or subsequently. In the presence of laxity, the capitate may sublux and reduce recurrently. When subluxed, the capitate can become more prominent and this is best observed on the dorsum of the hand with the wrist in a flexed position. Passive wrist extension will also be painfully blocked particularly when weight-bearing and localized pain can be elicited on full passive wrist flexion (Atkins et al 2010).

Clinical tip

The capitate is located at the base of the 3rd metacarpal and can more easily be palpated on the dorsum of the wrist. There is normally a palpable 'dip' over the capitate in the neutral position although this is lost if subluxation has occurred.

EXPERT OPINION	COMMENTS
★★	<p>Capitate apprehension test</p> <p>Only used when a generalized mid-carpal instability is suspected with a patient complaining of episodic subluxation and pain.</p>

Related tests

The *midcarpal pivot shift test* aims to identify instability as a result of traumatic attenuation of the scapholunate or lunotriquetral ligaments as midcarpal instability is often associated with concurrent injury to these articulations. The patient sits with the elbow at 90° with the supinated forearm supported on a table. The examiner stabilizes the distal forearm with one hand and, supporting the patient's hand in a neutral position with the other, takes the wrist from a fully radially deviated position (Fig. 4.7A) into full ulnar deviation (Fig. 4.7B). Instead of a normal smooth movement, it is irregular and accompanied by a painful clunk which indicates a positive finding. The clunk is thought to result from the sudden movement or shift of the capitate away from the lunate as a result of the ligamentous laxity.

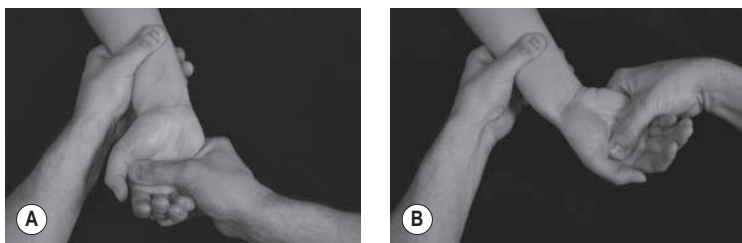


Fig. 4.7 • Midcarpal pivot shift. Start position (A). End position stressing the scapholunate and lunotriquetral articulations (B).

Lichtman's test is a variation of the midcarpal pivot shift test where axial compression is added to the movement. Pain and/or dorsal movement of the capitate are considered to be positive findings.

EXPERT OPINION	COMMENTS
★	<p>Lichtman's test</p> <p>This test can be hard to do well and interpret the findings accurately.</p>

B TRIANGULAR FIBROCARTILAGE COMPLEX (TFCC) TESTS

TFCC load test

Aka

Ulnar meniscal grind test

Purpose

To reproduce pain and/or apprehension indicating a tear or degeneration of the TFCC.

Technique

Patient position

Sitting or standing.

Clinician position

Facing the patient, the examiner stabilizes the patient's forearm with one hand and, as if shaking hands, places their other hand in the palm where it is held firmly.

Action

Axial compression is then applied through the patient's hand while ulnar deviation is added. This part of the manoeuvre has been described as the *ulnar impaction test*. This may be enough to reproduce localized pain at the base of the ulna negating the need for further loading. If asymptomatic, stress on the TFCC is increased by 'scooping' the hand from flexion to extension while maintaining the ulnar deviation and compression (see Fig. 4.8).

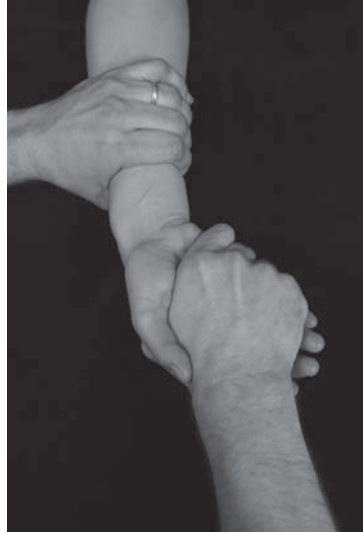Positive test

Localized pain at the ulnar side of the wrist joint is sometimes accompanied by apprehension and/or a click or crepitus on movement.

Clinical context

The TFCC, sometimes referred to as the ulnar articular disc, is a homogeneous structure comprising of the dorsal and palmar radioulnar ligaments, a meniscus, the ulnar collateral ligament and the sheath of the extensor carpi ulnaris (Palmer & Werner 1981). It acts as the primary soft tissue stabilizer of the distal radioulnar joint and takes 20% of the compressive load across the wrist. It is thickest (approx. 5mm) at its ulnar insertion but thinner (2mm) and more vulnerable to injury nearer to its radial origin which, unsurprisingly, is the most common site of TFCC tears (Miller & Schweitzer 2005). The central 80% of the TFCC is avascular and has little potential for repair although its

Fig. 4.8 • Triangular fibrocartilage complex (TFCC) test.



periphery and the dorsal and palmar ligaments are well vascularized, opening the possibility for healing in this zone (Bulstrode et al 2002).

Traumatic lesions (class one) usually involve a compressive force with rotation and/or ulnar deviation. The injury can be masked by associated fractures of the radius and/or ulna. Degenerative/over-use lesions (class two) are found increasingly over the age of 30 and in some cases may progress from simple TFCC 'wear' to accompanying lunotriquetral ligament disruption and ulnocarpal arthritis (Bulstrode et al 2002, Miller & Schweitzer 2005).

Clinical tip

Clinical features of TFCC lesions include wrist pain accentuated by movement, particularly pronation and ulnar deviation as well as loading of the clenched fist. These findings are usually accompanied by tenderness and crepitus over the TFCC area (Bulstrode et al 2002).

EXPERT OPINION	COMMENTS
★★★	<p>TFCC load test</p> <p>A very useful test but it can produce false positives and should therefore be taken in conjunction with all other findings.</p>

Related tests

The *supination lift test* requires the patient to sit facing an examination couch with the elbows flexed to 90° and the forearms fully supinated. The couch is positioned at a height that allows the palms of both hands to comfortably make contact with its under-surface. The patient is then asked to attempt to lift the couch up. Localized pain at the base of the ulnar and a reluctance to apply full force are both indicative of a TFCC tear.

C THUMB TESTS

Axial compression test

Aka

Axial grind test
Thumb grind test
Basal joint grind test

Purpose

To detect osteoarthritis (OA) of the trapeziofirstmetacarpal joint (basal joint of the thumb).

Technique

Patient position

The hand rests in a mid-pronated position on a table.

Clinician position and action

The compression test is performed by stabilizing the radial aspect of the wrist with one hand and gripping the first metacarpal shaft with the fingers and thumb of the other. An axial load is applied downwards along the shaft while the metacarpal is gently moved against the trapezium. This has been described as a 'grind' technique as the articular surfaces are moved together under compression (see Fig. 4.9).

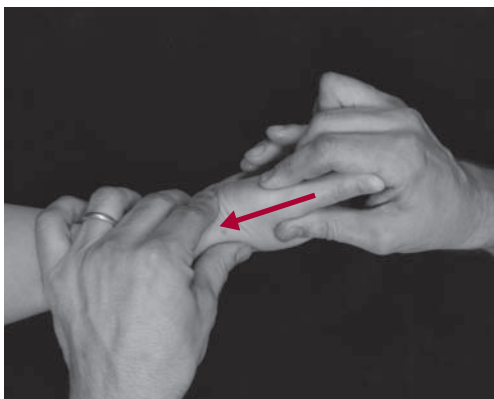
Positive test

A sudden, sharp pain is usually elicited as compression is applied. Occasionally crepitus may also be noted.

Clinical context

OA of the trapeziofirstmetacarpal joint is the most common site of degenerative joint disease in the hand (Brown & Neumann 2004, Ghavami & Oishi 2006, McRae 1990). The pain is localized around the base of the thumb and typically described as 'piercing'

Fig. 4.9 • Axial compression test of the trapezio-firstmetacarpal joint. The arrow indicates the direction of axial compression.



and exacerbated by twisting and gripping motions making functional tasks difficult. In the early stages, before changes become detectable on X-ray, the irritated joint capsule may begin to develop capsular restriction causing loss of extension (Atkins et al 2010). At this stage, in the absence of articular changes, the axial compression test is unlikely to be positive but as the condition worsens, laxity of the supporting ligaments and a reduction of bony constraints leads to increasing joint stress and progressive degenerative disease (see below). Once established, the sensitivity of the test increases but diagnosis is ultimately confirmed by radiology where any of the following may be evident: diminished joint space, subluxation, marginal osteophytes, joint sclerosis.

Trapeziofirstmetacarpal osteoarthritis staging

Stage I

Mild joint narrowing or subchondral sclerosis noted with small effusion. No laxity, subluxation or osteophyte formation.

Stage II

Possible osteophyte formation at the ulnar side of the distal trapezial articular surface. Mild to moderate subluxation might appear.

Stage III

Further joint space narrowing with cystic changes, bone sclerosis and prominent osteophytes. The first metacarpal is moderately subluxed radially and dorsally. Passive reduction might not be possible.

Stage IV

Scaphotrapezial joint also involved with evidence of destruction, with the trapeziofirstmetacarpal joint immobile and usually largely pain-free. (Eaton & Glickel 1987)

Clinical tip

Care needs to be taken when assessing this joint as axial loading can elicit severe twinges of pain, particularly when the condition presents acutely.

EXPERT OPINION	COMMENTS
★★★	<p>Axial compression test</p> <p>Used regularly as part of the routine clinical examination – especially if X-rays are not available to grade the stage of osteoarthritis.</p>

Finkelstein's test**Purpose**

To detect pain and limitation caused by inflammation between the tendons of abductor pollicis longus (APL) and extensor pollicis brevis (EPB) and their shared synovial sheath at the distal end of the radius (de Quervain's tenosynovitis).

Technique**Patient position**

With the forearm positioned in pronation, the patient is asked to flex the thumb and close their fingers over it.

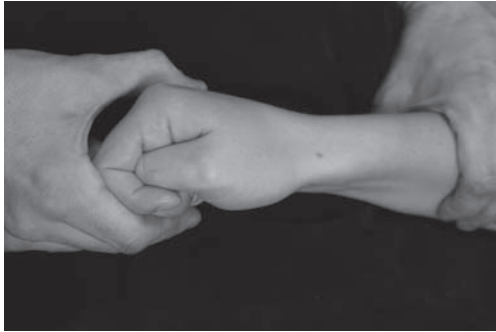Clinician position and action

The lower forearm is fixed with one hand and the patient's hand taken into ulnar deviation passively with the other.

Positive test

As the wrist is taken towards ulnar deviation, significant pain is reproduced over the radial aspect of the wrist.

Fig. 4.10 • Finkelstein's test.



Clinical context

De Quervain's tenosynovitis involves the two tendons in the first dorsal synovial compartment of the wrist. In the chronic stage where adhesions have developed and the sheath has become thickened, the condition is known as de Quervain's stenosing tenosynovitis (Atkins et al 2010, Placzek & Boyce 2006). The patient reports localized pain over the dorsum of the distal radius and this is often accompanied by swelling and crepitus on movement. Isometric resisted testing of the affected tendons is painful but repeated active thumb extension more so. The history is usually one of overuse or unaccustomed activity.

In a large study examining the incidence and demographic risk factors for de Quervain's tenosynovitis among military personnel, the incidence was reported to be considerably higher in the female population, with age also being a significant risk factor and prevalence increasing in the 40+ age group (Wolf et al 2009).

The relative excursions of the APL and EPB tendons in the first dorsal compartment during Finkelstein's testing have been examined in a cadaveric study which showed significantly greater excursion of EPB at both 30° and 60° of ulnar deviation compared to the APL tendon – suggesting that a positive Finkelstein's test may result more from EPB pathology than the APL (Kutsumi et al 2005). The two tendons usually share a common synovial sheath as they pass through the dorsal compartment however and the symptoms that result from overuse of either tendon are therefore indistinguishable.

Clinical tip

Even in the asymptomatic hand this test can be uncomfortable and care should be taken to ensure that the pain is not excessively provoked by an over-vigorous technique, particularly when acutely painful.

De Quervain's tenosynovitis should not be confused with intersection syndrome which involves the same two tendons as they cross over the wrist extensor muscles in the lower forearm about 5cm proximal from their sheathed extent (Atkins et al 2010) and, because of this, Finkelstein's test should not be significantly provocative.

EXPERT OPINION	COMMENTS
★★	<p>Finkelstein's test</p> <p>This can be approached with too much vigour. A subtle test if done well.</p>

Ulnar collateral ligament laxity test

Purpose

To detect pain and/or laxity of the ulnar collateral ligament (UCL) of the first metacarpophalangeal (MCP) joint.

Technique

Patient position

Seated with the hand supported on a table in a mid-pronated position.

Clinician position

The examiner stabilizes the distal end of the first metacarpal with the thumb and index finger. The same pincer grip is used with the other hand, placing the fingers over the radial and ulnar aspects of the proximal phalanx.

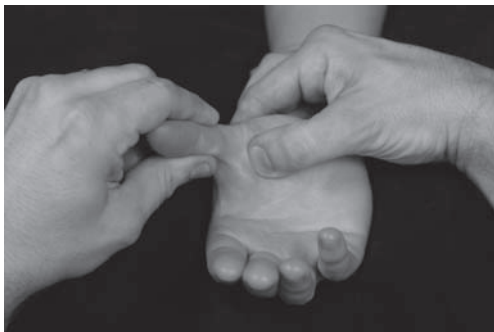Action

Fixing the metacarpal, a valgus stress is applied to the joint (which in this position involves the thumb being moved towards the patient).

Positive test

Pain and/or laxity reproduced at the base of the thumb.

Fig. 4.11 • Valgus stress on the ulnar collateral ligament of the first MCP joint.



Clinical context

Gamekeeper's thumb (Campbell 1955) is caused by a chronic insufficiency of the UCL at the first MCP joint leading to pain and weakness of the 'pinch grasp'. Injury to the UCL also presents acutely most commonly among the skiing population (skier's thumb), as a result of the ski-pole abruptly stopping in the snow during a fall and the static handle forcing a sudden valgus or abduction stress to the thumb (Davidson & Laliotis 1996, Van Dommelen & Zvirbulis 1989).

The UCL originates from the first metacarpal head and inserts into the medial aspect and base of the proximal phalanx of the thumb. When both the ulnar and accessory collateral ligaments are ruptured a Stener lesion may develop, where the aponeurosis of the adjacent adductor brevis muscle (which inserts into the extensor mechanism) becomes interposed between the ruptured ligament and the phalanx. The ligament retracts, no longer able to make contact with its insertion, and fails to heal (Stener 1962). As an important stabilizer of the thumb the loss of the UCL hampers function considerably and surgical repair is often necessary (Miller & Schweitzer 2005).

The same procedure can be repeated to test the radial collateral ligament by simply applying a varus stress although this ligament is much less commonly involved.

Clinical tip

With the joint in an extended position, valgus testing primarily determines the competence of the accessory collateral ligament which is taut in this position. Laxity of between 15° and 30° would

indicate rupture or partial rupture of the ligament and arouse suspicion of a gamekeeper's fracture where a portion of the proximal phalanx at the UCL insertion becomes avulsed. This is sometimes obvious on examination, with a palpable lump over the ulnar aspect of the MCP joint, but identifying this is not conclusive – the retracted stump of the UCL resulting from a Stener lesion may also be palpable (see clinical context above). A displaced fracture should be eliminated with X-ray before the clinician repeats the valgus test in 30° of flexion, as this position preferentially stresses the UCL and could disturb the fracture site. If the test in extension is normal, gross instability can be ruled out, but more pronounced laxity (30–40°) of the MCP joint in the flexed and extended positions make complete rupture of both ligaments likely (Heyman 1997).

If gamekeeper's fracture has been ruled out, an MRI or MR arthrography would be necessary to diagnose a Stener lesion (Harper et al 1996, Spaeth et al 1993).

EXPERT OPINION	COMMENTS
★★★	<p>Ulnar collateral ligament laxity test</p> <p>In acute injuries this test can determine whether surgical intervention is required. Most surgeons will have a point at which they will repair the ligament (usually around 30–40° of laxity). However, it is a matter of weighing up a number of factors: age, occupation, patient choice, time elapsed since trauma, anaesthetic risk, etc., as this may alter the threshold for surgical repair.</p>

D CARPAL TUNNEL TESTS

Phalen's test

Purpose

To increase pressure on the median nerve as it passes through the carpal tunnel in order to aid diagnosis of carpal tunnel syndrome (CTS).

Technique

Patient position

Seated with the hand resting on a table in mid-pronation.

Clinician position

Seated facing the patient. The affected hand is taken into full wrist flexion (Fig. 4.12A). Alternatively, the patient is asked to flex both wrists and oppose the dorsum of the hands so that the flexion is maintained bilaterally (Fig. 4.12B).

Action

In either position, the wrist flexion is maintained for a minute.

Positive test

Paraesthesiae is reproduced in the cutaneous distribution of the median nerve (the palmar aspect of the thumb, index and middle fingers and the lateral half of the ring finger) as a result of the sustained narrowing at the carpal tunnel during flexion of the wrist. If severe, pain may also be reproduced.

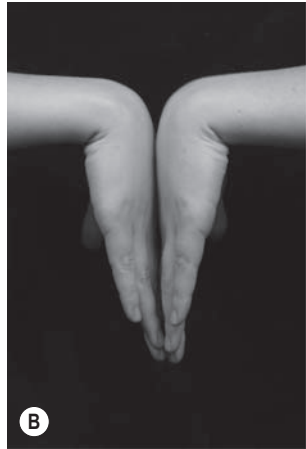

Fig. 4.12 • Phalen's test (A). Phalen's test – alternative position (B).

Clinical context

Studies of CTS have generated a great deal of controversy and no universally accepted diagnostic criteria exist (Placzek & Boyce 2006). Phalen's test was always widely considered to be the most

sensitive physical test but over recent years a number of studies have challenged this and attempted to demonstrate enhanced sensitivity with related or modified tests (Ahn 2001, Fertl et al 1998, Tetro et al 1998, Williams et al 1992). As with other tests for peripheral nerve dysfunction, no individual test can perfectly discriminate between the normal and abnormal and this is particularly so in the milder presentations (Rivner 1994). As a result there is a propensity for both false positive and false negative findings (Magee 2008) and this leads to wide variations in reported sensitivity and specificity (Gerr & Letz 1998, Malanga & Nadler 2006).

The absence of an agreed 'gold standard' of diagnosis requires the clinician to combine a number of clinical findings which can be used to predict the probability of CTS. The 'CTS 6' is a validated clinical diagnostic aid which assesses six factors (Graham 2008):

- 1 Numbness exclusively or predominantly in the median nerve distribution of the hand.
- 2 Nocturnal numbness.
- 3 Thenar atrophy or weakness (<grade 4 on examination).
- 4 Positive Phalen's test.
- 5 Loss of two-point discrimination (defined by failure to distinguish two points 5mm apart or less in the median nerve distribution of the hand).
- 6 Positive Tinel's test.

The presence of all these findings is considered to provide a strong indication for CTS. That is not to say that patients with less than the 'full house' do *not* have the condition but the fewer the indicators, the less certain the diagnosis becomes. For the majority of patients who are considered to have CTS on the basis of their history and physical examination alone, the addition of electrodiagnostic testing does not appear to improve the probability of diagnosing the condition to an extent that is clinically relevant (Graham 2008, Jordan et al 2002, Szabo et al 1999, Tetro et al 1998). Conversely, less than half of patients with electrodiagnostically confirmed CTS showed a positive result to Phalen's test (Malanga & Nadler 2006), further reinforcing the need to make a clinical diagnosis based on a number of findings.

Inflammation, and subsequent thickening of the flexor retinaculum and the soft tissues passing through this densely packed tunnel, has often been blamed for the symptoms associated with CTS. The co-morbidity of other conditions where inflammation is not

a particular feature has challenged this theory however, and both mechanical and vascular changes that cause swelling and compression are now thought to be responsible (Atkins et al 2010). CTS is often associated with tenosynovitis, diabetes, pregnancy and obesity, all of which have the capacity to potentially cause an increase in pressure in the carpal tunnel. Extrinsic factors, such as certain sports, vibration from heavy machinery and repetitive work, may also compromise the carpal tunnel and lead to symptoms.

TABLE 4.1 PHALEN'S TEST

Author and year	LR+	LR–	Target condition
Golding et al 1986	0.71	1.05	CTS
Gerr & Letz 1998	1.3	0.8	CTS
Williams et al 1992	88 ★★★	0.12 ★★	CTS
Tetro et al 1998	3.6 ★	0.5 ★	CTS

CTS = carpal tunnel syndrome

Clinical tip

Differential diagnosis of hand paraesthesiae/pain should include cervical myelopathy, radiculopathy, adverse neurodynamics involving the lower cervical nerve roots, thoracic outlet syndrome and ulnar nerve entrapment syndromes at the elbow and wrist.

Flattening of the thenar eminence muscles may be evident in more chronic cases with weakness of the abductor pollicis brevis muscle demonstrable on testing.

EXPERT OPINION	COMMENTS
★★★	<p>Phalen's test</p> <p>This is the preferential test for CTS but the clinician should always be aware of the potential of a more proximal source of symptoms requiring further examination of the cervical spine and brachial plexus.</p>

Additional tests

The *prayer test* (Fig. 4.13) can also be used to detect CTS. The affected hand is taken into full wrist extension (or together the palms of the hands are opposed and lowered until full extension at both wrists is achieved) and held there for a minute. Even though this is thought to increase the pressure within the carpal tunnel more than in the flexed position, the test is not thought to be as sensitive as Phalen's test (Malanga & Nadler 2006). A 'decompression phenomenon' is sometimes observed when pressure on the nerve trunk is removed, characterized by a rapid onset of paraesthesiae that can be temporarily uncomfortable for the patient.



Fig. 4.13 • Prayer test.

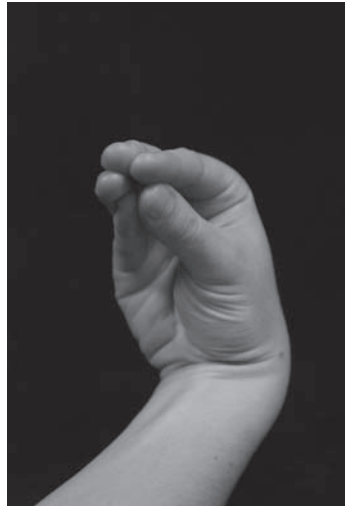The *tourniquet test* attempts to exacerbate median neuropathy in the carpal tunnel by inducing temporary ischaemia in the hand. A blood pressure cuff is inflated proximal to the elbow to approximately 180mmHg. The cuff pressure is maintained for up to 1 minute. If the patient reports numbness or tingling in the median distribution the test is considered to be positive. However, because this test relies on changes to the vascular supply at the carpal tunnel, symptoms that result predominantly from compression are unlikely to be provoked by this test and as a consequence a high rate of true negatives will be elicited. Equally, depriving the forearm and hand

of a normal blood supply may evoke tingling in the asymptomatic individual so false positive findings are also prevalent.

The *hand elevation test* has been proposed as a useful alternative in the diagnosis of CTS. The hand is simply elevated and sustained in this position for up to a minute. A positive test results in reproduction of the patient's symptoms. The authors proposing this test compared it favourably with Phalen's and Tinel's following their study on a symptomatic population (Ahn 2001) although these findings have not been corroborated independently and the test is not used widely.

The *three jaw chuck test* (Fig. 4.14) is an alternative method of compressing the carpal tunnel. This involves opposing the fingers with the thumb and then flexing the wrist maximally. Again symptoms should appear within 1 minute.

Fig. 4.14 • Three jaw chuck test.



Tinel's test

Aka

Median nerve percussion test

Purpose

To elicit paraesthesiae and/or pain in the median nerve distribution of the hand in order to aid diagnosis of carpal tunnel syndrome (CTS).

Technique***Patient position***

Seated with the hand resting on a table with the forearm fully supinated.

Clinician position

Sitting facing the patient, the affected hand is held in a neutral position.

Action

The mid-point of the carpal tunnel is identified and 'tapped' with a finger or a percussion hammer.



Fig. 4.15 • Tinel's test at the carpal tunnel.

Positive test

Temporary paraesthesiae or pain in the cutaneous distribution of the median nerve in the hand (palmar aspect of the thumb, index and middle fingers and the lateral half of the ring finger) is reported.

Clinical context

Tinel's test is used in other compressive neuropathies, although it is best known for the detection of CTS. Wide variations in both sensitivity and specificity of the test have been reported (Gerr & Letz 1998, Golding et al 1986, Heller et al 1986, Katz et al 1990, Williams et al 1992), leading to divergent recommendations, from abandoning physical tests altogether and referring symptomatic patients for neurophysiological examination (DeKrom et al 1990) to concluding that Tinel's and other physical tests have real prognostic and diagnostic value (Seror 1987). There are a number of possible reasons why results are so varied, including differences in patient selection, variability in testing procedure and variations in how the condition is defined. In addition, studies that use asymptomatic subjects as a control produce much higher rates of both sensitivity and specificity (Gerr & Letz 1998, Williams et al 1992) than studies where symptomatic patients – who were shown *not* to have CTS after electrodiagnosis – were used as the control.

Paraesthesiae in the hand is a common presentation that requires the clinician to consider all possible causes (see Phalen's test, p. 135) before a diagnosis of CTS is made. In the early stages of the condition when the symptoms are often more subtle, diagnostic hesitancy can lead to an over-reliance on electrodiagnostics which in themselves have been shown to be less than conclusive, particularly in the mild to moderate stages of the condition, leading to unacceptable levels of reported error (Lo et al 2002, Rivner 1994).

No physical test has been shown to be definitive although a combination of tests, including Tinel's, was shown to yield reasonable detection rates (Graham 2008, Katz et al 1990, Malanga & Nadler 2006). (See Phalen's test, p. 135, carpal compression test, p. 145.)

Clinical tip

Tinel's test can also be used to detect the extent of regeneration of the sensory fibres of the median nerve where the most distal point of abnormal sensation represents the distal extent of the regeneration.

TABLE 4.2 TINEL'S TEST

Author and year	LR+	LR–	Target condition
DeKrom et al 1990	0.6	1.3	CTS
Golding et al 1986	1.3	0.9	CTS
Gerr & Letz 1998	0.67	1.1	CTS
Tetro et al 1998	8.2 ★★	0.3 ★	CTS
Williams et al 1992	67 ★★★	0.3 ★	CTS

CTS = carpal tunnel syndrome

The clinician commences tapping at the tip of the palmar surface of the index finger and moves proximally towards the mid-point of the carpal tunnel and progresses in the midline towards the forearm, ascertaining from the patient when the sensation changes from abnormal to normal.

In the early stages of nerve compression, the clinician taps from the proximal to the distal extent of the median nerve in the carpal tunnel until pins and needles are reproduced. The most distal point that elicits the paraesthesiae is thought to signify the furthest point of nerve compression.

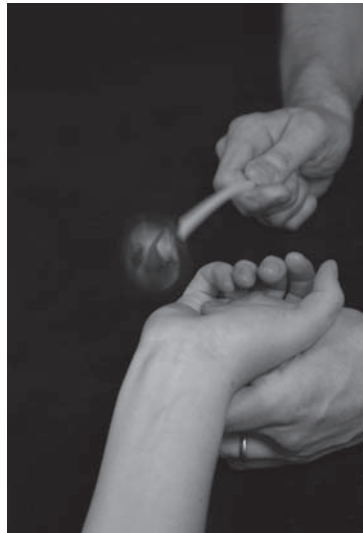EXPERT OPINION	COMMENTS
★★	<p>Tinel's test</p> <p>Used mainly to determine continued potential for nerve recovery post op/trauma rather than actual diagnosis of the condition.</p>

Related tests

Although less common, *ulnar tunnel syndrome* results from compression of the ulnar nerve as it passes through Guyon's canal (the

tunnel formed by the bridging of the pisohamate ligament – an extension of the flexor carpi ulnaris tendon – between the pisiform and hamate). It is usually caused by sustained compression (e.g. positioning the ulnar border of the hand on the handlebars when cycling with the wrist in extension and radial deviation) but can also result from ganglia, fracture or rheumatoid arthritis. Tinel's test can be repeated, tapping distally from the pisiform (Fig. 4.16). Both the motor and sensory divisions of the nerve may be affected but usually only one. If the sensory division is involved, decreased sensation over the palmar aspect of the fourth and fifth fingers may be evident, while weakness of the palmar interossei and medial two lumbricals would incriminate the motor division (Gross et al 2002). The most medial palmar interossei can be tested by sliding a piece of paper between the ring and little finger and asking the patient to hold this in place. Most commonly, ulnar tunnel syndrome is accompanied by tenderness over the tunnel.

Fig. 4.16 • Tinel's test at the ulnar tunnel.



Carpal compression test

Aka

Pressure provocative test
Manual carpal compression test
Durkan's compression test

Purpose

To increase pressure on the median nerve as it passes through the carpal tunnel in order to aid diagnosis of carpal tunnel syndrome (CTS).

Technique

Patient position

Seated with the forearm supinated with the hand rested on a table.

Clinician position and action

Sitting facing the patient, the examiner places one thumb, superimposed with the other, over the mid-point of the flexor retinaculum and presses firmly downwards for up to a minute while maintaining counterpressure with the fingers on the dorsum of the hand.



Fig. 4.17 • Carpal compression test.

Positive test

Paraesthesiae are reproduced in the cutaneous distribution of the median nerve (palmar aspect of the thumb, index and middle fingers and the lateral half of the ring finger) and if the condition is severe, pain may also be evoked.

Clinical context

The carpal compression test has been shown to be more sensitive than both Phalen's (see p. 135) and Tinel's (see p. 140) tests (Durkan 1994, Fertl et al 1998, González et al 1997, McRae 1990, Williams et al 1992) with symptoms often reproducible within several seconds, suggesting that it is a simple, fast and valuable provocative test for CTS (González et al 1997). In an attempt to standardize the amount of pressure required to consistently reproduce the symptoms, the use of an instrumented carpal compression device was tested and shown to deliver a similar degree of sensitivity and specificity in a controlled population of symptomatic patients (Durkan 1994). Although comparing favourably with other CTS tests, no technique can be regarded as diagnostic and a combination of findings should always be considered. The value of electrodiagnostic studies in the diagnosis of CTS has also been questioned (see Phalen's test, p. 135).

TABLE 4.3 CARPAL COMPRESSION TEST

Author and year	LR+	LR-	Target condition
Gonzalez et al 1997	7.9 ★★	0.15 ★★	CTS
Durkan 1994	22.3 ★★★	0.11 ★★	CTS
Tetro et al 1998	10.7 ★★★	0.27 ★	CTS
Williams et al 1992	33 ★★★	0.01 ★★★	CTS

CTS = carpal tunnel syndrome

Clinical tip

This test is also usefully employed where there is limited range of flexion or pain at the wrist which prevents an effective Phalen's test from being performed.

Accurate localization of the median nerve in the carpal tunnel is necessary for effective testing. The distal wrist crease is level with the proximal border of the flexor retinaculum so pressure needs to be distal to this line and centrally – over the crease that separates the thenar and hypothenar eminences (the crease can be enhanced by opposing the thumb and fifth finger).

Variations

The test can be further modified by either adding passive wrist extension (while asking the patient to grip) or passive wrist flexion (Fertl et al 1998, Tetro et al 1998). The latter has been found to have an optimal cut-off time of just 20 seconds and, again, has compared favourably in terms of sensitivity and specificity with both Phalen's and Tinel's tests.

TABLE 4.4 CARPAL COMPRESSION TEST WITH FLEXION/EXTENSION

Author and year	LR+	LR–	Target condition
Tetro et al 1998	82 ★★★	0.18 ★★	CTS

CTS = carpal tunnel syndrome

References

- Ahn, D.S., 2001. Hand elevation: a new test for carpal tunnel syndrome. *Ann. Plast. Surg.* 46 (2), 120–124.
- Atkins, E., Kerr, E., Goodlad, J., 2010. *A Practical Approach to Orthopaedic Medicine*, third ed. Churchill Livingstone, Edinburgh.
- Brown, D.E., Neumann, R.D., 2004. *Orthopaedic Secrets*, third ed. Hanley & Belfus, Philadelphia.
- Bulstrode, C., Buckwalter, J., Carr, A., et al., 2002. *Oxford Textbook of Orthopaedics and Trauma*. Oxford University Press, Oxford.
- Campbell, C.S., 1955. Gamekeeper's thumb. *J. Bone Joint Surg. Br.* 37 (1), 148–149.
- Davidson, T.M., Laliotis, A.T., 1996. Snowboarding injuries, a four-year study with comparison with alpine ski injuries. *West. J. Med.* 164 (3), 231–237.

- DeKrom, M.C., Knipschild, P.G., Kester, A.D., 1990. Efficacy of provocative tests for diagnosis of carpal tunnel syndrome. *Lancet* 335 (8686), 393–395.
- Durkan, J.A., 1994. The carpal-compression test: an instrumented device for diagnosing carpal tunnel syndrome. *Orthop. Rev.* 23 (6), 522–525.
- Eaton, R.G., Glickel, S.Z., 1987. Trapeziometacarpal osteoarthritis: staging as a rationale for treatment. *Hand Clin.* 3 (4), 455–471.
- Fertl, E., Wober, C., Zeitlhofer, J., 1998. The serial use of two provocative tests in the clinical diagnosis of carpal tunnel syndrome. *Acta Neurol. Scand.* 98 (5), 328–332.
- Gerr, F., Letz, R., 1998. The sensitivity and specificity of tests for carpal tunnel syndrome vary with the comparison subjects. *J. Hand Surg. Br.* 23 (2), 151–155.
- Ghavami, A., Oishi, S.N., 2006. Thumb trapeziometacarpal arthritis: treatment with ligament reconstruction tendon interposition arthroplasty. *Plast. Reconstr. Surg.* 117 (6), 116e–128e.
- Golding, D.N., Rose, D.M., Selvarajah, K., 1986. Clinical tests for carpal tunnel syndrome: an evaluation. *Br. J. Rheumatol.* 25 (4), 388–390.
- González del Pino, J., Delgado-Martínez, A.D., González González, I., et al., 1997. Value of the carpal compression test in the diagnosis of carpal tunnel syndrome. *J. Hand Surg. Br.* 22 (1), 38–41.
- Graham, B., 2008. The value added by electrodiagnostic testing in the diagnosis of carpal tunnel syndrome. *J. Bone Joint Surg. Am.* 90 (12), 2587–2593.
- Gross, J., Fetto, J., Rosen, E., 2002. *Musculoskeletal Examination*, second ed. Wiley-Blackwell, Chichester.
- Harper, M.T., Chandnani, V.P., Spaeth, J., et al., 1996. Gamekeeper thumb: diagnosis of ulnar collateral ligament injury using magnetic resonance imaging, magnetic resonance arthrography and stress radiography. *J. Magn. Reson. Imaging* 6 (2), 322–328.
- Heller, L., Ring, H., Costeff, H., et al., 1986. Evaluation of Tinel's and Phalen's signs in diagnosis of the carpal tunnel syndrome. *Eur. Neurol.* 25 (1), 40–42.
- Heyman, P., 1997. Injuries to the ulnar collateral ligament of the thumb metacarpophalangeal joint. *J. Am. Acad. Orthop. Surg.* 5 (4), 224–229.
- Jordan, R., Carter, T., Cummins, C., 2002. A systematic review of the utility of electrodiagnostic testing in carpal tunnel syndrome. *Br. J. Gen. Pract.* 52 (481), 670–673.
- Katz, J.N., Larson, M.G., Sabra, A., et al., 1990. The carpal tunnel syndrome: diagnostic utility of the history and physical examination findings. *Ann. Intern. Med.* 112 (5), 321–327.
- Kutsumi, K., Amadio, P.C., Zhao, C., et al., 2005. Finkelstein's test: a biomechanical analysis. *J. Hand Surg. Am.* 30 (1), 130–135.
- Lo, J.K., Finestone, H.M., Ibert, K., et al., 2002. Community-based referrals for electrodiagnostic studies in patients with possible carpal tunnel syndrome: what is the diagnosis? *Arch. Phys. Med. Rehabil.* 83 (5), 598–603.
- McRae, R., 1990. *Clinical Orthopaedic Examination*, third ed. Churchill Livingstone, London.
- Magee, D.J., 2008. *Orthopaedic Physical Assessment*, fifth ed. Saunders, Philadelphia.

- Malanga, G.A., Nadler, S., 2006. *Musculoskeletal Physical Examination: An Evidence-Based Approach*. Elsevier Health Sciences, Philadelphia.
- Miller, T.T., Schweitzer, M.E., 2005. *Diagnostic Musculoskeletal Imaging*. McGraw-Hill, New York.
- Palmer, A.K., Werner, F.W., 1981. The triangular fibrocartilage complex of the wrist – anatomy and function. *J. Hand Surg. Am.* 6 (2), 153–162.
- Placzek, J.D., Boyce, D.A., 2006. *Orthopaedic Physical Therapy Secrets*, second ed. Elsevier Health Sciences, Missouri.
- Rivner, M.H., 1994. Statistical errors and their effect on electrodiagnostic medicine. *Muscle Nerve* 17 (7), 811–814.
- Seror, P., 1987. Tinel's sign in the diagnosis of carpal tunnel syndrome. *J. Hand Surg. Br.* 12 (3), 364–365.
- Spaeth, H.J., Abrams, R.A., Bock, G.W., et al., 1993. Gamekeeper thumb: differentiation of nondisplaced and displaced tears of the ulnar collateral ligament with MR imaging: work in progress. *Radiology* 188 (2), 553–556.
- Stener, B., 1962. Displacement of the ruptured ulnar collateral ligament of the metacarpo-phalangeal joint of the thumb. *J. Bone Joint Surg. Br.* 44, 869–879.
- Szabo, R.M., Slater, R.R., Farver, T.B., et al., 1999. The value of diagnostic testing in carpal tunnel syndrome. *J. Hand Surg. Am.* 24 (4), 704–714.
- Tetro, A.M., Evanoff, B.A., Hollstien, S.B., et al., 1998. A new provocative test for carpal tunnel syndrome: assessment of wrist flexion and nerve compression. *J. Bone Joint Surg. Br.* 80 (3), 493–498.
- Van Dommelen, B.A., Zvirbulis, R.A., 1989. Upper extremity injuries in snow skiers. *Am. J. Sports Med.* 17 (6), 751–753.
- Weiss, S., Finkelstein, N., 2005. *Hand Rehabilitation – A Quick Reference Guide and Review*, second ed. Elsevier Mosby, St Louis.
- Williams, T.M., Mackinnon, S.E., Novak, C.B., et al., 1992. Verification of the pressure provocative test in carpal tunnel syndrome. *Ann. Plast. Surg.* 29 (1), 8–11.
- Wolf, J.M., Sturdivant, R.X., Owens, B.D., 2009. Incidence of de Quervain's tenosynovitis in a young, active population. *J. Hand Surg. Am.* 34 (1), 112–115.

This page intentionally left blank

HIP

A ARTICULAR TESTS 152

FAIR test	152
McCarthy test	156
FABER test	160
Torque test	163
Active straight leg raise (SLR) test	165

B MUSCLE AND TENDON TESTS 166

Thomas's test	166
Modified Ober's test	170
Trendelenburg test	172

C OTHER TESTS 175

Craig's test	175
Sign of the buttock	177

A ARTICULAR TESTS

FAIR test

Aka

Impingement test
Posterior labral tear test
Apprehension sign
Piriformis test
Psoas test

Purpose

To reproduce pain and/or apprehension and increase the likelihood of detecting a range of conditions such as articular pathology (e.g. femoro-acetabular impingement (FAI), labral and hip joint pathology and instability), piriformis syndrome and psoas bursitis.

Technique

Patient position

Lying supine.

Clinician position

Standing on the affected side.

Action

The hip and knee are taken into 90° of flexion and then full internal rotation is added by applying a stabilizing pressure on the outside at the knee with the cephalic hand and drawing the lower leg outwards by using the heel as a lever with the caudal hand. The final component is adduction, achieved by passively moving the knee towards the opposite hip.

Positive test

Reproduction of the patient's pain can be considered to be a positive test although the site of this will vary depending on the pathology.

- *Articular pathology/psoas bursitis*: pain in the groin which may be accompanied by a click if the labrum is involved.
- *Piriformis syndrome*: buttock or radicular pain.

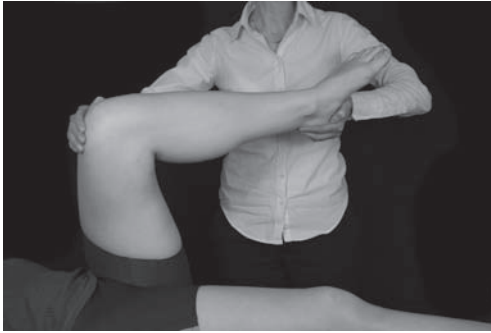

Fig. 5.1 • Flexion, adduction and internal rotation (FAIR) test.

Clinical context

The FAIR test gets its name from the acronym generated by the principal elements of this test (Flexion, Adduction and Internal Rotation). The list of possible structures that can be incriminated by a positive FAIR test naturally results in a test with low specificity. There is some evidence, however, that demonstrates its sensitivity in the diagnosis of labral pathology/impingement and piriformis syndrome (Burnett et al 2006, Fishman et al 2002, Fitzgerald 1995, Hase & Ueo 1999, Jaberi & Parvizi 2007, Lewis & Sahrman 2006, Mitchell et al 2003, Narvani et al 2003).

Most of the research comprises of small case series or larger retrospective studies of patients with known acetabular pathology or femoro-acetabular impingement (FAI). While the precise prevalence and cause of labral pathology is unknown, the population most likely to present is the younger patient with groin or hip pain (see McCarthy test, p. 156; McCarthy & Busconi 1995, Narvani et al 2003). A typical presentation would be a female patient in her mid-thirties with groin pain which is provoked by flexion activities such as driving or squatting and where certain movements are accompanied by a click. Some patients may also report lumbar or buttock pain provoked by activity, impact or load-bearing. There is a general lack of consensus concerning the significance of other findings such as a history of trauma, congenital or developmental hip abnormalities, movement impairment and radiological changes (Burnett et al 2006, Fitzgerald 1995, Hase & Ueo 1999, Jaberi & Parvizi 2007, Lewis & Sahrman 2006, Mitchell et al 2003, Narvani et al 2003).

Impingement, scour/quadrant (see Variations) and FABER tests (see p. 160) are all additional tests used to help the clinician determine the necessity of further investigation such as magnetic resonance arthrography (MRA) and arthroscopy.

The absence of an agreed 'gold standard' diagnostic tool for labral injury introduces uncertainty when attempting to measure the sensitivity of the test, as the significance of a positive finding on examination cannot always be confirmed definitively by means other than surgery, with investigations such as MRI and MRA being of limited value (Standaert et al 2008). In a retrospective study of 66 patients, the FAIR test was positive in 95% of patients with an arthroscopically confirmed labral tear compared to only 79% detected by MRA (Burnett et al 2006). These findings were confirmed in two separate case series (Hase & Ueo 1999, Ito et al 2004). The lack of false negatives in these current studies prevents specificity being calculated. Although the FAIR test is part of the suggested examination for FAI there are several variations (see p. 155).

The use of the test for piriformis syndrome has been evaluated in a large cohort trial of 918 patients which found that a positive FAIR test was a valid predictor of the response to physiotherapy, injection or surgical treatment for this condition (Fishman et al 2002). A study of 15 cases of surgically proven piriformis/sciatic nerve compression following blunt trauma concluded that the combination of a positive FAIR test along with a history of trauma, buttock pain and/or radicular pain, intolerance to sitting and tenderness over the sciatic notch were highly indicative of piriformis adhesions and should guide the need for referral for EMG (Benson & Schutzer 1999).

TABLE 5.1 FAIR TEST

Author and year	LR+	LR-	Target condition
Fishman et al 2002	5.2 ★★	0.14 ★★	Piriformis syndrome

Clinical tip

Placing the hip in flexion, adduction and internal rotation will cause either compression or stretch of many hip structures including the ischiofemoral ligament of the hip, iliopsoas tendon and bursa, pectineus, adductor longus, sartorius, tensor fascia lata, piriformis and the glutei. Inevitably the hip joint itself is tested and the findings

may help to isolate the first signs of joint pathology, such as Perthes' disease in children for example (Woods & Macnicol 2001). The FAIR test is not capable of distinguishing between specific structures or pathology and the clinician is reliant on other information gleaned from the patient including the history, other physical findings and the results of pertinent investigations.

EXPERT OPINION	COMMENTS
★★	FAIR test Useful as a non-specific test for a range of hip pathology. A diagnosis of femoro-acetabular impingement is likely if the patient's symptoms are typical, the test is positive and they have a 'C' sign (when asked to indicate the area of pain, they grasp the area of the greater trochanter with their thumb and index finger).

Variations

The *scour/quadrant/flexion adduction test* is a modification where the hip is passively flexed to 90° and adducted. The clinician's hands

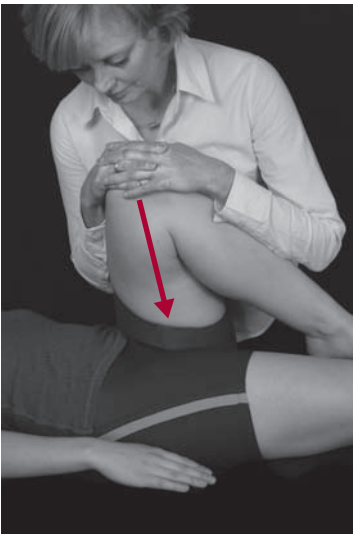

Fig. 5.2 • Scour test. The arrow indicates the direction of axial compression.

are interlocked and placed over the patient's flexed knee. Leaning over the knee so that the examiner's body weight can be used to good effect, a compressive force is applied through the longitudinal axis of the femur. Small passive movements are made into flexion and extension in order to 'scour' the joint (Fig. 5.2). A positive test is indicated by reproduction of the patient's symptoms.

TABLE 5.2 SCOUR TEST

Author and year	LR+	LR–	Target condition
Narvani et al 2003	1.32	0.58	Labral tears

McCarthy test

Purpose

To reproduce pain and/or a 'click' in order to detect an acetabular labral tear.

Technique

Patient position

Lying supine with the hips and knees flexed and both feet resting on the couch.

Clinician position

The affected hip is taken into full passive flexion, with one hand supporting the flexed knee and the other supporting the foot (see Fig. 5.3).

Action

External rotation is then added as the affected hip is gradually taken down towards extension (see Fig. 5.4). If this does not elicit a positive response, the manoeuvre is repeated with the addition of internal rotation instead.

Positive test

Reproduction of the patient's hip pain or click.

Clinical context

The role of the labrum in the symptomatic hip and the diagnosis of femoro-acetabular impingement (FAI) are comparatively new



Fig. 5.3 • McCarthy test. Start position.



Fig. 5.4 • McCarthy test. End position in external rotation. The test can then be repeated moving the hip into internal rotation.

areas of study and the evidence concerning the clinical diagnosis and the most appropriate investigations and treatment is uncertain. The labrum does have a propensity to degenerate with age and this was demonstrated in a cadaver study where degenerative

tears were identified in 90% of specimens (McCarthy et al 2003). Interestingly, it is not the ageing population that report labral problems as the accompanying joint disease inevitably takes precedence. The younger patient with groin or hip pain is most likely to present and 22–55% of patients with this profile were found to have labral tears (Narvani et al 2003). A typical presentation would be a female patient in her mid-thirties with groin pain which is provoked by flexion activities such as driving or squatting and where certain movements are accompanied by a click. Some patients may also report lumbar or buttock pain provoked by activity, impact or load-bearing.

Apart from surgical confirmation, there is no agreed 'gold standard' diagnostic tool, with neither MR arthrography nor MRI showing sufficient sensitivity or specificity to confirm FAI (Standaert et al 2008). The detection of FAI, labral tears or chondral lesions at the hip therefore largely relies on a combination of the history, signs and symptoms, the outcome of physical tests and imaging studies to guide both diagnosis and management. There has been shown to be some correlation, however, between acetabular tears and pre-operative reports of clicking and giving way (McCarthy & Busconi 1995, Narvani et al 2003).

Clinical tip

Acetabular tears may present in young, athletic patients where the predominant symptoms are groin pain, often accompanied by clicking, a catching sensation and/or giving way. A traumatic history involving hip flexion, abduction and knee extension is common (DeAngelis & Busconi 2003), although not essential, as a significant proportion of patients in one study reported an insidious onset (Burnett et al 2006).

EXPERT OPINION	COMMENTS
★★	<p>McCarthy test</p> <p>Useful as a non-specific test for hip joint pathology. A positive test is not sensitive or specific for labral lesions. However, patients who report reproduction of their click and pain on this test seem to get better outcomes post surgery.</p>

Variations

The *snapping hip test* (sometimes known as the *clicking hip test* or the *extension test*) is an active version of the *McCarthy test* and used to distinguish extra-articular snapping of the iliopsoas tendon as it passes over the femoral head or the iliopectineal eminence anteriorly. Iliopsoas syndrome is a source of groin pain and clicking and is most commonly encountered in young, athletic patients. It may also be associated with inflammatory or degenerative arthritis in the hip, or present post hip arthroplasty. The patient lies supine and actively brings the affected hip into a flexed, adducted and internally rotated position. The clinician places one hand over the anterior aspect of the hip joint to palpate for snapping. The other hand is then free to guide the movement of the patient's leg downwards. The patient actively extends, abducts and externally rotates the hip from the starting position. A positive test is indicated by pain and reproduction of the patient's familiar snapping sensation (Magee 2008). Alternative causes of extra-articular snapping are the tensor fascia lata/gluteus maximus slipping over the greater trochanter and the iliofemoral ligament movement over the anterior joint capsule.

Related tests

Other labral tests have attempted to identify the location of the tear (Fitzgerald 1995). For the *posterior labral tear test* (Fig. 5.5) the hip

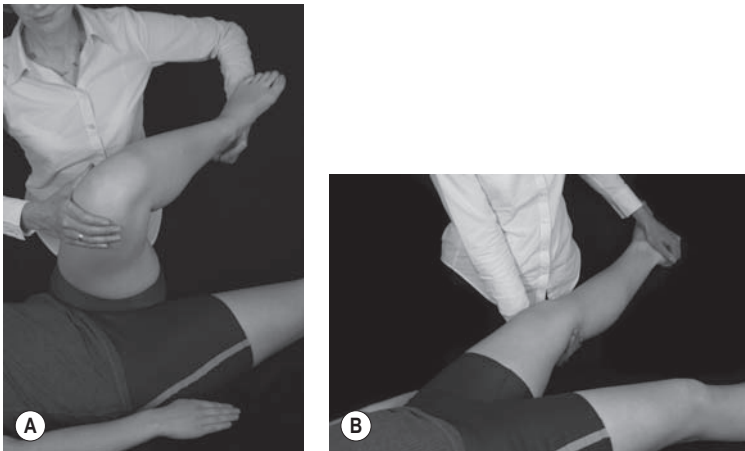


Fig. 5.5 • Start (A) and end position (B) of the posterior labral tear test.

is taken into in a flexed, adducted and internally rotated position (Fig. 5.5A) and then passively moved into the reverse pattern of extension, abduction and external rotation (Fig. 5.5B). The opposite manoeuvre is used for the *anterior labral tear test*. The hip starts in full flexion, external rotation and abduction and is then moved passively into extension, internal rotation and adduction. Pain and/or clicking reproduced with either of these manoeuvres would be suggestive of a labral tear. Fitzgerald's (1995) study prospectively examined patients with surgically verified labral pathology and although 54 of 55 patients reported a positive finding (pain and/or a click) on one of these tests, it was not possible to specifically isolate the exact site of the lesion.

EXPERT OPINION	COMMENTS
★	<p>Posterior labral tear test</p> <p>The posterior labral tear test can be adapted so that the hip is taken into extension over the edge of the couch.</p>

The *log roll test* can also be used to detect pathology of the acetabular labrum or identify hip joint laxity. The patient lies supine with the lower limbs relaxed in a neutral position. Standing on the affected side, the hands are positioned over the anterior aspect of the patient's thigh, just above the knee. The thigh is then passively rolled into full internal rotation and then full external rotation. The test may elicit a click in the presence of a labral tear. An increase in the range of movement of the affected hip can indicate laxity (Austin et al 2008; see torque test, p. 163).

EXPERT OPINION	COMMENTS
★★	<p>Log roll test</p> <p>The log roll test can be useful as a general assessment for hip pathology. As the patient lies supine, excess external rotation caused by hip instability/laxity is indicated by the foot of the affected leg rolling outwards.</p>

FABER test

Aka

The '4' test
Patrick's test
Jansen's test

Purpose

To test primarily for articular pathology in the hip joint. Also stresses the sacro-iliac joint (SIJ), iliopsoas tendon and the lumbar spine.

Technique

Patient position

The patient lies supine and the affected leg is flexed and externally rotated so that the lateral aspect of the ankle is positioned just above the opposite knee joint. If this starting position is uncomfortable for the patient, the knee can be brought more into the midline to reduce hip abduction.

Clinician position

Standing at the patient's affected side, the pelvis is stabilized by applying gentle pressure over the opposite anterior superior iliac spine.

Action

The patient is asked to lower the knee towards the couch and if full range is achieved, gentle overpressure can be applied to the medial aspect of the knee to assess full passive range and end-feel.

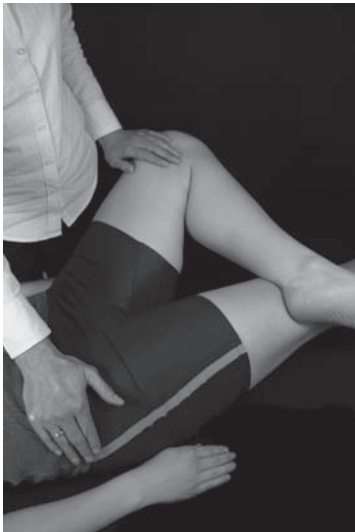

Fig. 5.6 • Flexion, abduction and external rotation (FABER) test.

Positive test

A positive test is indicated by the reproduction of the patient's pain or reduced range of movement. If the knee lowers to a point which is level to the opposite knee or the range is equivalent to the contralateral side, range is considered to be normal.

Clinical context

The test position places the hip in Flexion, ABduction and External Rotation, giving the acronym FABER. Interpretation of the test can be difficult as the position adopted not only tensions the hip joint capsule and neighbouring iliopsoas tendon but also the anterior sacroiliac ligaments (Atkins et al 2010).

The FABER test was evaluated in a study examining the correlation between clinical examination, imaging investigations and arthroscopy in a prospective study of 25 patients with hip pain. A range of hip joint pathologies was found including labral lesions, chondromalacia, loose bodies, synovitis and acetabular rim lesions. Of the 17 patients who recorded a positive FABER test pre-operatively, 15 were found to have hip pathology, although there was no correlation between a positive test and a specific lesion, rendering the test 88% sensitive. In contrast, magnetic resonance arthrography was 100% specific in 13 patients but lower levels of sensitivity were reported because of failure in some cases to identify pathology later verified by arthroscopy. The findings on clinical examination, including positive FABER (see p. 160) and FAIR tests (see p. 152), should alert the clinician to the possibility of hip pathology (particularly involving the labrum) and provide the basis for further investigations (Mitchell et al 2003).

Clinical tip

Groin pain and limitation of movement without the addition of overpressure is more likely to highlight a hip lesion, whereas unilateral lumbar/buttock pain reproduced with overpressure may be more attributable to a SIJ problem (Atkins et al 2010). In addition to the site of pain, the patient's age, history and other clinical findings will also help in the differential diagnosis but this is not universally the case and the possibility of co-existent dysfunction in both the hip and SIJ may need to be considered.

EXPERT OPINION	COMMENTS
★★	FABER test Useful as a non-specific test for assessing hip pathology.

Torque test

Purpose

To test the capsular ligaments and passive stability of the hip joint.

Technique

Patient position

Lying supine to one side of the treatment couch with the buttock just off the edge.

Clinician position and action

The clinician stands between the couch and the patient's affected leg with the cephalic hand placed over the anterior aspect of the thigh. The caudal hand supports the lower limb at the ankle. With the knee extended, the hip is taken to end-range extension over the edge of the couch until the pelvis just starts to rotate anteriorly. The hip is then taken to end-range internal rotation using the ankle to supply the leverage while simultaneously applying a strong posterolateral pressure over the anterior aspect of the upper thigh for 20 seconds.

Positive test

Reproduction of the patient's pain suggests hip instability.

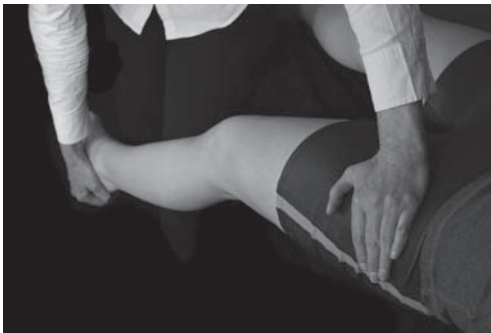

Fig. 5.7 • Torque test.

Clinical context

Hip instability is much less commonly encountered than instability at the shoulder largely because of the congruence of the pelvic and femoral architecture, although if this stable arrangement is altered due to congenital dysplasia, hip arthroplasty or capsular laxity (occurring as a result of connective tissue disorders such as Ehlers–Danlos syndrome), instability may ensue.

Significant trauma with the hip in a flexed position (typically a car collision where the knee impacts with the dashboard) is most likely to cause posterior instability and usually does so in combination with a fracture or dislocation. With this history a diagnosis of instability should be considered (Byrd 2005). However, more subtle degrees of anterior instability have recently been reported in patients following comparatively minor trauma such as a fall onto a flexed hip or a sudden movement into abduction or external rotation. Damage to the ligamentum teres has been hypothesized as a possible cause for this instability (Bardakos & Villar 2009). Symptoms and clinical signs are very similar to those reported in FAI i.e. groin pain related to activity, possibly accompanied by clicking, locking or giving way, positive impingement tests on examination (see McCarthy test, p. 156; FABER test, p. 160; FAIR test, p. 152; active SLR test, p. 165) and further radiological investigations are required to aid the differential diagnosis process (Bardakos & Villar 2009).

Clinical tip

The torque test can be modified to stress individual components of the capsular ligaments more specifically (Lee 2004) by taking the hip into extension and full external rotation and adding abduction to focus stress on the *iliofemoral ligament* and adduction to test the *pubofemoral ligament* with the femoral distraction added in an identical manner. The *ischiofemoral ligament* is tested by the FAIR test (see p. 152).

EXPERT OPINION	COMMENTS
★	<p>Torque test</p> <p>Hip instability can also be assessed using the log roll test. The torque test is also helpful to assess for psoas tightness and pain.</p>

Active straight leg raise (SLR) test

Aka

Stinchfield resisted hip flexion test

Mens test

Purpose

To test for intra-articular hip pain (e.g. OA, labral tear, femoro-acetabular impingement), fracture, pain stemming from a hip prosthesis and contractile lesions of the hip flexors.

Technique

Patient position

Lying supine.

Clinician position

Standing on the affected side.

Action

Keeping the knee extended, the patient performs a straight leg raise (SLR) to approximately 20–30°. The clinician then steadily resists the SLR by applying pressure to the lower aspect of the anterior thigh.

Positive test

Reproduction of the patient's hip pain, which is usually in the groin or anterior aspect of the thigh.

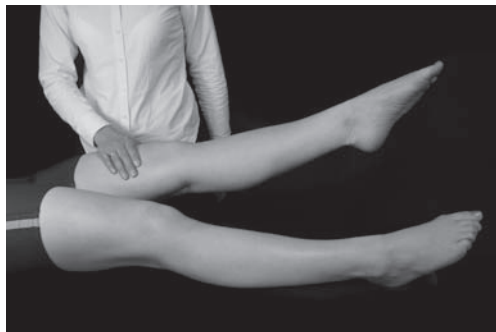

Fig. 5.8 • Active straight leg raise (SLR).

Clinical context

Active lifting of a straight leg approximately 15cm from the bed while in the supine position generates a reaction force through the hip of $1.8 \times$ body weight and can be used to indicate intra-articular

hip pathology. Adding a resistance to the leg will increase the force and make the test more sensitive for hip joint pathology but potentially less specific (Callaghan et al 2007) as this will increase the stress on adjacent structures, namely the hip flexors (rectus femoris, sartorius and iliopsoas), the lumbar spine and sacro-iliac joint.

EXPERT OPINION	COMMENTS
★★	<p>Active SLR test</p> <p>Groin pain on this test suggests hip pathology, with reproduction of buttock and/or low back pain more suggestive of a lumbar or SI problem. The Ling test (see below), is a useful variation to discriminate between hip and spinal pathology.</p>

Clinical tip

The active SLR is also used as a validated test to measure effective load transfer between the trunk and lower limbs (Lee 2004). Rather than assessing for pain, the effort required by the patient to maintain good pelvic stabilization throughout the test is noted. Excessive effort, loss of global and local muscle stabilization or compensatory movement of the pelvis into flexion, extension, rotation or lateral flexion during the test, indicates poor muscle control around the pelvis and spine.

Variations

The *Ling test* is an adaptation of the SLR test. Active SLR to approximately 20° is performed on the affected leg and the patient is asked about the effect on their pain. The clinician then supports the patients heel and resists active hip extension. Pain which diminishes with resisted extension incriminates the hip, whilst unchanged symptoms should cast suspicion towards the spine.

B MUSCLE AND TENDON TESTS

Thomas's test

Aka

Hugh Owen Thomas (HOT) test
Thompson test
Rectus femoris contracture test

Purpose

To test for a fixed flexion deformity at the hip and assess muscle length of the rectus femoris, iliacus, tensor fascia lata (TFL) and the iliotibial band (ITB).

Technique

Patient position

Lying supine.

Clinician position

Firstly, the clinician checks that the patient is able to maintain their normal lumbar lordosis with the legs comfortably resting on the couch. In patients with soft tissue tightness or flexion contracture, the affected hip(s) will be held in a degree of flexion (this may also present as an increased lumbar lordosis). One hand is then placed under the patient's lumbar spine in order to assess the degree of lumbar movement during the test.

Action

The patient flexes the unaffected hip and knee towards the chest until the lumbar spine is flattened as assessed by the clinician's hand. The patient then grasps the knee with both hands and maintains the hip in this position. Attention is then turned to the affected leg where the position of the thigh in relation to the couch is determined.

Positive test

In a normal hip, the affected thigh is able to remain extended, resting on the couch. In the presence of soft tissue tightness or a fixed flexion deformity, the affected hip will be drawn into a degree of flexion bringing the thigh away from the couch. If the clinician attempts to

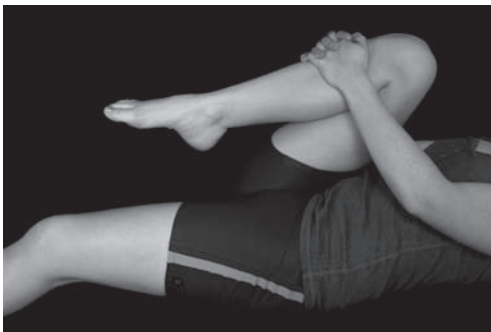

Fig. 5.9 • Thomas's test.

passively extend the hip by pushing the thigh in a downwards direction, the patient will report a stretching sensation over the anterior hip and thigh and an attempt to increase their lumbar lordosis will be noted. If the hip gravitates more towards abduction than flexion during the test (the J sign), shortening of the ITB is likely (Magee 2008, Placzek & Boyce 2006).

Clinical context

A fixed flexion deformity may occur for several reasons. Soft tissue shortening in the hip flexors can occur as a consequence of spasticity, pain or a habitually flexed posture and bony changes secondary to osteoarthritis or fracture may cause a physical block to hip extension. The test may appear positive if there is a fixed lumbar lordosis or significant posterior pelvic tilt which can give the illusion of a fixed hip flexion deformity.

Clinical tip

To differentiate between soft tissue tightness and joint restriction:

- passively explore the end of available joint range and assess the end-feel as this can help to detect minor but significant differences
- when testing muscle length, palpation for tightness within the muscle may help to distinguish between muscle contracture and tightness in the joint itself. If the muscle being tested feels comparatively relaxed, the joint is more likely to be involved
- muscle energy techniques (e.g. hold/relax) can be used at the end of available range, with increasing extension indicating tightness of the hip flexors.

EXPERT OPINION	COMMENTS
★★★	Thomas's test Used on most patients to assess for a fixed flexion deformity.

Variations

The *modified Thomas's test* (Fig. 5.10) allows more effective analysis of the length of individual muscles (Lee 2004). The patient 'perches' on the edge of the treatment couch at one end. The clinician stands adjacent to the affected side. The patient then flexes the opposite knee and hip towards the chest and slowly rolls backward

onto the couch as the clinician supports the patient's head. Once lying, the affected thigh is allowed to hang off the end of the couch. Gentle overpressure can be applied to the anterior thigh to further assess the range of available hip extension (see Fig. 5.10). Rectus femoris length is measured by recording the angle of knee flexion with the hip in a neutral position (the normal angle of knee flexion in this position is around 80°). TFL/ITB length is assessed in the same position but considered tight if the hip drifts into some abduction as it is extended (see Ober's test, p. 171). Further evaluation of the ITB length can be achieved by observing the extent of tibial rotation at the knee, as the test position will have the tendency to pull the tibia into external rotation and consequently limit passive internal rotation if the ITB is tight.

A contracture of the rectus femoris can also be detected with *Ely's test*. The patient lies prone and the knee is passively flexed to approximately 90° . If there is shortening or contracture of the muscle, the hip on the same side will endeavour to flex as flexion is added at the knee.

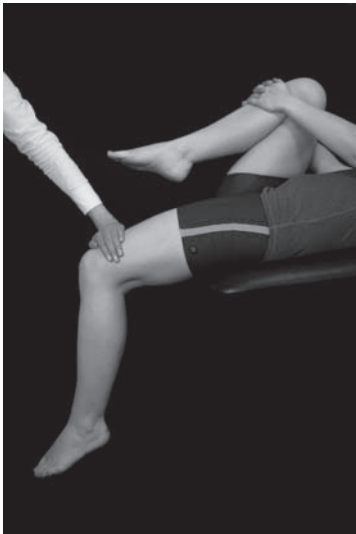

Fig. 5.10 • Modified Thomas's test assessing the range of hip extension.

Modified Ober's test

Purpose

To assess ITB and tensor fascia lata (TFL) extensibility.

Technique

Patient position

Lying on the unaffected side with the hip and knee flexed to provide a stable base. The affected hip is uppermost and in a neutral position.

Clinician position

Standing behind the patient, the caudal hand crosses over the top of the uppermost leg and cups the medial aspect of the thigh just above the knee. The cephalic forearm stabilizes the pelvis by applying a firm downward and forward pressure onto the iliac crest. The affected hip is then drawn into an extended and abducted starting position ensuring that neutral femoral rotation is maintained.

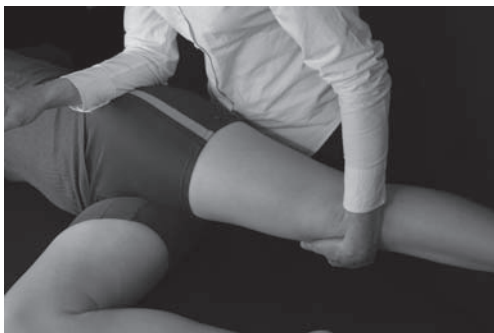Action

The pelvis must be prevented from tilting backwards by maintaining the downward and forwards pressure with the stabilizing arm. Maintaining the affected hip in extension the thigh is lowered towards an adducted position. The end-point of the test is either cessation of hip adduction as the leg reaches a resting position on the couch or the clinician detecting movement of the pelvis.

Positive test

A positive test is either reproduction of the patient's lateral hip pain or reduced range of movement. The normal range of hip adduction

Fig. 5.11 • Modified Ober's test.



in the modified Ober's test position is 10° beyond neutral and an inability to reach this range is therefore considered abnormal.

Clinical context

The effects on the ITB of both the modified and original Ober's tests (see below) have been evaluated using ultrasound imaging in healthy subjects. Both tests were shown to cause a reduction of the ITB width as the adduction stretch was gradually increased until a neutral adduction angle was reached. Beyond the neutral position, only the modified Ober's test resulted in a further reduction in the ITB width (Wang et al 2006). Because the *modified Ober's test* allows a greater range of adduction to be achieved and more effectively tensions the ITB, it is the preferred test for many clinicians (Gajdosik et al 2003, Reese & Bandy 2003).

Clinical tip

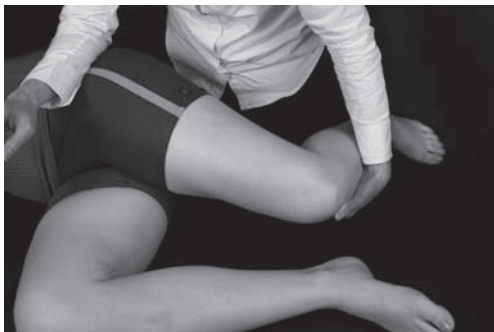To make sure that the ITB passes over the greater trochanter during the test, the clinician must ensure that the hip stays in the extended position throughout the manoeuvre.

EXPERT OPINION	COMMENTS
★★	<p>Modified Ober's test</p> <p>Useful in assessing lateral hip pain. If positive, along with tenderness over the greater trochanter, a diagnosis of trochanteric bursitis/tendinopathy is likely.</p>

Variations

The original *Ober's test* (Fig. 5.12; Ober 1936) was described for use with patients suffering from low back pain and sciatica. The position of both clinician and patient is as described above. The affected knee is then flexed to 90° and the hip lowered into the adducted position. A reduced range (normal range 0° adduction) is anticipated when compared with the modified Ober's test (see Fig 5.11). It has been suggested that the original test selectively stresses the TFL more than the ITB, while the modified version reverses this tendency. Ober's test can also be limited by contracture of the rectus femoris muscle and this can be evaluated further with Thomas's test (see p. 166). The position of hip extension and knee flexion adopted in the modified Ober's test also tensions the femoral nerve and provocation of back pain or thigh pain/paraesthesiae during the test would guide the clinician to investigate the lumbar spine and neural tissue.

Fig. 5.12 • Original Ober's test.



Trendelenburg test

Purpose

To test for stability of the pelvic/hip complex and strength of the hip abductors.

Technique

Patient position

Standing.

Clinician position

Standing facing the patient in order to observe the outcome of the test and provide some support to the patient with the hands if required.

Action

The patient is asked to transfer their weight onto the affected leg and lift the unaffected foot off the ground by flexing both the hip and knee. The clinician observes the movement as the weight is transferred onto the symptomatic side.

Positive test

A positive/abnormal test is recorded if the pelvis on the non-weight-bearing side drops because the gluteal muscles on the weight-bearing side cannot maintain the pelvis in a neutral position. Normally the glutei will produce a slight uplift of the pelvis on the non-weight-bearing side as weight is borne on the opposite leg. In a study of normal volunteers the change in position of the pelvis on the femur was measured at a barely detectable 4° and, that being the case, normal abductor performance could be assumed (Youdas et al 2007).



Fig. 5.13 • Trendelenburg test on a normal subject where the pelvis position is maintained as weight is borne through the supporting leg.

Clinical context

There are several variations of the original test described by Trendelenburg in 1897 (Hardcastle & Nade 1985). In an attempt to standardize the method and interpretation of the Trendelenburg test, normal subjects were compared to a group of symptomatic subjects with disorders of the hip or spine. Several factors were identified which commonly led to incorrect interpretation of the test, namely faulty technique because of poor understanding, use of the trunk muscles rather than the glutei to elevate the pelvis, shift of the trunk and body weight over the weight-bearing leg and using pain rather than weakness to distinguish a positive test (Hardcastle & Nade 1985). This study led to a modified version (see Variations).

A positive test is not diagnostic of a specific pathology and, as with most tests, needs to be evaluated in the light of other presenting signs and symptoms. It has, however, been shown to be a useful predictor of gluteal tendon pathology or weakness in patients with lateral hip pain. In a sample of 24 female patients with lateral hip pain, the presence of both a positive Trendelenburg test and an accompanying Trendelenburg gait was found to be a better predictor of a gluteus medius tear than

pain found on either resisted hip abduction or internal rotation and served as a reasonable determinant for MRI referral (Bird et al 2001).

In another small study where MRI was used as the reference standard to diagnose gluteal tendinopathy, patients were asked to adopt a modified Trendelenburg test position for 30 seconds. Provocation of pain (rather than weakness) in this position was found to be very sensitive and specific in detecting the presence of gluteal tendinopathy and/or bursitis (Lequesne et al 2008).

TABLE 5.3 TRENDELENBURG TEST

Author and year	LR+	LR–	Target condition
Bird et al 2001	3.2 ★	0.35 ★	Gluteal tendon tear (weakness)
Lequesne et al 2008	37 ★★★	0 ★★★	Gluteal tendinopathy +/- bursitis (pain)

Clinical tip

A trick movement (side-flexion towards the weight-bearing side) may be performed by the patient with gluteal weakness who is unable to achieve a normal response to Trendelenburg testing.

EXPERT OPINION	COMMENTS
★★★	Trendelenburg test Used with most patients. Most accurate if one-legged stance is maintained for 30 seconds.

Variations

The *Hardcastle and Nade method* (Hardcastle & Nade 1985) has the clinician standing behind the patient. If some support is required to allow the patient to balance, this should be provided on the weight-bearing side. The patient is asked to stand on the affected leg and lift the other foot off the floor. They then attempt to raise the pelvis on the unaffected side while the clinician observes the movement and transference of weight. A negative test (i.e. normal response) is found if the pelvis on the non-weight-bearing side can be raised and held for 30 seconds while the patient maintains a

straight, neutral position with the head aligned over the supporting hip and foot (Fig. 5.14A). A positive test (i.e. abnormal) is indicated by either the pelvis on the non-weight-bearing side dropping or an inability to raise the pelvis and maintain this position for 30 seconds, the so called 'delayed Trendelenburg response' (Fig. 5.14B).

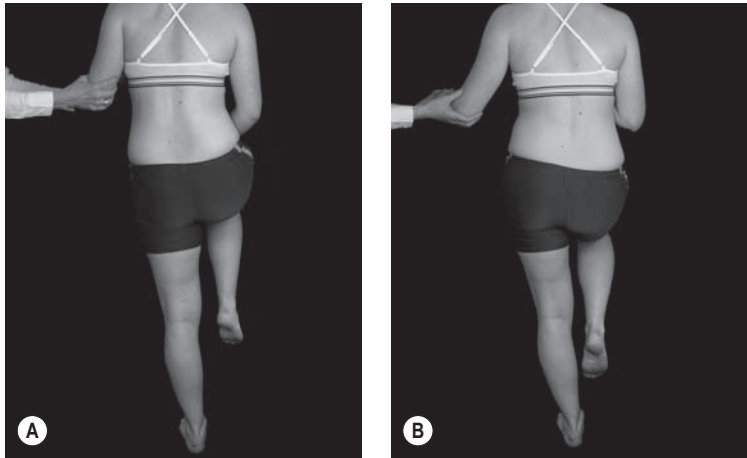


Fig. 5.14 • Hardcastle and Nade method. A normal subject maintaining a raised position of the pelvis on the non-weight-bearing leg (A). A positive test is indicated if the patient is unable to achieve or maintain the raised position (B).

C OTHER TESTS

Craig's test

Aka

Ryder method for measuring femoral anteversion

Purpose

To ascertain the degree of femoral anteversion.

Technique

Patient position

Lying prone with the thighs and knees approximated and the affected knee flexed to 90°.

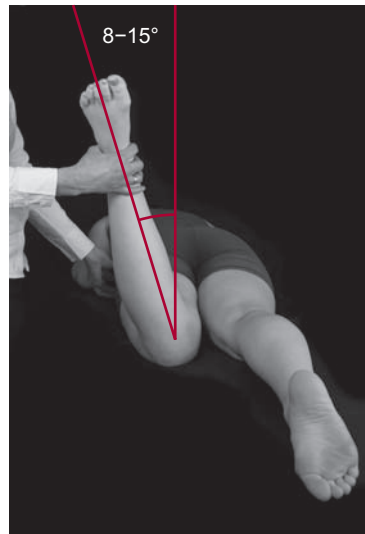Clinician position and action

Using one hand, the lateral aspect of the greater trochanter on the affected side is palpated. The other hand uses the patient's foot as a lever and passively internally rotates the hip until the greater trochanter reaches its most prominent point laterally. The angle that the line of the tibia makes with the vertical equates to the degree of femoral anteversion.

Positive test

The normal angle of femoral anteversion in the adult is between 8° and 15° . An angle greater than 15° indicates increased femoral anteversion; less than 8° indicates femoral retroversion.

Fig. 5.15 • The normal degree of femoral anteversion ($8\text{--}15^{\circ}$) is indicated by the angle formed between the vertical axis and the line of the tibia.



Clinical context

The femoral neck normally projects anteriorly from the shaft of the femur. This degree of anteversion (which simply means 'leaning forward') is measured by the angle formed between the axis of the neck of femur and an imaginary line through the femoral condyles at the knee.

It is suggested that the degree of femoral and acetabular rotation is determined by intrauterine foetal position during pregnancy.

In 85% of cases the acetabular and femoral positions normalize after birth and the degree of anteversion gradually decreases from 30–40° in childhood to approximately 15° with skeletal maturity. There is also a gender variation, with an average angle of 14° in women compared to 7° in men (Magee 2008).

An increased angle of anteversion is accompanied by excessive internal rotation (<60° is abnormal) and reduced external rotation of the hip, a presentation often epitomized by bilateral 'squinting' patellae. Osteoarthritis of the knee or patellofemoral instability are both secondary problems that can also develop as a result. Decreased femoral anteversion can be found as a result of a slipped upper femoral epiphysis, coxa vara, a deep acetabulum or congenital dysplasia and there is increasing evidence to suggest that this retroversion also predisposes to hip osteoarthritis (Giori & Trousdale 2003, Kim et al 2006, Tonnis & Heinecke 1999) and femoro-acetabular impingement (Giori & Trousdale 2003).

EXPERT OPINION	COMMENTS
★★	<p>Craig's test</p> <p>An easily performed test to assess anteversion in children and adults.</p>

Sign of the buttock

Purpose

To test for a serious lesion in the buttock or hip region, e.g. fracture, neoplasm or infection.

Technique

Patient position

Lying supine.

Clinician position and action

Standing adjacent to the side being tested the clinician performs a straight leg raise (SLR) on the affected leg and the angle achieved is noted (see Fig. 5.16A). At the point where increased pain is reported by the patient, the tension in the posterior thigh, buttock and sciatic nerve is removed by flexing the knee while maintaining the hip at the same angle (see Fig. 5.16B). Further hip flexion is then

attempted. Under normal circumstances, it should then be possible to move the hip into further flexion.

Positive test

Once the knee is flexed, further hip flexion would be expected but in fact none is possible as this increases the patient's buttock pain. This may be accompanied by voluntary muscle spasm and the patient stopping further movement taking place (Atkins et al 2010).

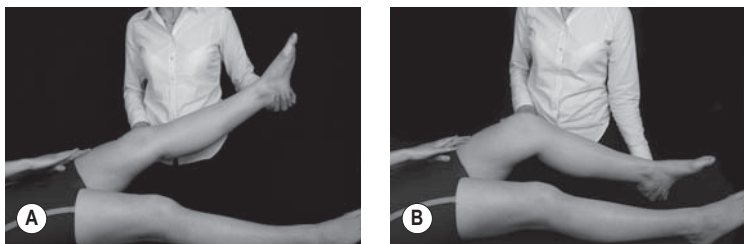


Fig. 5.16 • In a positive sign of the buttock, the degree of hip flexion achievable with a straight leg raise (A), remains unchanged when the knee is flexed (B).

Clinical context

The sign of the buttock is an unusual finding and, if genuinely detected, indicates the presence of a serious injury or disease process such as fracture or neoplasm around the upper femur and pelvis, osteomyelitis, septic arthritis of the hip, ischiorectal abscess or septic bursitis.

In addition to the sign of the buttock, lumbar flexion will also be limited and reproduce the patient's buttock pain. The degree of flexion achieved will be equal to the angle of flexion permitted with SLR and hip flexion testing. This is an important detail as there are many pathologies that can present simultaneously causing different degrees of limitation and pain but none that produce an *identical* loss of flexion (Atkins et al 2010). Pain on a number of resisted tests around the hip may also be evident as well as a subjective history of 'red flags' such as unremitting pain, fever, weight loss or significant night pain.

Clinical tip

The patient will register some apprehension to the examination, particularly in relation to the key elements of this test, and will instinctively withdraw from the movement, often before the pain is elicited. The anticipation of severe pain causes them to stop the movement either with their hand or verbally, at which point the examiner may

detect an 'empty' end-feel – characterized by a sense that more range is obtainable but unavailable due to the patient being unwilling to allow further excursion. The movement may also be limited by a combination of voluntary and involuntary muscle spasm which would further prevent movement if attempted.

References

- Atkins, E., Kerr, E., Goodlad, J., 2010. *A Practical Approach to Orthopaedic Medicine*, third ed. Churchill Livingstone, Edinburgh.
- Austin, A., Souza, R., Meyer, J., et al., 2008. Identification of abnormal hip motion associated with acetabular labral pathology. *J. Orthop. Sport. Phys. Ther.* 38 (9), 558–565.
- Bardakos, N.V., Villar, R.N., 2009. The ligamentum teres of the adult hip. *J. Bone Joint Surg. Br.* 91 (1), 8–15.
- Benson, E.R., Schutzer, S.F., 1999. Posttraumatic piriformis syndrome: diagnosis and results of operative treatment. *J. Bone Joint Surg.* 81 (7), 941–949.
- Bird, P.A., Oakley, S.P., Shnier, R., et al., 2001. Prospective evaluation of magnetic resonance imaging and physical examination findings in patients with greater trochanteric pain syndrome. *Arthritis Rheum.* 44 (9), 2138–2145.
- Burnett, R.S., Della Rocca, G., Prather, H., et al., 2006. Clinical presentation of patients with tears of the acetabular labrum. *J. Bone Joint Surg. Am.* 88, 1448–1457.
- Byrd, J.W., 2005. Hip arthroscopy in athletes. *Oper. Techn. Sport. Med.* 13, 24–36.
- Callaghan, J., Rosenberg, A., Rubash, H., 2007. *The Adult Hip*, second ed. Lippincott Williams and Wilkins, Philadelphia.
- DeAngelis, N.A., Busconi, B.D., 2003. Assessment and differential diagnosis of the painful hip. *Clin. Orthop. Relat. Res.* 406, 11–18.
- Fishman, L.M., Dombi, G.W., Michaelsen, C., et al., 2002. Piriformis syndrome: diagnosis, treatment, and outcome – a 10-year study. *Arch. Phys. Med. Rehab.* 83 (3), 295–301.
- Fitzgerald, R.H., 1995. Acetabular labrum tears diagnosis and treatment. *Clin. Orthop. Relat. Res.* 311, 60–68.
- Gajdosik, R.L., Sandler, M.M., Marr, H.L., 2003. Influence of knee positions and gender on the Ober test for length of the iliotibial band. *Clin. Biomech.* 18 (1), 77–79.
- Giori, N.J., Trousdale, R.T., 2003. Acetabular retroversion is associated with osteoarthritis of the hip. *Clin. Orthop. Relat. Res.* 417, 263–269.
- Hardcastle, P., Nade, S., 1985. The significance of the Trendelenburg test. *J. Bone Joint Surg. Br.* 67 (5), 741–745.
- Hase, T., Ueo, T., 1999. Acetabular labral tear: arthroscopic diagnosis and treatment. *Arthroscopy: J. Arthroscopic Relat. Surg.* 15 (2), 138–141.
- Ito, K., Leunig, M., Ganz, R., 2004. Histopathologic features of the acetabular labrum in femoroacetabular impingement. *Clin. Orthop. Relat. Res.* 429 (12), 262–271.

- Jaberi, F., Parvizi, J., 2007. Hip pain in young adults femoroacetabular impingement. *J. Arthroplasty* 22 (7/Suppl. 3), 37–42.
- Kim, W.Y., Hutchinson, C.E., Andrew, J.G., 2006. The relationship between acetabular retroversion and osteoarthritis of the hip. *J. Bone Joint Surg. Br.* 88 (6), 727–729.
- Lee, D., 2004. *The Pelvic Girdle: An Approach to the Examination and Treatment of the Lumbopelvic-hip Region*, third ed. Churchill Livingstone, Edinburgh.
- Lequesne, M., Mathieu, P., Vuillemin-Bodaghi, V., et al., 2008. Gluteal tendinopathy in refractory greater trochanter pain syndrome: diagnostic value of two clinical tests. *Arthritis Rheum.* 59 (2), 241–246.
- Lewis, C.L., Sahrman, S.A., 2006. Acetabular labral tears. *Phys. Ther.* 86 (1), 110–121.
- McCarthy, J.C., Busconi, B., 1995. The role of hip arthroscopy in the diagnosis and treatment of hip disease. *Can. J. Surg.* 38 (1), 13–17.
- McCarthy, J., Noble, P., Aluisio, F.V., et al., 2003. Anatomy, pathologic features, and treatment of acetabular labral tears. *Clin. Orthop. Relat. Res.* 406, 38–47.
- Magee, D.J., 2008. *Orthopaedic Physical Assessment*, fifth ed. Saunders, Philadelphia.
- Mitchell, B., McCrory, P., Brukner, P., et al., 2003. Hip joint pathology: clinical presentation and correlation between magnetic resonance arthrography, ultrasound and arthroscopic findings in 25 consecutive cases. *Clin. J. Sport Med.* 13 (3), 152–156.
- Narvani, A.A., Tsiridis, E., Kendall, S., et al., 2003. A preliminary report on prevalence of acetabular labrum tears in sports patients with groin pain. *Knee Surg. Sports Traumatol. Arthrosc.* 11 (6), 403–408.
- Ober, F., 1936. The role of the iliotibial band and fascia lata as a factor in the causation of low back disabilities and sciatica. *J. Bone Joint Surg. Am.* 18, 105–110.
- Placzek, J.D., Boyce, D.A., 2006. *Orthopaedic Physical Therapy Secrets*, second ed. Elsevier Health Sciences, Missouri.
- Reese, N., Bandy, W., 2003. Use of an inclinometer to measure flexibility of the iliotibial band using the Ober test and the modified Ober test: differences in magnitude and reliability of measurements. *J. Orthop. Sports Phys. Ther.* 33 (6), 326–330.
- Standaert, C.J., Manner, P.A., Herring, S.A., 2008. Expert opinion and controversies in musculoskeletal and sports medicine: femoroacetabular impingement. *Arch. Phys. Med. Rehabil.* 89, 890–893.
- Tonnis, D., Heinecke, A., 1999. Acetabular and femoral anteversion: relationship with osteoarthritis of the hip. *J. Bone Joint Surg. Am.* 81 (12), 1747–1770.
- Wang, T.G., Jan, M.H., Lin, K.H., et al., 2006. Assessment of stretching of the iliotibial tract with Ober and modified Ober's tests: an ultrasonographic study. *Arch. Phys. Med. Rehabil.* 87 (10), 1407–1411.
- Woods, D., Macnicol, M., 2001. The flexion–adduction test: an early sign of hip disease. *J. Pediatr. Orthop.* 10 (3), 180–185.
- Youdas, J.W., Mraz, S.T., Norstad, B.J., et al., 2007. Determining meaningful changes in pelvic-on-femoral position during the Trendelenburg test. *J. Sport Rehabil.* 16 (4), 326–335.

KNEE

A ONE-PLANE TESTS 183

Valgus test	183
Varus test	186
Posterior drawer test	188
Anterior drawer test	191
Lachman's test	194

B MULTI-PLANE TESTS 198

● **Anteromedial rotatory instability (AMRI) 198**

Slocum (AMRI) test	198
---------------------------	------------

● **Anterolateral rotatory instability (ALRI) 199**

Slocum (ALRI) test	199
---------------------------	------------

Pivot shift test	201
-------------------------	------------

● **Posteromedial rotatory instability (PMRI) 204**

Posteromedial drawer test	204
----------------------------------	------------

● **Posterolateral rotatory instability (PLRI) 205**

Posterolateral drawer test	205
Reverse pivot shift test	207
Dial test	209
External rotation recurvatum test	211

C MENISCAL TESTS **212**

Apley's test	212
McMurray's test	215
Weight-bearing/rotation meniscal test	218

D PATELLOFEMORAL TESTS **221**

McConnell test	221
Patella apprehension test	224
Patellofemoral grind test	225

E OTHER TESTS **227**

Noble's compression test	227
Mediopatellar plica test	229

A ONE-PLANE TESTS

Valgus test

Aka

Abduction stress test

Purpose

To primarily detect pain and/or laxity of the medial collateral ligament (MCL).

Technique

Patient position

Lying supine with the leg relaxed.

Clinician position

Standing on the outside of the affected leg; the patient's lower leg is lifted and supported between the waist and the inside of the clinician's elbow with the knee flexed to about 20–30° and the hip positioned in a degree of internal rotation and abduction. The heel of the outside hand is placed just above the lateral joint line, the inside hand is placed just below the medial joint line where the thumb can palpate the medial tibiofemoral joint line.

Action

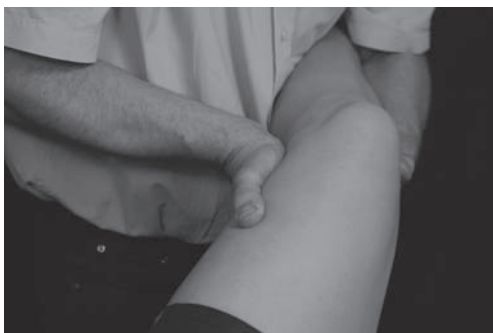Firm inward pressure is applied with the outside hand and outward pressure with the inside hand while rotating the body away from the end of the couch to achieve a valgus stress to the knee. The test can then be repeated with the knee in full extension.

Positive test

The reproduction of medial knee pain alone is suggestive of injury to the MCL. An intact ligament produces a normal ligamentous end-feel where firm resistance to the valgus stress is noted. Loss of this normal resistance and an increase in valgus movement (in excess of 15°) suggests structural damage to the MCL indicative of a more significant injury involving other structures.

In full extension stability to the joint is afforded by the cruciate ligaments and laxity in this position is likely to represent major disruption to the knee and concurrent injury to the posterior capsule, posterior cruciate ligament (PCL) and possibly the anterior cruciate ligament (ACL) should be suspected (Malanga et al 2003, Slocum & Larson 1968).

Fig. 6.1 • Valgus test.



Clinical context

The MCL is the most commonly injured knee ligament and the valgus stress test is the primary tool for assessing the integrity of its deep and superficial fibres. In addition the posteromedial capsule, posterior oblique ligament, PCL and ACL will also be subject to stress during this manoeuvre.

In the acute injury, full physical assessment may not be possible because of pain, apprehension and swelling, so diagnosis may depend on assessment of the force and mechanism of injury, the degree of pain, the rapidity of swelling (immediate, significant swelling suggesting haemarthrosis) and the degree of disability.

Assessment of the subacute or chronic lesion allows the MCL injury to be graded (Bulstrode et al 2002, Kesson & Atkins 2005):

Grade	Findings
Minor/ grade I	Pain, tenderness and diffuse swelling with medial joint gapping of less than 5 mm on valgus testing with maintenance of the normal joint end-feel and a minimal suction sign (drawing in the skin over the medial joint line) signifies some MCL microfailure but no instability
Moderate/ grade II	Pain, tenderness and local swelling with medial joint gapping of 5–10 mm on valgus testing with maintenance of the normal joint end-feel and a marked suction sign caused by moderate to major MCL tear. Minor ligamentous laxity does not usually result in serious functional instability unless the demands on the knee are high

Grade	Findings
Severe/ grade III	Severe pain at the time of injury, significant swelling and possible haemarthrosis. Gapping of greater than 10 mm, with loss of the definite ligamentous end-feel, indicating a complete MCL rupture

Imaging with stress X-rays and/or MRI may help grade the injury more specifically and determine the presence of concurrent damage to other structures.

Although valgus stress is the most frequently used test in assessing injury to the MCL, the absence of an appropriate reference standard against which to measure the accuracy of mild injury or rupture has resulted in little evidence to support its use. Only one study reported a sensitivity of 86% for MCL tears using arthroscopy as a reference standard (Malanga et al 2003).

Clinical tip

Ensuring that the hip is internally rotated prevents extraneous movement of the leg during testing and allows the application of selective stress on the structures responsible for stabilizing the medial aspect of the knee. A positive test in slight knee flexion incriminates the MCL and/or posterior capsule, as this position takes tension off the ACL which provides a secondary restraint to valgus in full extension. When repeated in full extension, a positive test suggests damage not only to the MCL and posterior capsule but also to one or both cruciate ligaments.

Tibial rotation has an opposite effect on the collateral and cruciate ligaments. In *external* rotation the MCL/lateral collateral ligament are more taut and the ACL/PCL more lax and in *internal* rotation the opposite is true. The degree of MCL stress during this test can therefore be increased by adding external rotation of the tibia.

EXPERT OPINION	COMMENTS
★★★	Valgus test Used in every patient as a screening test for medial knee stability and pain.

Varus test

Aka

Hughston's varus stress test
Adduction stress test

Purpose

To primarily detect pain and/or laxity of the lateral collateral ligament (LCL).

Technique

Patient position

Lying supine towards the edge of the couch.

Clinician position

Standing on the affected side, the leg is lifted off the couch and the hip is passively abducted far enough to allow the clinician to stand in the space between the inside of the leg and the side of the couch. The patient's lower leg is supported between the waist and the outer elbow and the hip is positioned in some degree of internal rotation. The heel of the outside hand is placed on the upper tibia just below the lateral joint line and the inside hand is placed just above the medial joint line on the lower femur.

Action

With the knee in about 20° of flexion and the hip internally rotated, firm pressure is applied with both hands to achieve a varus stress while rotating the body in order to increase leverage.

Positive test

Lateral knee pain or laxity on stress testing.

Clinical context

Lateral or posterolateral knee injuries are relatively uncommon as the mechanism of injury usually requires an external impact (e.g. being hit by a car or a rugby tackle) to force the knee into an extreme varus position. In contrast to the MCL, the ligament is quite independent of the lateral capsule and meniscus which makes the structure less vulnerable to injury. The normal degree of varus is variable (usually around 7°) and should be compared to the normal knee if laxity is suspected. Stress X-ray showing a lateral opening of more than 8mm is suggestive of a grade III injury (see ligament injury table, p. 184) and the likelihood of injury to the other posterolateral

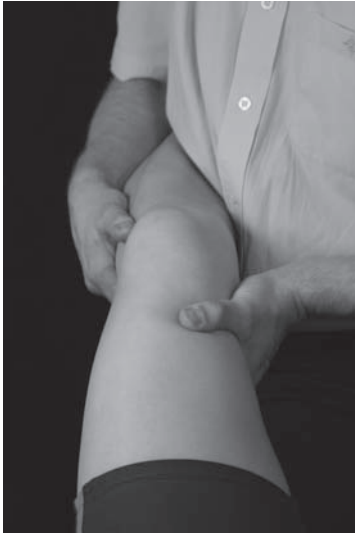

Fig. 6.2 • Varus test.

structures (cruciate ligaments, posterolateral capsule, arcuate–popliteus complex, iliotibial band) increases with the degree of abnormal varus movement detected (LaPrade & Terry 1997, Larsen & Toth 2005). Lateral instability, though much less common, is potentially more disabling than medial instability.

Varus stress tests the integrity of the LCL ligament. Although laxity noted on this test may indicate one-plane lateral instability, it is more likely to be positive where there has been injury to the other structures that contribute to posterolateral stability (Malanga et al 2003). If this is suspected, the posterolateral drawer test (see p. 205), dial test (see p. 209) or external recurvatum test (see p. 211) are considered to be more accurate in detecting posterolateral rotational instability (PLRI; Baker et al 1983). Conversely, a negative varus test does not rule out PLRI as an intact PCL contributes to varus stability in full extension and may limit varus excursion. In one large study, the LCL was found to be involved in only 23% of PLRI injuries (LaPrade & Terry 1997).

There is little evidence on the accuracy of any of the tests for the lateral structures of the knee primarily due to the absence of an appropriate reference standard. The clinical findings for lateral and

posterolateral injuries of the knee are often subtle and, as a result, are more frequently misinterpreted (Hughston et al 1976).

Clinical tip

To maximize stress on the LCL, the tibia needs to be positioned in slight flexion and as much external rotation as possible as this reduces stress on the cruciates and leaves the iliotibial band lying centrally over the lateral joint line.

The test can be repeated with the knee in full extension and if instability is still detected, major disruption of the knee has occurred and injury to either the cruciates, popliteus or other lateral structures should be suspected along with injury to the LCL (Larsen & Toth 2005, Malanga et al 2003).

EXPERT OPINION	COMMENTS
★★★	<p>Varus test</p> <p>Used in every patient as a screening test for lateral knee instability.</p>

Posterior drawer test

Purpose

To detect posterior (one-plane) instability and posterior cruciate ligament (PCL) laxity.

Technique

Patient position

Supine with the hip flexed to 45°, the knee flexed to 90° and the foot placed on the couch.

Clinician position

The lower leg is stabilized by sitting on the dorsum of the fore-foot. Both hands grasp around the upper tibia with thumbs placed anteriorly over the joint line with the thenar area of both hands positioned over the upper tibia. The fingers can also palpate the hamstring tendons posteriorly to ensure they are relaxed.

Action

The tibia is pushed backwards with both hands. The quality of the joint end-feel should be appreciated and a ligamentous 'stop' noted if the ligament remains intact.

Positive test

A positive test is indicated by increased posterior excursion of the tibia and an associated loss of the normal end-feel. An increase in the slope of the infrapatellar tendon may also be noted.

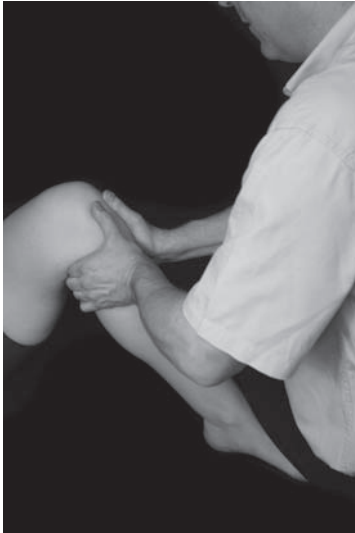

Fig. 6.3 • Posterior drawer test.

Clinical context

In a complete PCL tear, the average extent of posterior excursion of the tibia is 9.2mm although incomplete tears will produce varied degrees of laxity (Hewett et al 1997). Injury of other stabilizing structures (i.e. arcuate–popliteus complex, posterior oblique ligament, iliotibial band) should always be considered as a potential source of pain and/or instability. Posterior excursion can be assessed and graded by measuring the amount of 'step-off' between the anterior tibial plateau and the femoral condyles (Larsen & Toth 2005).

Grade	Amount of step-off between anterior tibial plateau and femoral condyles
1	Palpable step (approx 5 mm)
2	The normal anterior step is eliminated and the medial femoral condyle and medial tibial plateau are level
3	The medial tibial plateau is displaced posteriorly in relation to the medial femoral condyle resulting in a reverse 'step off'. With this finding, posterolateral corner and medial injuries should also be considered

The posterior drawer test is considered to be the most accurate test for diagnosing isolated PCL injuries but this has not been verified in studies examining its use as an isolated test. A high degree of sensitivity and specificity has been recorded where it is used as part of a composite assessment to determine PCL injury, particularly when complemented by other tests such as the posterior sag test (Malanga et al 2003); analysing the test in this context is helpful as it mirrors usual clinical practice.

Perhaps unsurprisingly, increased inter-examiner reliability has been noted in the presence of more significant grade II and III injuries (Rubenstein et al 1994).

TABLE 6.1 POSTERIOR DRAWER TEST

Author and year	LR+	LR-	Target condition
Jackson et al 2003	16.2 ★★★	0.2 ★★	PCL tear as part of a composite assessment
Solomon et al 2001	21 ★★★	0.05 ★★★	PCL tear as part of a composite assessment
Rubenstein et al 1994	90 ★★★	0.10 ★★	PCL tear as part of a composite assessment

Clinical tip

With an isolated tear of the PCL, the greatest degree of tibial excursion is noted at 90° flexion. Where the injury is located to the posterolateral corner, most excursion is found when the test is performed in 30°. In a combined posterolateral corner and PCL injury,

increased posterior tibial movement will be noted when the test is repeated at both 30° and 90° flexion (Larsen & Toth 2005) and injury to other lateral stabilizers will be likely.

If the PCL is ruptured, the tibia, having lost some posterior restraint, tends to gravitate backwards (posterior sag sign). This false starting position can lead an inexperienced clinician to incorrectly record an increase in anterior tibial translation when in fact there is PCL insufficiency. Observing for a posterior sag of the tibia on the femur and performing the posterior drawer test prior to ACL assessment should guard against this (see related tests).

EXPERT OPINION	COMMENTS
★★★	<p>Posterior drawer test</p> <p>A standard test used in all patients which accurately identifies PCL tears.</p>

Related tests

The *posterior sag sign/gravity drawer test/Godfrey's test* is a useful adjunct to the posterior drawer test. The patient lies supine with the hips and knees flexed to 90° and the lower legs supported by the clinician. If posterior instability is present, a posterior 'sag' appears and additional backward pressure will increase this posterior displacement.

The *active drawer test/quadriceps active test* can be helpful in confirming PCL insufficiency. In the drawer test position with the foot stabilized, the patient is asked to attempt to extend the knee. The backwards sag of the tibia will be reduced with this isometric contraction of the quadriceps (bringing the tibia back into its normal position) and increased with hamstring isometric contraction. This positions the tibia in its fully displaced position and provides a good starting position for maximum anterior translation to occur when the quadriceps contract again.

Anterior drawer test

Purpose

To detect anterior (one-plane) instability and anterior cruciate ligament (ACL) laxity.

Technique

Patient position

Lying supine with the knee flexed to 90° and foot placed on the couch.

Clinician position

The patient's foot is stabilized by sitting on the dorsum of the forefoot. Both hands grasp around the upper tibia with thumbs placed anteriorly over the joint line. Also, in this position the hamstring tendons can easily be palpated to ensure the muscle is completely relaxed and that voluntary or involuntary resistance to the test is avoided.

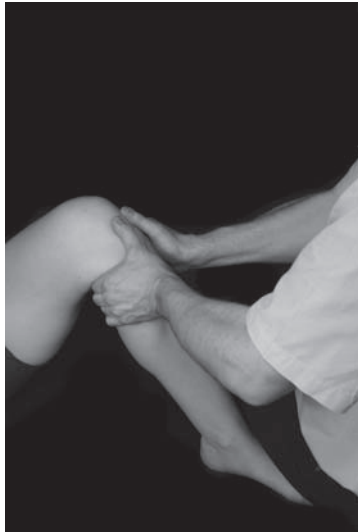Action

The tibia is drawn forwards with both hands and a comparison of the degree of anterior translation is made with the other knee. The quality of the joint end-feel should be appreciated and a ligamentous 'stop' noted if the ligament remains intact.

Positive test

Increased anterior excursion of the tibia accompanied by the loss of normal ligamentous resistance usually indicates significant

Fig. 6.4 • Anterior drawer test.



injury. In a healthy knee, it is normal for approximately 6 mm of anterior tibial translation to be present (Magee 2008). If the ACL is injured in combination with the medial ligament/capsule, a much greater degree of anterior translation will be present (15 mm or more).

Clinical context

In an evaluation of the evidence around physical tests at the knee, a composite assessment (which included the anterior drawer test) was found to be more accurate than any one single test in diagnosing ligament and meniscal lesions (Solomon et al 2001). The test has also demonstrated a high degree of specificity (Jackson et al 2003) although doubts over its degree of sensitivity led other studies to conclude that the test should be secondary to the more sensitive Lachman (see p. 194) or pivot shift test (see p. 201) (Benjaminse et al 2006, Jackson et al 2003, Ostrowski 2006, Scholten et al 2003). It is an easier test to perform, however, and for the less experienced practitioner, the findings may be more helpful than trying to detect abnormalities with the pivot shift test. The sensitivity of all these tests improves when testing in the acute stages is avoided and they are used either when the patient is anaesthetized or in the sub-acute/chronic stage of the condition.

In the test position of 90° knee flexion, the MCL and posterior capsule provide secondary restraints to anterior tibial translation. If these structures are intact and the ACL is injured in isolation, the drawer test will be normal, leading to a false negative result. Other factors that can lead to a false negative result are hamstring spasm, a bucket-handle meniscal tear which blocks anterior translation of the tibia, or a partial ACL tear which has attached to the PCL during the healing process (Kim & Kim 1995). A false positive test can occur (increased anterior translation even when the ACL is intact) if the medial coronary (meniscotibial) ligament has been disrupted (Magee 2008). Increased anterior excursion of the medial tibial condyle should lead the clinician to conduct further multiplanar tests (see Slocum AMRI, p. 198) to establish the extent of the rotational instability. If a click or sudden shift accompanies a positive drawer test, suspicion of a concurrent meniscal tear should be aroused. The sudden movement or jerk is known as *Finochietto's jump sign* (Magee 2008).

TABLE 6.2 ANTERIOR DRAWER TEST

Author and year	LR+	LR-	Target condition
Scholten et al 2003 (review)	5.17 ★★	0.43 ★	ACL rupture
Solomon et al 2001 (systematic review and pooled data summary)	3.8 ★	0.3 ★	ACL rupture
Benjaminse et al 2006 (systematic review and pooled data)	10.2 ★★★	0.09 ★★★	Chronic ACL rupture
Katz & Fingerroth 1986	7.4 ★★ 17.93 ★★★	0.8 0.48	Acute ACL rupture under anaesthesia Chronic ACL rupture under anaesthesia
Lee et al 1988	78 ★★★	0.2 ★★	ACL rupture

Clinical tip

If the posterior cruciate ligament has been injured it can be difficult to establish the normal starting position for this test. PCL laxity or rupture will cause the tibia to drop backwards (posterior sag sign, see p. 191) which then falsely leads to an apparent increase in anterior drawer. It is therefore necessary to eliminate a positive sag sign before recording an increase in anterior drawer.

EXPERT OPINION	COMMENTS
★★	Anterior drawer test Useful as a secondary test if Lachman's test is equivocal.

Lachman's test

Aka

Anterior drawer in extension test

Trillat test

Lachman-Trillat test

Ritchie test

Purpose

To detect anterior (one-plane) instability and anterior cruciate ligament (ACL) laxity.

Technique

Patient position

Lying supine.

Clinician position

The patient's foot is stabilized between the clinician's thigh and the couch. The outside hand is placed over the lateral aspect of the thigh just above the knee joint and the fingers wrapped around the back of the lower thigh while counterpressure is applied anteriorly with the thumb. The inside hand is placed over the medial aspect of the leg just below the knee joint using an identical grip, with the thumb placed over the tibial tuberosity and the knee positioned in about 10–30° of flexion.

Action

With the outside hand stabilizing the femur, the lower hand firmly pulls the tibia forwards in an attempt to generate anterior translation. The quality of the joint end-feel should be appreciated and a firm ligamentous 'stop' noted in the normal knee.

Positive test

Increased anterior excursion of the tibia on the femur with an accompanying change in the end-feel usually indicates a significant injury. The firm resistance gives way to a softer or even absent end-feel. The normal slope of the infrapatellar tendon also diminishes.

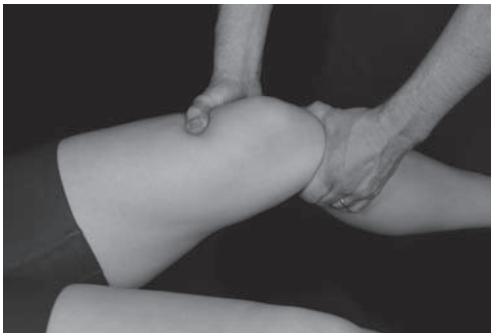

Fig. 6.5 • Lachman's test.

Clinical context

This is a test for one-plane anterior instability and is the most sensitive physical test for diagnosing an isolated ACL injury. It was originally described by Torg but he named the test after his boss, Lachman (Torg et al 1976).

In studies using arthroscopy as the 'gold standard' for ACL diagnosis (Jackson et al 2003, Ostrowski 2006) Lachman's test has been shown to be both more sensitive and specific compared with the anterior drawer (see p. 191) and pivot shift (see p. 201) tests. The Lachman test has also been found to be more accurate than MRI in the diagnosis of ligamentous injury (Kocabey et al 2004, Liu et al 1995, Rose & Gold 1996), a negative test thereby effectively ruling out complete ACL rupture (Scholten et al 2003).

The test is less sensitive where there is complex or acute injury (Frobell et al 2007, Yoon et al 1997) and, as with all ligament tests at the knee, is more sensitive when performed under anaesthesia (Kim & Kim 1995, Katz & Fingerroth 1986). Torg's original study (Torg et al 1976) examined its use on patients with combined ACL and meniscal lesions and reported high levels of sensitivity, largely unaffected by the presence of bucket-handle tears. False negative results have been reported however, in cases where there is only a partial tear of the ACL, in chronic lesions where the injured ACL has adhered to the PCL, or where there is a concurrent meniscal injury sufficiently significant to prevent anterior translation of the tibia (Kim & Kim 1995).

In the test position, maximum tension is found in all portions of the ACL (Kim & Kim 1995). If instability is detected, stress X-rays *can* assist in grading the degree of injury (see below) although, in practice, clinicians are more likely to use their findings on examination to subjectively grade the degree of tibial translation.

Grade	Amount of anterior tibial translation
1	< 5 mm
2	5–10 mm
3	>10 mm

Clinical tip

In the larger patient, the knee can be supported in the required flexed position over the clinician's knee, making handling a heavy leg easier.

TABLE 6.3 LACHMAN'S TEST

Author and year	LR+	LR-	Target condition
Scholten et al 2003	9.6 ★★	0.15 ★★	ACL rupture
Solomon et al 2001	25 ★★★	0.1 ★★	ACL rupture
Benjaminse et al 2006	14.2 ★★★	0.16 ★★	Chronic ACL rupture
Katz & Fingerroth 1986	15.4 ★★★ 16.9 ★★★	0.23 ★ 0.16 ★★	Acute ACL rupture under anaesthesia Chronic ACL rupture under anaesthesia
Lee et al 1988	88 ★★★	0.12 ★★	ACL rupture
Jackson et al 2003	12.3 ★★★	0.14 ★★	ACL rupture

The degree of anterior drawer can be palpated if the fingers of the outside hand are placed over the joint line while the tibia is drawn forwards.

The knee must be maintained in a degree of flexion throughout the test to reduce tension on the medial and lateral collateral ligaments and the iliotibial band, thereby minimizing their ability to restrain anterior movement of the tibia (Magee 2008). Lerat et al (2000) suggested that sensitivity of the test was improved by positioning the tibia in slight external rotation with the anterior translatory force coming from a posteromedial direction, as anterior translation of the medial compartment is thought to be a better indication of ACL deficiency in chronic tears than translation of the lateral compartment.

EXPERT OPINION	COMMENTS
★★★	Lachman's test Extremely helpful, with a positive test confirming an ACL tear, but the range must be compared with the unaffected knee as this varies considerably in the normal population.

B MULTI-PLANE TESTS

● **Anteromedial rotatory instability (AMRI)**

Slocum (AMRI) test

Aka

Modified anterior drawer test
Lemaire's 'T' drawer test

Purpose

To detect anteromedial rotatory instability (AMRI) of the knee.

Technique

Patient position

Lying supine with the hip flexed to 45°, the knee flexed to 90° and the foot placed on the couch.

Clinician position

The foot is turned out so that the tibia is positioned in about 15° of external rotation and then stabilized by sitting on the dorsum of the forefoot. Both hands grasp around the upper tibia, with thumbs placed anteriorly over the joint line in order to be able to detect anterior movement of the tibia. The fingers are well placed to ensure the hamstrings are completely relaxed so that resistance to anterior movement of the tibia is avoided.

Action

The tibia is drawn forwards with both hands and the extent of anterior translation on the medial side of the knee is noted. The quality of the joint end-feel should be appreciated and a ligamentous 'stop' noted in the absence of significant injury.

Positive test

Increased anterior excursion of the medial tibial condyle.

Clinical context

AMRI occurs as a result of a forceful external rotation injury to the flexed knee while the foot is planted (e.g. pivoting on the weight-bearing foot while running or jumping); the injury is therefore often sustained during sporting activities.

The sequence of injury originally described by Slocum & Larson (1968) started with rupture of the medial collateral ligament and medial joint capsule followed by the posterior oblique ligament.

If the knee continues to rotate into further external rotation, especially if accompanied by a valgus force, strain then falls on the anterior cruciate ligament which will ultimately rupture if the force is great enough. With this degree of instability, abnormal loading of the medial meniscus over time will predispose the knee to further injury. Given the structures implicated in AMRI, other physical tests should be used to fully assess the stability of the knee (see Lachman's test, p. 194; valgus test, p. 183).

The degree of instability *can* be graded with stress X-rays by measuring the extent of anterior subluxation of the tibia (Magee 2008) (see below) although, in practice, clinicians are more likely to use their findings on examination to subjectively grade the degree of tibial translation.

Grade	Amount of anterior tibial translation
1	<12 mm
2	12–20 mm
3	>20 mm

Clinical tip

The tibia must not be *fully* rotated as this will tension the surrounding structures and could lead to a false negative finding. If abnormal external rotation is noted when placing the leg into the pre-test position, major disruption of the medial capsule and deep portion of the medial ligament should be suspected. Greater degrees of instability would also implicate injury to the more superficial layer of the medial ligament and ACL (Slocum & Larson 1968).

EXPERT OPINION	COMMENTS
★★	<p>Slocum (AMRI) test</p> <p>There is a lack of evidence to determine relative sensitivities and specificities for this test and it is considered by clinicians to be insufficient, if used in isolation, to diagnose AMRI with confidence. It should therefore be employed alongside other instability tests.</p>

● Anterolateral rotatory instability (ALRI)

Slocum (ALRI) test

Aka

Modified anterior drawer test

Purpose

To detect anterolateral rotatory instability (ALRI) of the knee joint.

Technique

Patient position

Lying supine with the hip flexed to 45°, the knee flexed to 90° and the foot placed on the couch.

Clinician position

The tibia is positioned in about 30° of internal rotation. The foot needs to be stabilized for this test and this can be achieved by sitting on the dorsum of the forefoot. Both hands grasp around the upper tibia with thumbs placed anteriorly over the joint line in order to be able to detect anterior movement of the tibia. The fingers are well placed to ensure the hamstrings are completely relaxed so that muscular resistance to anterior movement of the tibia is avoided.

Action

The tibia is drawn forwards with both hands and the extent of anterior translation on the lateral side of the knee is noted. The quality of the joint end-feel should be appreciated and a ligamentous 'stop' noted in the absence of significant injury.

Positive test

Increased anterior excursion of the lateral tibial condyle.

Clinical context

This is a modification of the anterior drawer test and is thought to detect the degree of anterolateral rotational excursion more specifically. In the normal knee, forward translation of the tibia in this position of internal rotation is prevented by tension in the posterolateral capsule, cruciate ligaments, popliteus tendon, lateral collateral ligament and iliotibial band. A positive test may indicate injury to one or more of these structures (Slocum & Larson 1968). Some laxity on varus testing (see p. 186) is also often evident, both with the knee flexed and in full extension.

Clinical tip

The tibia must not be *fully* rotated as this will increase the tension of the cruciates and surrounding structures, which may reduce the sensitivity of the test and lead to a false negative finding.

EXPERT OPINION	COMMENTS
★★	<p>Slocum (ALRI) test</p> <p>The test can be useful if ALRI is suspected; however it can be difficult to interpret and other, more sensitive and specific tests for ALRI (e.g. pivot shift) may be preferred.</p>

Pivot shift test

Aka

Lateral pivot shift test
Test of Macintosh

Purpose

To assess for anterolateral rotational instability (ALRI) and laxity of the anterior cruciate ligament (ACL).

Technique

Patient position

The patient lies supine with the head supported and leg relaxed.

Clinician position

The patient's hip is flexed to 45° and abducted to about 30° with the knee in 50° of flexion (the reduced position). The tibia is internally rotated by using the heel as a lever with the thumb of the caudal hand over the lateral border of the calcaneus and the fingers gripping medially. The cephalic hand is placed on the outside of the leg just below the knee joint (Fig. 6.6A).

Action

While maintaining the internal rotation, a valgus stress is applied with the cephalic hand as the knee is moved towards extension (Fig. 6.6B).

Positive test

The lateral tibial condyle subluxes forwards on the tibial plateau as the knee approaches extension, sometimes accompanied with a clunk (Fig. 6.6C).

The tibial condyle can also be reduced by reversing the manoeuvre. The knee is gradually taken into increasing flexion while maintaining the valgus and rotational torque. At around 30° the tibia reduces backwards with a sudden 'jerk' – caused by the iliotibial

band (ITB) changing its position and function from an extensor to a flexor and pulling the tibia back into its normal position as a result.

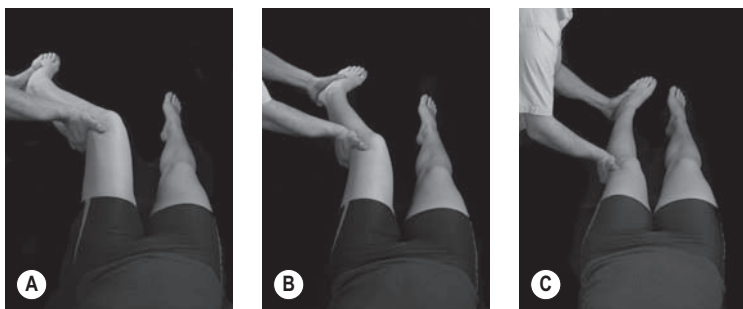


Fig. 6.6 • The pivot shift test start position (A). As internal rotation, valgus and extension are added, the knee is most likely to sublux at about 30° off full extension (B) before the end position is achieved (C).

Clinical context

The ACL is intimately involved in controlling the rolling and sliding that takes place during flexion/extension movements of the knee. When torn, the ACL is unable to control this complex mechanism and this leads to a repeated cycle of anterior subluxation (and reduction) of the lateral tibial plateau on the femoral condyle causing the patient to report pain, apprehension to certain movements and giving way on activity. The test assesses the dynamic stability of the knee and often reproduces the 'giving way' feeling reported so often by patients. In addition to testing the integrity of the ACL, stress is also placed on the other lateral stabilizers (posterolateral capsule, arcuate–popliteus complex, lateral collateral ligament and the ITB).

The pivot shift test is widely regarded as the primary test for ALRI (Ostrowski 2006) as it is considered to have a high degree of sensitivity and specificity for diagnosing ACL injury (Katz & Fingerroth 1986, Malanga et al 2003). It has been found to be at least as accurate as MRI in the diagnosis of ACL injury (Kocabey et al 2004) although much of the research has been conducted on anaesthetized patients. The test has been shown to have a much lower level of sensitivity in the alert patient, particularly in acute conditions where it drops as low as 35% (Donaldson et al 1985). A false negative result can also arise from protective muscle spasm in the acute knee, the inability

of the patient to relax the muscles around the knee adequately or where other pathology/injury exists (e.g. medial collateral ligament injury, partial ACL tear, rupture of the iliotibial tract, lateral compartment osteoarthritis, meniscal injury) (Kim & Kim 1995).

The test can be difficult to perform in the outpatient setting with an alert patient, and the drawer type tests (Lachman's test, Slocum test, etc.) are regarded as being easier to perform and more likely to yield an accurate result in this environment. The pivot shift test can be quite uncomfortable for the alert patient (provocation of pain and muscle spasm in the acute knee is common) and is technically more challenging for the clinician – a combination which may lead to an inaccurate result (Anderson et al 2000).

There are a number of variations on this test (e.g. *soft pivot shift test*, the *jerk test of Hughston*, *active pivot shift test*, *Losee test*) but these are no easier to perform well and evidence to support their use is lacking.

TABLE 6.4 PIVOT SHIFT TEST

Author and year	LR+	LR–	Target condition
Scholten et al 2003	16 ★★★	0.69	ACL rupture
Boeree & Ackroyd 1991	10.3 ★★★	0.7	ACL rupture and menisci
Benjaminse et al 2006	12 ★★★	0.78	ACL rupture
Katz & Fingerroth 1986	49.2 ★★★	0.02 ★★★	ACL rupture under anaesthesia
Jackson et al 2003	20.3 ★★★	0.4 ★	ACL rupture

Clinical tip

The patient should recline in such a way as to ensure the muscles around the knee are completely relaxed when testing. Attention should be paid to the position of the hip as this has considerable bearing on the tension of the ITB – the test is more sensitive when

the hip is positioned into some abduction and less so in adduction. The ITB also needs to be intact in order for the tibia to 'jerk' back into a reduced position although the subluxation would still be evident regardless. It is important not to take the knee into full extension as the 'locking home' mechanism of the knee forces the joint into a stable position where rotatory instability cannot be detected.

EXPERT OPINION	COMMENTS
★★	<p>Pivot shift test</p> <p>This test requires considerable experience to perform well and evaluate the findings accurately.</p>

● Posteromedial rotatory instability (PMRI)

Posteromedial drawer test

Aka

Hughston's posteromedial drawer sign

Purpose

To assess for posteromedial rotatory instability (PMRI).

Technique

Patient position

Lying supine with the hip flexed to 45° and the knee flexed to about 90°. The foot is positioned inwards so that the tibia is internally rotated and stabilized on the couch.

Clinician position

The foot needs to be stabilized for this test and this can be achieved by sitting on the dorsum of the forefoot. Both hands grasp around the upper tibia with thumbs placed anteriorly over the joint line in order to be able to detect posterior movement of the tibia.

Action

The tibia is pushed posteriorly, noticing the degree of posterior excursion on the medial side of the knee compared with the unaffected side.

Positive test

The tibia subluxes posteriorly and the posterior part of the medial femoral condyle falls backwards into some internal rotation. This is best assessed by looking at differences in condylar prominences of the tibia when compared to the contralateral knee.

Clinical context

This variation of the posterior drawer test is used to detect the possibility of PMRI, which should be considered when posterior cruciate and medial collateral ligament rupture co-exist. The anterior and posterior cruciate ligaments, posterior oblique ligament, posteromedial capsule, medial collateral ligament and semimembranosus can also be involved in PMRI.

Clinical tip

In the test position, gravity acts on the tibia and causes it to drop back, potentially leading to a false positive test. Care should be taken to ensure that the tibia is in a neutral position prior to testing.

EXPERT OPINION	COMMENTS
★★	<p>Posteromedial drawer test</p> <p>Although not used routinely, it is the test of choice when a diagnosis of PMRI is being considered.</p>

● Posterolateral rotatory instability (PLRI)

Posterolateral drawer test

Aka

Hughston's posterolateral drawer sign

Purpose

To assess for posterolateral rotatory instability (PLRI).

Technique**Patient position**

Lying supine with the hip flexed to 45° and the knee flexed to about 90°. The foot is positioned outwards so that the tibia is externally rotated to a maximum of 15° and stabilized on the couch.

Clinician position

The foot needs to be stabilized for this test which can be achieved by sitting on the dorsum of the forefoot. Both hands grasp around the upper tibia with thumbs placed anteriorly over the joint line in order to be able to detect posterior movement of the tibia.

Action

The tibia is pushed posteriorly noticing the degree of posterior excursion on the lateral side of the knee compared to the unaffected side.

Positive test

Essentially, in tests for PLRI, the clinician assesses for excessive posterior rotation of the lateral tibial condyle. In this test, increased posterior excursion or rotation of the lateral tibial condyle when compared to the contralateral knee indicates a tear of both the PCL and the lateral collateral ligament (LaPrade & Terry 1997).

Clinical context

The terminology used in the literature regarding the anatomical structures involved in injuries at the posterolateral corner is inconsistent. Essentially, varus movement is controlled by the lateral ligament and capsule while external rotation of the femur is primarily controlled by the posterior cruciate ligament, arcuate–popliteus complex, lateral collateral ligament, biceps femoris tendon and the posterolateral capsule.

A high incidence of multiple ligament involvement and peroneal nerve trauma are associated with posterolateral injury and a variety of physical tests are recommended to provide a complete evaluation of stability including the external recurvatum test (see p. 211), varus test (see p. 186), posterolateral drawer test (see p. 205), the dial test (see p. 209) and the reverse pivot shift test (see p. 207) (Hughston & Norwood 1980, LaPrade & Wentorf 2002).

Although a positive posterolateral drawer test is said to be diagnostic of PLRI (Baker et al 1983) there is an absence of rigorous studies to support this. Posterolateral corner injuries are comparatively rare and account for only 2% of all acute knee ligament injuries, most frequently occurring during high-energy / impact sporting activities (Larsen & Toth 2005).

Clinical tip

In the test position, gravity acts on the tibia and causes it to drop back, potentially leading to a false negative result. Care should

be taken to ensure that the tibia is in a neutral position prior to testing.

EXPERT OPINION	COMMENTS
★★	<p>Posterolateral drawer test</p> <p>Although not used routinely, it is a useful test along with the dial test (see p. 209) where PLRI is a diagnostic possibility.</p>

Reverse pivot shift test

Aka

Jakob test

Purpose

To assess for posterolateral rotatory instability (PLRI).

Technique

Patient position

The patient lies supine with the leg relaxed.

Clinician position

The caudal hand grasps the heel and places the forearm against the medial border of the foot in order to maintain external rotation of the tibia throughout the test while the cephalic hand supports the anterior and medial aspects of the knee. The hip is flexed to about 45° and the knee taken into about 80° flexion.

Action and positive test

The caudal hand maintains the external rotation of the tibia, at the same time applying a valgus stress to the knee (Fig. 6.7A). This position causes the lateral tibial plateau to sublux posteriorly in an unstable knee. The knee is then allowed to extend slowly and at around 20–30° of flexion, the iliotibial band then lies anterior to the axis of rotation, suddenly bringing the lateral tibial condyle back into a neutral position, indicating a positive test (Fig. 6.7B).

Clinical context

This tests posterolateral corner instability caused by injury to the lateral collateral ligament and the posterolateral stabilizers (see posterolateral drawer test, p. 205; Laprade & Terry 1997). Although

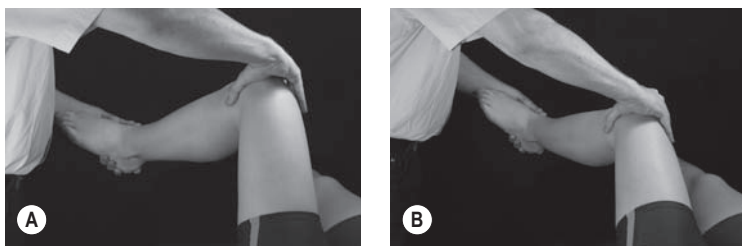


Fig. 6.7 • Reverse pivot shift test. Start position of subluxation (A) and end position (B) of relocation in further knee extension.

comparatively rare, PLRI is considerably more disabling than medial instability as it involves injury to multiple structures and can be accompanied by anterolateral and anteromedial instability when the anterior cruciate ligament and medial capsular ligaments are also involved.

The reverse pivot shift test is considered to be a difficult test to perform and hard to reproduce consistently, even with an anaesthetized patient (Larsen & Toth 2005) and this was verified in a study by Cooper (1991) in which the test was considered positive in 35% of normal knees examined under anaesthesia.

Many clinicians rely more on the drawer type tests (see posterolateral drawer test, p. 205) in the outpatient setting because they are more comfortable for the patient, easier to perform for the clinician and more likely to yield an accurate finding (Anderson et al 2000). Given the complexity of PLRI, a variety of physical tests are recommended to provide a complete evaluation of the posterolateral stability of the knee including the external recurvatum test (p. 211), the varus test (see p. 186), the posterolateral drawer test (see p. 205) and the dial test (see p. 209) (Bahk & Cosgarea 2006; LaPrade & Wentorf 2002).

There is little evidence on the accuracy of any of the tests for the lateral structures of the knee, possibly because lateral instability is much less frequently encountered.

Clinical tip

The test can also be done with the patient standing, using a support for balance, with the weight equally distributed between both legs. The examiner places one hand above, and the other below the knee, applying a valgus stress; the patient initiates knee flexion while

weight-bearing. A positive test is indicated by the knee giving way or the tibia shifting posteriorly with a jerk (Magee 2008).

EXPERT OPINION	COMMENTS
★	Reverse pivot shift test Rarely used as other tests such as the dial test are easier to perform and more accurate.

Dial test

Aka

Tibial lateral rotation test

Purpose

To assess for posterolateral rotatory instability (PLRI).

Technique

Patient position

Lying supine with the thigh abducted so that the knee can flex over the side of the couch.

Clinician position

The thigh is stabilized with the cephalic hand while the other hand grasps the heel and uses the forearm to push the foot into dorsiflexion.

Action and positive test

Using the dorsiflexed foot as a lever, the knee is passively flexed to 30° and externally rotated. The extent of rotation is noted in comparison to the other knee (Fig. 6.8A) but an excess of 10° is considered to be a positive test. The test is then repeated in 90° of flexion, still with the thigh comfortably supported on the couch. The clinician again assesses for excessive tibial rotation (Fig. 6.8B) with increased external rotation in this position also incriminating the posterior cruciate ligament (PCL).

Clinical context

The dial test assesses for posterolateral corner and PCL injury. As PLRI involves injury to multiple structures (see posterolateral

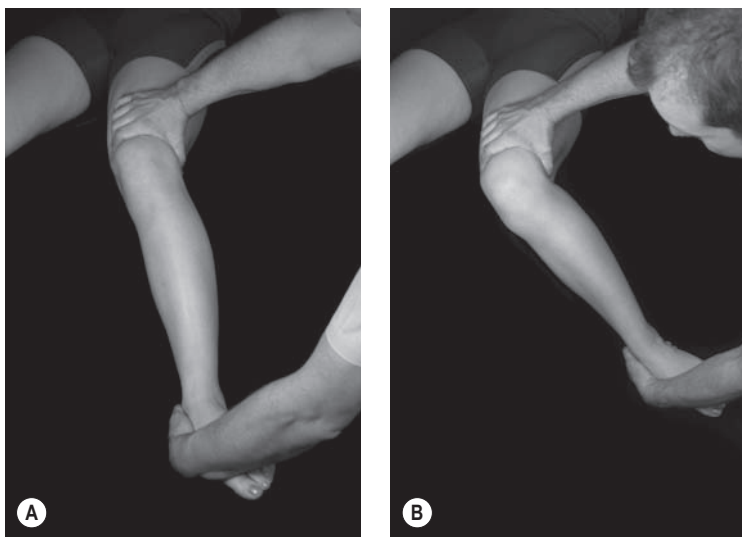


Fig. 6.8 • In the dial test, the amount of tibial external rotation is compared in 30° (A) and 90° (B) knee flexion.

drawer test, p. 205) a variety of physical tests are recommended to provide a complete evaluation of the posterolateral stability of the knee (Bahk & Cosgarea 2006, LaPrade & Wentorf 2002).

There is little evidence on the accuracy of any of the tests for the lateral structures of the knee. These diagnostic tests require skilled handling and interpretation and, because of this, can be frequently misinterpreted (Hughston et al 1976).

Clinical tip

The foot and tibial tubercle provide useful visible markers to observe the extent of tibial rotation during this test.

EXPERT OPINION	COMMENTS
★★★	Dial test The most helpful test in assessing for PLRI.

Variations

Alternative positions have been described to perform the dial test. The patient's leg and foot can remain on the couch and passive external rotation of the foot and tibia performed in a similar manner in first 30° and then 90° knee flexion. A second version starts with the patient in the prone position. The knee is flexed to 30° and the degree of tibial external rotation is noted. Maintaining the external rotation, the knee is flexed further to 90°.

In all cases, increased range of external rotation at 30° knee flexion indicates posterolateral corner injury. If increasing the knee flexion to 90° abolishes the external rotation discrepancy, the PCL can be assumed to be functioning; however, more pronounced discrepancy implicates both the posterolateral corner and the PCL.

With *Loomer's test/Bousquet external hypermobility test* the patient lies supine with both hips and knees flexed to 90°. The clinician passively externally rotates both tibias to the end of range. Observation of excessive rotation *and* a posterior sag of the tibia on the femur indicate a positive test.

External rotation recurvatum test

Purpose

To detect the presence of posterolateral instability (PLRI).

Technique

Patient position

Lying supine with the leg relaxed.

Clinician position

Standing at the end of the couch facing the patient, both big toes are grasped.

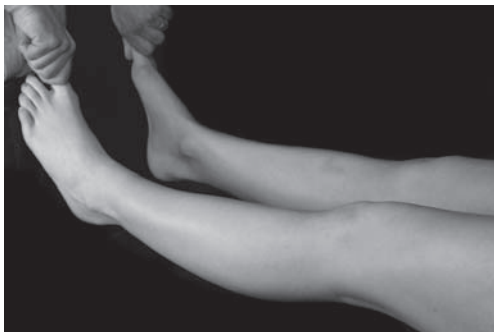Action

The feet and legs are passively lifted from the couch using the big toes while observing the extension and rotation movement of the tibial tuberosity and lateral tibial condyle compared to the uninjured knee.

Positive test

As in all tests for PLRI, the clinician is looking for excessive posterior subluxation/rotation of the lateral tibial condyle. In this test, hyperextension and varus as well as increased external rotation of the tibia would be expected.

Fig. 6.9 • External recurvatum test.



Clinical context

In a study comparing physical assessment and surgical findings, a correlation was observed between a positive external rotation recurvatum test and injury to the lateral collateral ligament and the lateral head of gastrocnemius tendon (LaPrade & Terry 1997). As PLRI can involve injury to multiple structures (see posterolateral drawer test, p. 205) a selection of physical tests are necessary to fully evaluate posterolateral stability (LaPrade & Wentorf 2002).

In a small study, Baker et al (1983) suggested that a positive external rotation recurvatum test or posterolateral drawer test should be considered diagnostic of PLRI but there is limited evidence to support this, with reported sensitivity varying from 33% to 94% (Larsen & Toth 2005).

Clinical tip

Spasm or tension in the hamstrings during this test can mask PLRI, resulting in a false negative result.

C MENISCAL TESTS

Apley's test

Aka

Apley's grinding test

Purpose

To elicit pain and/or apprehension resulting from meniscal injury or pathology.

Technique

Patient position

Prone lying with the knee positioned in 90° flexion. The couch needs to be low enough to allow the clinician's knee to fix the lower thigh during the manoeuvre.

Clinician position

The clinician's cephalic knee is positioned over the patient's lower thigh and a firm but comfortable pressure is applied to maintain the thigh's position against the couch during the test.

Action

This test involves rotation of the tibia with both distraction and compression.

Firstly, rotation with distraction is tested. Cupping the dorsum of the foot with the caudal hand and applying a firm hold around the ankle with the other, the knee is distracted by pulling longitudinally along the line of the tibia, using both hands to achieve this. Once the distraction is on, internal and external tibial rotation is applied with both hands (Fig. 6.10A).

Rotation under compression is then applied. Both hands change position. The caudal hand fixes the forefoot in a plantigrade position while the other is placed over the heel in order to apply compression along the longitudinal axis of the tibia. Once the compression is added, internal and external tibial rotation is applied, using the foot as a lever (Fig. 6.10B).

Positive test

Pain and/or apprehension elicited when rotation is applied under compression which reduces when the test is repeated with distraction.

Clinical context

There are many meniscal tests recorded in the literature, most of which are variations on either Apley's, McMurray's (see p. 215) or the weight-bearing rotation test (see p. 218). Relying on Apley's test in isolation has been found to be a poor predictor of meniscal pathology (Malanga et al 2003) and the test is not sufficiently sensitive or specific to provide a definitive diagnosis, particularly when the injury is comparatively minor or accompanied by other pathology such as osteoarthritis. One study reported a greater sensitivity for the test in patients with a history suggesting a meniscal tear (Karachalios et al 2005), confirming work by other authors concluding that a combination of history and

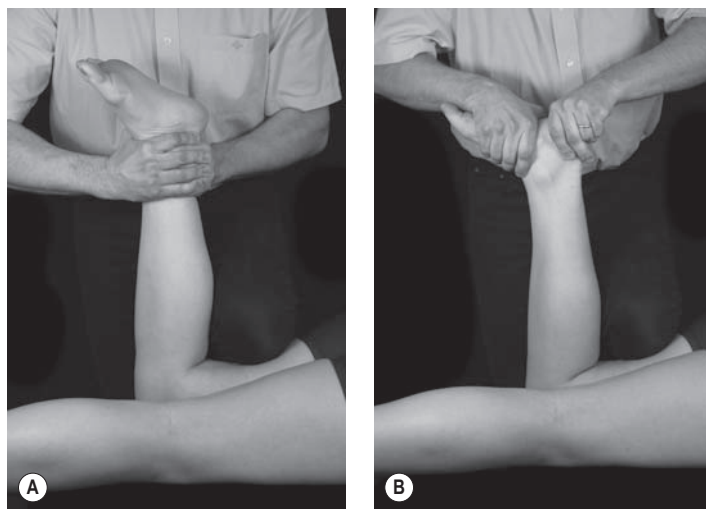


Fig. 6.10 • Apley's test with distraction (A) and compression (B).

TABLE 6.5 APLEY'S TEST

Author and year	LR+	LR–	Target condition
Karachalios et al 2005	5.86 ★★	0.63	Medial meniscus
Karachalios et al 2005	2.9 ★	0.69	Lateral meniscus
Fowler & Lubliner 1989	0.8	1.05	Both menisci
Ryzewicz 2007	0.8–5.9 ★★	0.6–1.1	Both menisci
Malanga et al 2003	1.3	0.97	Both menisci

examination findings provides an accurate predictor of patients likely to require arthroscopic surgery (Solomon et al 2001). However, both the McMurray and weight-bearing rotation tests have been shown to be more accurate than Apley's.

Clinical tip

Unwanted stress to the ankle ligaments can be avoided by maintaining the foot in a plantigrade position during the manoeuvre.

The distraction element of this test should always be applied first in order to ascertain the response before the knee is tested under compression when provocation of both pain and apprehension are most likely.

In addition to testing the menisci, stress will also fall on the ligamentous structures and increased pain under traction is more likely to incriminate the ligaments which would then require further evaluation.

EXPERT OPINION	COMMENTS
★	<p>Apley's test</p> <p>The lack of sensitivity and the availability of other tests has resulted in a decline in its use.</p>

McMurray's test

Purpose

To elicit pain and/or apprehension resulting from meniscal injury or pathology.

Technique

Patient position

Lying supine.

Clinician position

The cephalic hand is placed above the patella and, using the index finger and thumb, the medial and lateral joint lines are palpated in order to detect clicking during the test. The patient's heel is cupped with the caudal hand so that the forearm lies along the medial aspect of the foot enabling it to be used as a lever, so the tibia can be rotated externally.

Action

With the knee positioned in full flexion and external rotation, the leg is steadily extended to around 90°.

The test can then be repeated with the tibia held in internal rotation. The caudal hand is re-positioned so that the fingers cup the calcaneus medially with the thumb on the lateral aspect.

Positive test

Reproduction of the patient's pain, click or apprehension.

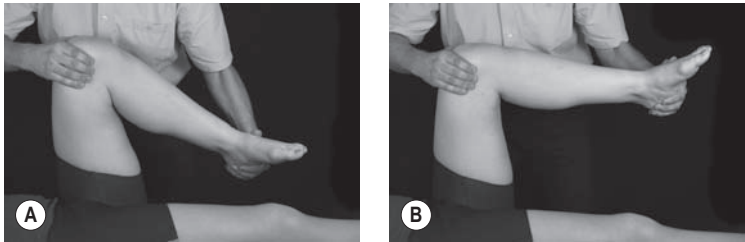


Fig. 6.11 • McMurray's test carried out with internal rotation of the tibia. Start (A) and end (B) position.

Clinical context

The original test described by McMurray, before the advent of arthroscopy, suggested that the posterior segments of both menisci were the areas predominantly stressed by this test. External rotation of the tibia was thought to increase stress in the posteromedial compartment with internal rotation increasing loading posterolaterally (McMurray 1942). There are several studies examining the accuracy of meniscal tests but their inclusion criteria vary, the presence of associated pathology is not always considered, and they differ in whether they consider pain, apprehension or a click to represent a positive test; this makes an overall judgement of their clinical usefulness difficult.

Across all studies, the sensitivity of the McMurray test is generally poor. A higher degree of sensitivity has been reported in populations of patients with a typical meniscal history (Karachalios et al 2005) and is lower where patients were selected based on a history of chronic knee pain or where no pre-test selection was attempted (Fowler & Lubliner 1989). However, a combination of a thorough history and examination has been found in several studies to be as accurate as MRI and on this basis, accurate clinical examination should provide sufficient grounds in most cases to determine the need for arthroscopy (Fowler & Lubliner 1989, Jackson et al 2003, Miller 1996, Ryzewicz et al 2007, Solomon et al 2001). A negative physical examination reduces the likelihood of a meniscal tear to less than 1.5% (Jackson et al 2003). MRI was found to be less accurate

than examination in children, adolescents and patients with degenerative tibiofemoral changes (Dervin et al 2001, Ryzewicz et al 2007).

TABLE 6.6 McMURRAY'S TEST

Author and year	LR+	LR–	Target condition
Karachalios et al 2005	8 ★★	0.55	Medial meniscus
Boeree & Ackroyd 1991	2.3 ★	0.8	Medial meniscus
Karachalios et al 2005	4.6 ★	0.41 ★	Lateral meniscus
Boeree & Ackroyd 1991	2.5 ★	0.8	Lateral meniscus
Evans et al 1993	8.0 ★★	0.9	Both menisci
Scholten et al 2001	8.0 ★★	0.9	Both menisci
Fowler & Lubliner 1989	7.8 ★★	0.7	Both menisci
Solomon et al 2001	1.3	0.8	Both menisci
Ryzewicz et al 2007	2.2–9.3 ★/★★	0.4–0.9 ★	Both menisci

Clinical tip

The conventional history of an acute locked knee following a weight-bearing, rotatory stress is often absent and in many patients with a meniscus lesion there may be no significant history of trauma, swelling or locking.

Diagnosing meniscal lesions in the presence of other knee pathology is more difficult, particularly if there is anterior cruciate ligament (ACL) involvement or underlying degenerative changes. If the ACL is normal, the combination of a block to full knee extension, a

positive McMurray test and pain on full flexion is highly suggestive of meniscal injury (Fowler & Lubliner 1989). Interestingly, joint line tenderness is also considered to be very sensitive in meniscal lesions and palpation is therefore a good accompaniment to the highly specific McMurray test (Jackson et al 2003, Karachalios et al 2005, Ryzewicz et al 2007, Solomon et al 2001).

EXPERT OPINION	COMMENTS
★★★	<p>McMurray's test</p> <p>Frequently used but false negatives and positives are not uncommon. A history of localized sharp pain and giving way, together with joint line tenderness, helps to point towards a meniscal diagnosis.</p>

Variations

A modification of the McMurray test is now widely used where a valgus or varus stress is added to the rotation component (Atkins et al 2010). This enhancement is thought to further challenge the integrity of the menisci and potentially improve the test's sensitivity but this variation has not been tested so these conclusions are speculative.

Weight-bearing/rotation meniscal test

Aka

Disco test
Merke's test
Thessaly test

Purpose

To elicit pain and/or apprehension resulting from injury or pathology to the medial and lateral menisci.

Technique

Patient position
Standing.

Clinician position

The clinician allows the patient to hold lightly onto their hands for support.

Action

Standing on the affected leg, the patient flexes the weight-bearing knee to approximately 20° , then rotates the femur with the body-weight over the fixed foot and tibia. Rotation into internal and external rotation is repeated several times.

Positive test

Pain, locking or apprehension on testing are considered positive findings.

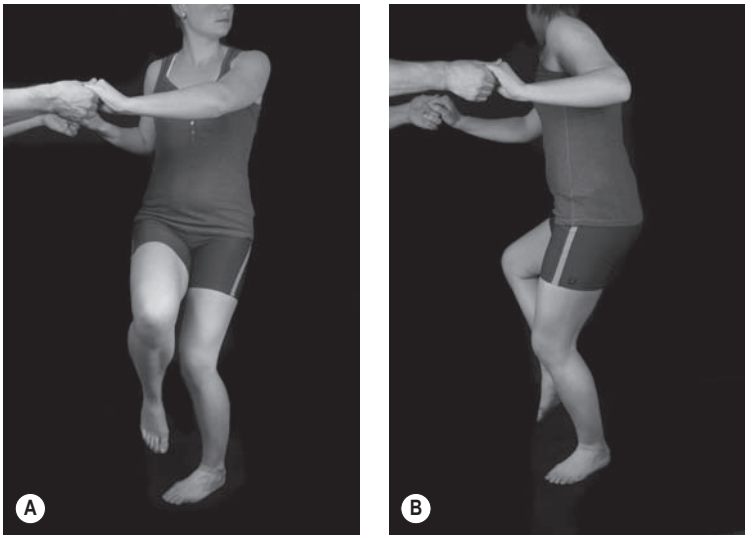


Fig. 6.12 • (A, B) Weight-bearing rotation test performed on the left leg.

Clinical context

This test aims to reproduce the likely mechanism of meniscal injury, but the forces exerted on the flexed knee may also expose ligamentous instability, so it is necessary for the clinician to assimilate all findings from the history and examination before suspicion falls on the menisci alone.

TABLE 6.7 WEIGHT-BEARING/ROTATION MENISCAL TEST

Author and year	LR+	LR–	Condition
Karachalios et al 2005	29.7 ★★★	0.11 ★★	Medial meniscus
Karachalios et al 2005	23 ★★★	0.08 ★★★	Lateral meniscus

In a study carried out by the test originators, the sensitivity and specificity of joint line tenderness, McMurray's, Apley's and the weight-bearing rotation test were measured, prior to MRI and arthroscopy, on a population of young subjects with an absence of other knee pathology but a history suggestive of meniscal injury. The weight-bearing rotation test performed better than both the McMurray and Apley tests (Karachalios et al 2005) and in a review of evidence around examination techniques at the knee, its accuracy was comparable to MRI in diagnosing meniscal lesions (Ryzewicz et al 2007).

Clinical tip

In the active, middle aged patient, the degenerative menisci may be responsible for symptoms that present without a dramatic history or presentation and, acutely, can be difficult to differentiate from degenerative arthritis.

EXPERT OPINION	COMMENTS
★★★	Weight-bearing/rotation meniscal test Used inconsistently probably because it is a comparatively recent addition but it is a good functional test which replicates the likely mechanism of injury.

Variations

Childress's test aims to isolate a lesion of the posterior horn of the meniscus. The patient squats and attempts to walk a few steps in this position, performing a 'duck waddle'; a positive test is indicated by pain, apprehension or locking (Magee 2008).

Ege's test is a variation of the McMurray's test in a weight-bearing position and involves squatting and rising with the knees first in an externally rotated position and then internally rotated; again, a positive test is indicated by pain, apprehension or locking (Akseki et al 2004).

D PATELLOFEMORAL TESTS

McConnell test

Purpose

To detect pain emanating from the patellofemoral articulation.

Technique

Patient position

The patient sits on the edge of a raised couch, with the femur externally rotated and the knee flexed over the side.

Clinician position

Sitting on a low stool, resistance to isometric extension is given by one hand which is positioned over the front of the shin while the other hand stabilizes the thigh.

Action

The patient holds an isometric contraction of the quadriceps for several seconds in varying degrees of flexion (120°, 90°, 60°, 30° and 0°) (Fig. 6.13A). If pain is reproduced in any of these positions the test is repeated while the clinician passively maintains a medial glide to the patella (Fig. 6.13B).

Positive test

Patellofemoral pain is indicated if pain is reproduced on isometric quadriceps contraction and lessened when the medial glide is applied in any of the positions tested.

Clinical context

The McConnell test reproduces the concentric activity of the quadriceps through range with the vastus medialis obliquus functioning particularly in the final degrees of extension to stabilize the patella (Bulstrode et al 2002).

In maximum flexion, the medial patellar facet is completely unloaded with the lateral and middle facets taking all the compressive force and the superior aspect of the patella providing the contact area. As the knee moves towards extension, the contact area of the patella moves inferiorly and the medial aspect starts to share some of the load (estimated to be around 40%) (Bulstrode et al 2002). An understanding of the forces acting through various parts of the articular surfaces of the patellofemoral joint (PFJ) may theoretically help the clinician to isolate the facet responsible for the symptoms during the test.

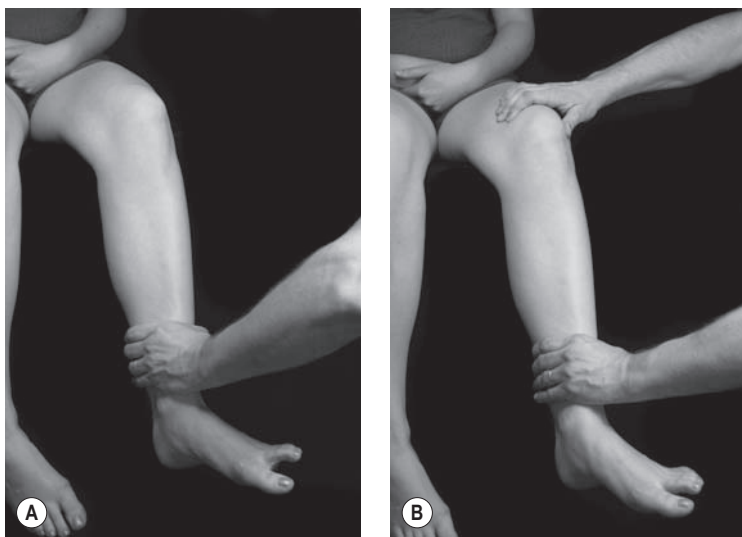


Fig. 6.13 • Resisted knee extension (A), repeated with a medial glide applied to the lateral aspect of the patella (B).

EXPERT OPINION	COMMENTS
★★	<p>McConnell test</p> <p>Useful to guide treatment for patellofemoral symptoms and anterior knee pain.</p>

Clinical tip

Because the patella is less mobile in positions of knee flexion, it can be helpful to return the knee to full extension before applying the medial glide and then maintain this as much as possible as the knee is taken back into the test position.

Variations

The *active patella grind test* has the patient extending the knee from 90° of flexion while the patella is palpated for crepitus and the onset of pain noted.

The patellofemoral joint can also be tested using *squat or step tests*. The patient is asked to step up or down from a step. In a small

study looking at the diagnosis of patellofemoral pain syndrome, the step-down (eccentric) phase was found to be a more accurate predictor than *Waldron's test*, a similar active test where the patient squats while standing (Nijs et al 2006) (Tables 6.8, 6.9).

EXPERT OPINION	COMMENTS
★★★	<p>Step test</p> <p>Used frequently as it is a functional test and replicates what is usually the most painful activity for the patient.</p>

TABLE 6.8 STEP DOWN TEST

Author and year	LR+	LR–	Condition
Nijs et al 2006	2.34 ★	0.71	Patellofemoral pain syndrome

TABLE 6.9 WALDRON'S TEST

Author and year	LR+	LR–	Condition
Nijs et al 2006	1.05	0.99	Patellofemoral pain syndrome

A positive *vastus medialis coordination test* was found to indicate a small but significant increase in the probability of patellofemoral pain syndrome (Nijs et al 2006). The patient lies with the knee flexed over the clinician's clenched fist and is asked to extend the knee while maintaining uniform pressure on the clinician's hand. A positive test is indicated by an uncoordinated contraction of the hip flexors/extensors, indicated by the patient pushing down or lifting away from the clinician's fist.

Patella apprehension test

Aka

Fairbank's apprehension test

Purpose

To detect instability/pain emanating from the patellofemoral articulation.

Technique

Patient position

Patient lying supine with the knee flexed to 30°.

Clinician position

Sitting on the edge of the couch with the patient's knee flexed over the clinician's thigh. Both thumbs are placed over the medial patella border.

Action

The patella is pushed laterally in a slow, controlled manner.

Positive test

The patient experiences pain and/or apprehension in anticipation of patella subluxation and usually attempts to contract the quadriceps to try to prevent further excursion.

Fig. 6.14 • Patella apprehension test.



Clinical context

Recurrent patella dislocation occurs most commonly among teenagers, who report symptoms of giving way, pseudolocking and pain. In addition to provocation testing, assessment of local and regional

TABLE 6.10 PATELLA APPREHENSION TEST

Author and year	LR+	LR–	Target condition
Magee 2008	2.26 ★	0.79	Patella instability

strength and stability, generalized ligament laxity, femoral anteversion, external tibial torsion, valgus deformity, patella alta and trochlear dysplasia may be required to determine any underlying predisposition to instability (Bulstrode et al 2002).

If the patient is very apprehensive, they may actively contract the quadriceps to prevent lateral excursion of the patella hindering a satisfactory test, and in this situation, assessment under anaesthesia has been advocated (Bulstrode et al 2002). The test has been evaluated under anaesthetic as part of a study examining the clinical and arthroscopic findings associated with patella dislocation (Sallay et al 1996). Only 39% of patients had a positive *patella apprehension test* in contrast to 83% exhibiting a moderate to large effusion and 70% with tenderness over the tissues on the posteromedial aspect of the knee. Arthroscopic findings of gross laxity of the patellofemoral joint were most notable when the test was performed in 70–80° of knee flexion and this would suggest that the sensitivity of the test may be improved if carried out in a greater degree of flexion (Malanga et al 2003).

Clinical tip

In a study evaluating diagnostic tests for patellofemoral pain (not instability), a positive *patella apprehension test* was reported to increase the probability of patellofemoral joint syndrome to a small but significant degree (Nijs et al 2006).

Patellofemoral grind test

Purpose

To elicit pain and/or apprehension emanating from the patellofemoral joint.

Technique

Patient position

Lying supine with the knee extended.

Clinician position

Using a pinch grip of the index finger and thumb of both hands, the superior and inferior poles of the patella are fixed.

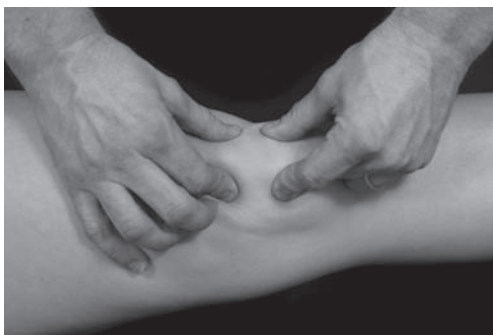Action

The patella is gradually compressed against the femur and moved inferiorly and superiorly, sliding the posterior surface of the patella against the femoral condyles.

Positive test

Reproduction of the patient's anterior knee pain.

Fig. 6.15 •
Patellofemoral grind test.



Clinical context

This test was originally used as a diagnostic test for chondromalacia patellae but subsequent studies have found little correlation between physical examination and arthroscopic findings of articular cartilage damage (Malanga et al 2003). It now has a wider application and is used, along with a number of others (see variations below), to assess symptoms stemming from the patellofemoral joint. Although there are no studies on this test in isolation, a poor correlation was noted when the clinical history and physical/X-ray findings were compared to subsequent arthroscopic findings in a small group of subjects with traumatic knee disorders. These combined examination findings yielded a sensitivity of only 37% for patients with chondromalacia patellae (O'Shea et al 1996).

Clinical tip

It is necessary to gauge carefully the amount of downward pressure that is applied during this test, as, if sufficient force is applied, it is possible to elicit pain in the healthiest of knees. Pressure should be

added gradually and comparison with the opposite side is always valuable to detect differences.

It is also important to monitor the patient's response to all these tests carefully as apprehension, with or without pain, is also considered to represent a positive finding.

EXPERT OPINION	COMMENTS
★★★	Patellofemoral grind test Commonly used for assessment of patellofemoral problems.

Variations

Clarke's test is performed with the patient lying with the knee extended and relaxed. The web of the clinician's hand is placed over the superior pole of the patella. The patient then contracts their quadriceps, forcing the patella upwards into the clinician's hand. As a slight variation, *Zohler's test* requires the clinician to use a pincer grip to pull the patella inferiorly to provide resistance to the superior excursion of the patella during contraction. These tests are often found to be painful in otherwise asymptomatic subjects and their usefulness is therefore limited. The patella grind test can be repeated in various degrees of knee flexion (*Fruend's sign*) to assess the integrity of different parts of the articular surface of the patella (Magee 2008).

E OTHER TESTS

Noble's compression test

Purpose

To detect the presence of iliotibial friction syndrome.

Technique

Patient position

Lying supine.

Clinician position

Standing on the side to be tested, the hip and knee are passively flexed to 90°.

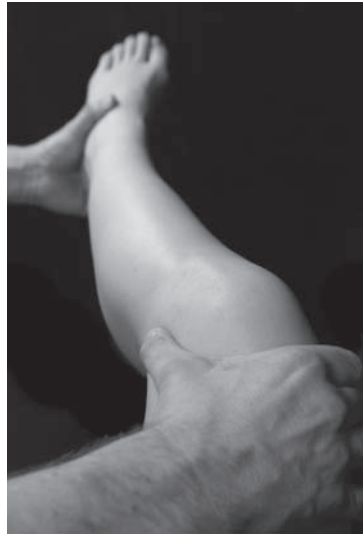Action

Using the cephalic thumb, pressure is applied over the lateral femoral condyle or slightly proximal to it (approximately 2–3 cm above the lateral knee joint line) and maintained while the knee is passively extended.

Positive test

The patient's lateral knee pain is reproduced when the knee reaches around 30° off full extension with tenderness under the pressure of the clinician's thumb. It may also be accompanied by crepitus.

Fig. 6.16 • Noble's compression test.



Clinical context

The Noble compression test aims to replicate the movement of the ITB over the femoral condyle which occurs during locomotion. As the knee moves from flexion into the last 30° of extension, the ITB moves forward over the lateral femoral condyle and if this movement is repeated excessively, particularly in the presence of predisposing factors such as ITB tightness, genu varum, overpronation and leg length discrepancy (symptoms tend to occur in the longer leg), the distal extent of the ITB and its underlying bursa can become inflamed (MacAuley 2007, Narvani et al 2006). Rapid increases in distance, hill

running or sudden changes to training schedules can precipitate the problem. Ober's test may also be positive (see p. 171).

Clinical tip

Given the iliotibial band is both a dynamic lateral stabilizer of the knee and contributes to active isotonic extension and flexion, some clinicians prefer to get the patient to actively extend the knee from about 40° as this is thought to put maximum stress on the band as it crosses over the condyle.

EXPERT OPINION	COMMENTS
★★	<p>Noble's compression test</p> <p>This is a useful test particularly in the differential diagnosis of lateral knee pain in athletes.</p>

Mediopatellar plica test

Aka

Mital–Hayden test

Purpose

To identify pain emanating from the medial patellar plica.

Technique

Patient position

Lying supine.

Clinician position

Standing on the side of the affected leg, the patient's knee is flexed to about 30° and supported over the clinician's knee. Both thumbs are placed over the lateral border of the patella.

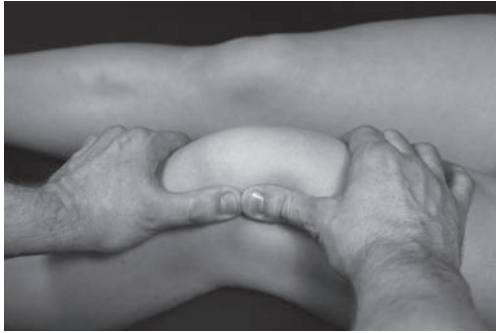Action

Firm pressure is applied with both thumbs to the patella, attempting to glide it medially.

Positive test

Reproduction of the pain is suggestive of an inflamed medial patellar plica.

Fig. 6.17 • Mediopatella plica test.



Clinical context

Plicae are folds of synovial tissue which are embryological in origin but which often persist into adult life, although they remain asymptomatic in most people. They are usually found around the margins of the patella – medially, superiorly and inferiorly (Hardaker et al 1980). The medial patellar plica has been estimated to be present in 19–70% of the population. It consists of approximately five folds lying between the medial border of the patella and the medial femoral condyle and is the most problematic (Abrahams & Kern 2001), causing impingement, usually between 40° and 80° of knee flexion. The suprapatellar plica lies in the suprapatellar pouch and the inferior plica, which despite being the largest is considered to be the least troublesome, lies anterior to the intercondylar notch inserting into the infrapatellar fat pad (Abrahams & Kern 2001).

There is no evidence on the accuracy of physical tests or other assessment methods for plica pathology although there is agreement that it can mimic classic meniscal symptoms, making the diagnosis difficult (Abrahams & Kern 2001, Saengnipanthkul et al 1992, Tindel & Nisonson 1992).

EXPERT OPINION	COMMENTS
★	<p>Mediopatellar plica test</p> <p>Plicae tests have the tendency to produce inaccuracies and the symptoms can be difficult to distinguish from medial meniscal pathology, so MRI is sometimes necessary to confirm plica involvement.</p>

Clinical tip

It is necessary to apply the glide medially as this squeezes the most commonly involved medial plica between the undersurface of the patella and the medial femoral condyle. The test can be reversed if the symptoms emanate from the lateral aspect. Other tests such as McMurray's (p. 215) and the patella apprehension tests (p. 224) may also be positive in the presence of a symptomatic medial plica (Abrahams & Kern 2001, Saengnipanthkul et al 1992) potentially leading to a false positive result.

In the symptomatic patient, tenderness and thickening may be found approximately 1 cm medial to the border of the patella over the medial femoral condyle

Variations

Hughston's plica test is performed with the patient lying supine, the knee is taken to 30° and the tibia internally rotated by the caudal hand. A medial glide is applied to the patella using the heel of the cephalic hand while the fingers palpate the medial border of the patella to feel for crepitus or a 'popping' sensation as the knee is passively moved between extension and flexion. This may or may not be accompanied by pain (Magee 2008).

The *plica stutter test* has the patient sitting with both knees flexed over the side of the couch. The margins of the patella on the affected knee are palpated to detect any sudden jump or 'stutter' as the knee is actively extended from a flexed position. This usually occurs in the mid-range (Magee 2008).

To test the *suprapatellar plica*, the patient lies supine and the knee is passively flexed with the tibia internally rotated. The patella is palpated on the medial aspect for a 'pop' which may indicate a symptomatic suprapatellar plica (Abrahams & Kern 2001).

References

- Abrahams, S., Kern, J.H., 2001. Anterior knee pain: plica syndrome, the forgotten pathology? *Physiotherapy* 87 (10), 523–528.
- Akseki, D., Ozcan, O., Boya, H., et al., 2004. A new weight bearing test and a comparison with McMurray's test and joint line tenderness. *Arthroscopy* 20 (9), 951–958.
- Anderson, A.F., Rennirt, G.W., Standeffer, W.C., 2000. Clinical analysis of the pivot shift tests: description of the pivot drawer test. *Am. J. Knee Surg.* 13 (1), 19–23.

- Bahk, M.S., Cosgarea, A.J., 2006. Physical examination and imaging of the lateral collateral ligament and posterolateral corner of the knee. *Sports Med. Arthrosc.* 14 (1), 12–19.
- Baker, C.L., Norwood, L.A., Hughston, J.C., 1983. Acute posterolateral rotatory instability of the knee. *J. Bone Joint Surg. Am.* 65 (5), 614–618.
- Benjaminse, A., Gokeler, A., Van der Schans, C.P., 2006. Clinical diagnosis of an anterior cruciate ligament rupture: a meta-analysis. *J. Orthop. Sports. Phys. Ther.* 36 (5), 267–288.
- Boeree, N.R., Ackroyd, C.E., 1991. Assessment of the menisci and cruciate ligaments: an audit of clinical practice. *Injury* 22, 291–294.
- Bulstrode, C., Buckwalter, J., Carr, A., et al., 2002. *Oxford Textbook of Orthopaedics and Trauma*. Oxford University Press, Oxford.
- Cooper, D.E., 1991. Tests for posterolateral instability of the knee in normal subjects: results of examination under anesthesia. *J. Bone Joint Surg. Am.* 73 (1), 30–36.
- Dervin, G.F., Stiell, A.G., Wells, G.A., 2001. Physicians' accuracy and interrater reliability for the diagnosis of unstable meniscal tears in patients having osteoarthritis of the knee. *Can. J. Surg.* 44 (4), 267–274.
- Donaldson, W.F., Warren, R.F., Wickiewicz, T., 1985. A comparison of acute anterior cruciate ligament examinations: initial versus examination under anesthesia. *Am. J. Sports Med.* 13 (1), 5–10.
- Evans, P.J., Bell, G.D., Frank, C., 1993. Prospective evaluation of the McMurray test. *Am. J. Sports Med.* 21 (4), 604–608.
- Fowler, P.J., Lubliner, J.A., 1989. The predictive value of five clinical signs in the evaluation of meniscal pathology. *Arthroscopy* 5 (3), 184–186.
- Frobell, R.B., Lohmander, L.S., Roos, H.P., 2007. Acute rotational trauma to the knee: poor agreement between clinical assessment and magnetic resonance imaging findings. *Scand. J. Med. Sci. Sports* 17 (2), 109–114.
- Hardaker, W.T., Whipple, T., Bassett, F., 1980. Diagnosis and treatment of plica syndrome of the knee. *J. Bone Joint Surg. Am.* 66, 221–226.
- Hewett, T.E., Noyes, F.R., Lee, M.D., 1997. Diagnosis of complete and partial cruciate ligament ruptures: stress radiography compared with KT-1000 arthrometer and posterior drawer testing. *Am. J. Sports Med.* 25 (5), 648–655.
- Hughston, J.C., Norwood, L.A., 1980. The posterolateral drawer test and external rotational recurvatum test for posterolateral rotatory instability of the knee. *Clin. Orthop. Relat. Res.* 147, 82–87.
- Hughston, J.C., Andrews, J.R., Cross, M.J., et al., 1976. Classification of knee ligament instabilities. Part II: the lateral compartment. *J. Bone Joint Surg. Am.* 58 (2), 173–179.
- Jackson, J.L., O'Malley, P.G., Kroenke, K., 2003. Evaluation of acute knee pain in primary care. *Ann. Intern. Med.* 139, 575–588.
- Karachalios, T., Hantes, M., Zibis, A.H., et al., 2005. Diagnostic accuracy of a new clinical test (the Thessaly test) for early detection of meniscal tears. *J. Bone Joint Surg.* 87 (5), 955–962.
- Katz, J.W., Fingerhuth, R.J., 1986. The diagnostic accuracy of ruptures of the anterior cruciate ligament comparing the Lachman test, the anterior drawer sign,

- and the pivot shift test in acute and chronic knee injuries. *Am. J. Sports Med.* 14 (1), 88–91.
- Kesson, M., Atkins, E., 2005. *Orthopaedic Medicine: a Practical Approach*, second edn. Butterworth Heinemann, Edinburgh.
- Kim, S.J., Kim, H.K., 1995. Reliability of the anterior drawer test, the pivot shift test, and the Lachman test. *Clin. Orthop. Relat. Res.* 317, 237–242.
- Kocabay, Y., Tetik, O., Isbell, W., et al., 2004. The value of clinical examination versus magnetic resonance imaging in the diagnosis of meniscal tears and anterior cruciate ligament rupture. *Arthroscopy* 20 (7), 696–700.
- LaPrade, R.F., Terry, G.C., 1997. Injuries to the posterolateral aspect of the knee: association of anatomic injury patterns with clinical instability. *Am. J. Sports Med.* 25 (4), 433–438.
- LaPrade, R.F., Wentorf, F., 2002. Diagnosis and treatment of posterolateral knee injuries. *Clin. Orthop. Relat. Res.* 402, 110–121.
- Larsen, M.W., Toth, A., 2005. Examination of posterolateral corner injuries. *J. Knee Surg.* 18 (2), 146–150.
- Lee, J.K., Yao, L., Phelps, C.T., et al., 1988. Anterior cruciate ligament tears: MR imaging compared with arthroscopy and clinical tests. *Radiology* 166 (3), 861–864.
- Lerat, J.L., Moyon, B.L., Cladiere, F., et al., 2000. Knee instability after injury to the anterior cruciate ligament: quantification of the Lachman test. *J. Bone Joint Surg. Am.* 82 (1), 42–47.
- Liu, S.H., Osti, L., Henry, M., et al., 1995. The diagnosis of acute complete tears of the anterior cruciate ligament. *J. Bone Joint Surg. Am.* 77B, 586–588.
- MacAuley, D., 2007. *Oxford Handbook of Sport and Exercise Medicine*. Oxford University Press, Oxford.
- McMurray, T.P., 1942. The semilunar cartilages. *Br. J. Surg.* 29, 407–414.
- Magee, D.J., 2008. *Orthopaedic Physical Assessment*, fifth edn. Saunders, Philadelphia.
- Malanga, G.A., Andrus, S., Nadler, S.F., et al., 2003. Physical examination of the knee: a review of the original test description and scientific validity of common orthopaedic tests. *Arch. Phys. Med. Rehabil.* 84 (4), 592–603.
- Miller, G.K., 1996. A prospective study comparing the accuracy of the clinical diagnosis of meniscus tear with magnetic resonance imaging and its effect on clinical outcome. *Arthroscopy* 12 (4), 406–413.
- Narvani, A.A., Thomas, P., Lynn, B., 2006. *Key Topics in Sports Medicine*. Routledge, London.
- Nijs, J., Van Geel, C., Van der Auwera, C., et al., 2006. Diagnostic value of five clinical tests in patellofemoral pain syndrome. *Man. Ther.* 11, 69–77.
- O'Shea, K.J., Murphy, K.P., Heekin, R.D., et al., 1996. The diagnostic accuracy of history, physical examination, and radiographs in the evaluation of traumatic knee disorders. *Am. J. Sports Med.* 24, 164–167.
- Ostrowski, J.A., 2006. Accuracy of 3 diagnostic tests for anterior cruciate ligament tears. *J. Athl. Train.* 41 (1), 120–121.

- Rose, N.E., Gold, S.M., 1996. A comparison of accuracy between clinical examination and magnetic resonance imaging in the diagnosis of meniscal and anterior cruciate ligament tears. *Arthroscopy* 12 (4), 398–405.
- Rubenstein, R.A., Shelbourne, K.D., McCarroll, J.R., et al., 1994. The accuracy of the clinical examination in the setting of posterior cruciate injuries. *Am. J. Sports Med.* 22 (4), 550–557.
- Ryzewicz, M., Peterson, B., Siparsky, P.N., et al., 2007. The diagnosis of meniscus tears: the role of MRI and clinical examination. *Clin. Orthop. Relat. Res.* 455, 123–133.
- Saengnipanthkul, S., Sirichativapee, W., Kowsuwon, W., et al., 1992. The effects of medial patellar plica on clinical diagnosis of medial meniscal lesion. *J. Med. Assoc. Thai.* 75 (12), 704–708.
- Sallay, P.I., Poggi, J., Speer, K.P., et al., 1996. Acute dislocation of the patella: a correlative pathoanatomic study. *Am. J. Sports Med.* 24 (1), 52–60.
- Scholten, R.J., Deville, W.L., Opstelten, W., 2001. The accuracy of physical diagnostic tests for assessing meniscal lesions of the knee. *J. Fam. Pract.* 50 (11), 938–942.
- Scholten, R.J., Opstelten, W., Van der Plas, C.G., et al., 2003. Accuracy of physical diagnostic tests for assessing ruptures of the anterior cruciate ligament: a meta-analysis. *J. Fam. Pract.* 52 (9), 689–694.
- Slocum, D.B., Larson, R.L., 1968. Rotatory instability of the knee. *J. Bone Joint Surg. Am.* 50, 211–225.
- Solomon, D.H., Simel, D.L., Bates, D.W., et al., 2001. The rational clinical examination. Does this patient have a torn meniscus or ligament of the knee? Value of the physical examination. *J. Am. Med. Assoc.* 286 (13), 1610–1620.
- Tindel, N., Nisonson, B., 1992. The plica syndrome. *Orthop. Clin. North. Am.* 23 (4), 613–618.
- Torg, J.S., Conrad, W., Kalen, V., 1976. Clinical diagnosis of anterior cruciate ligament instability in the athlete. *Am. J. Sports Med.* 4 (2), 84–93.
- Yoon, Y.S., Rah, J.H., Park, H.J., 1997. A prospective study of the accuracy of clinical examination evaluated by arthroscopy of the knee. *Int. Orthop.* 21 (4), 223–227.

ANKLE AND FOOT

A	LIGAMENT STRESS TESTS	236
	Anterior talofibular ligament stress test	236
	Calcaneofibular ligament stress test	238
	Calcaneocuboid ligament stress test	240
	Medial collateral ligament stress test	242
B	LIGAMENT INSTABILITY TESTS	244
	External rotation stress test	244
	Talar tilt test	248
	Drawer test	250
C	OTHER TESTS	255
	Thompson's test	255
	Peroneal subluxation test	257
	Metatarsal squeeze test	259

A LIGAMENT STRESS TESTS

Anterior talofibular ligament stress test

Aka

Plantarflexion/inversion stress test

Purpose

To stress the anterior talofibular ligament (ATFL) in order to detect a grade I/II sprain.

Technique

Patient position

Long sitting on the couch.

Clinician position

One hand cups the calcaneum (right ankle/right hand and vice versa), the other hand is wrapped around the dorsum of the foot, ensuring that the medial border of the hand is positioned over the talus in order to localize stress on the ligament effectively.

Action

The calcaneum is tilted into a plantarflexed position. The upper hand then gradually adds further plantarflexion and inversion (see Fig 7.1).

Positive test

Pain over the lateral aspect of the ankle and/or limited range. Assuming that the ligament is intact, the extent of pain and limitation depends on the acuteness of the injury and its severity.

Clinical context

The ATFL is the most important lateral stabilizer of the ankle and the most frequently injured (Tohyama et al 1995, Trojian & McKeag 1998, Wolfe et al 2001). With the foot in a neutral position, the fibula-ATFL angle is around 90° (i.e. the ligament runs approximately parallel to the sole of the foot) but plantarflexion brings it increasingly parallel to the long axis of the fibula where it functions as the main collateral ligament (Bahr et al 1997). In increasing degrees of plantarflexion and inversion, strain of the ATFL increases, more so than the calcaneofibular ligament (CFL), thereby rendering the ATFL most vulnerable in this position (Bahr et al 1997, Colville et al 1990). The posterior talofibular ligament is the strongest of the



Fig. 7.1 • Anterior talofibular ligament stress test.

lateral complex and is only injured in a severe inversion sprain (Wolfe et al 2001).

While careful physical examination has been shown to be a valuable tool in the detection of ankle fracture (see clinical tip; Stiell et al 1994), accurate evaluation of ligament injury is more difficult (Fujii et al 2000, Van Dijk et al 1996). Isolated tears do not tend to produce significant instability and pain is usually the dominant finding on stress testing. If the trauma is more severe and accompanied by swelling and bruising, instability testing should be performed (i.e. drawer test, p. 250, and talar tilt test, p. 248) with the index of suspicion high of a double rupture of the ATFL and the CFL, if positive (Bahr et al 1997).

Clinical tip

Leaving the pain and swelling to settle for a few days has been shown to be advantageous in improving the diagnostic accuracy of ligament injury at the ankle (Van Dijk et al 1996).

The widely accepted Ottawa rules for radiographic examination post ankle trauma have been found to produce a very low rate of false negatives and a sensitivity of 100%, reducing the number of ankle X-rays by about 35% (Stiell et al 1992). A subsequent larger

trial confirmed these findings (Stiell et al 1994) which led to effective implementation at multiple centres (Stiell et al 1995). The Ottawa rules (Duckworth et al 2009) state that:

An *ankle* X-ray is only required if there is:

- 1 bony tenderness over the distal 6 cm of the posterior edge or tip of the lateral and/or medial malleolus
- 2 an inability to weight-bear immediately following trauma or/and an inability to walk four steps when examined.

A *foot* X-ray is required if there is:

- 1 pain in the mid-foot zone
- 2 bony tenderness at the base of the navicular or fifth metatarsal
- 3 an inability to weight-bear immediately following trauma or/and an inability to walk four steps when examined.

EXPERT OPINION	COMMENTS
★★★	<p>ATFL stress test</p> <p>An extremely useful test to preferentially stress the ATFL but more valuable once the acute stage has passed and sufficient plantarflexion is available. This can also be used as a global lateral ligament stress test.</p>

Calcaneofibular ligament stress test

Aka

Inversion stress test

Purpose

To stress the calcaneofibular ligament (CFL) in order to detect a grade I/II sprain.

Technique

Patient position

Long sitting on the couch.

Clinician position

The calcaneum is cupped by one hand (right foot/left hand and vice versa) while the other hand wraps over the dorsum of the foot,

the fingers positioned over the lateral talar dome and the thumb supporting the sole of the foot.

Action

The foot is taken into plantargrade – the talus should not be in the close-packed position. The hand cupping the calcaneum provides a firm varus stress and the range of talar motion can be assessed by palpation.

Positive test

Pain over the lateral aspect of the ankle and/or limited range with no laxity is suggestive of a grade I/II sprain. The extent of pain and limitation depends on the acuteness of the injury and its severity.



Fig. 7.2 • Calcaneofibular ligament stress test.

Clinical context

This test is exactly the same as the manoeuvre described at the talar tilt test but with the emphasis on the detection of minor ligamentous injury rather than ankle instability (see talar tilt, p. 248). With the foot in the neutral position, the CFL forms a posterior angle of about 130° with the fibula, but with the foot in dorsiflexion the

ligament becomes parallel to the axis of the fibula, thereby functioning as a collateral ligament. As a result, the ligament is under most stress in dorsiflexion and inversion while its lateral companion, the anterior talofibular ligament (ATFL), provides little restraint in this position (Bahr et al 1997, Colville et al 1990). With the reverse occurring in plantarflexion and inversion, it is clear that the ATFL and CFL function together in all positions of ankle flexion to provide lateral ankle stability (Colville et al 1990).

Calcaneocuboid ligament stress test

Purpose

To stress the calcaneocuboid ligament (CCL) in order to detect a grade I/II sprain.

Technique

Patient position

Long sitting on the couch.

Clinician position

One hand cups the calcaneum (right ankle/right hand and vice versa), the other hand is wrapped around the dorsum of the foot, ensuring that the medial border of the hand is positioned just below the calcaneocuboid joint line.

Action

The calcaneum is fixed in a neutral position while the other hand applies a combined movement of adduction and inversion of the forefoot (see Fig. 7.3).

Positive test

Pain over the lower, lateral aspect of the ankle and/or limited range, the extent of which depends on the acuteness of the injury and its severity.

Clinical context

The CCL is composed of the dorsal CCL ligament (a thickening of the fibrous capsule on the dorsal surface of the joint) and the CCL component of the bifurcate ligament (Standring 2005). Compared to the prevalence of anterior talofibular ligament (ATFL) injury,



Fig. 7.3 • Calcaneocuboid ligament stress test.

the CCL is much less commonly involved in ankle sprains. It can either be injured in isolation, where the forefoot is exposed to forced inversion and adduction while the calcaneus is relatively fixed and stable, or as a combined lesion resulting from gross lateral strain. In ankle sprains, the ATFL, calcaneofibular ligament and the CCL can all be involved and the ligaments should always be tested for pain *and* laxity (i.e. ATFL stress test, p. 236; drawer test, p. 250; talar tilt test, p. 248). If the CCL is involved as part of a combined sprain, the ATFL is most likely to be its injured partner.

Clinical tip

The calcaneum must be held in neutral or slight eversion to keep stress off the ATFL and CFL and ensure most of the stress falls on the CCL.

The calcaneocuboid joint line can be found by placing the side of the thumb up against the base of the fifth metatarsal where the joint will be approximately in line with the midpoint of the thumb pad. It is important to ensure that the hand is positioned just distal to the joint line in order to localize stress on the ligament effectively.

EXPERT OPINION	COMMENTS
★★	<p>CCL stress test</p> <p>The CCL is often missed as a component of a lateral complex sprain and this test permits more specific localisation.</p>

Medial collateral ligament stress test

Purpose

To stress the medial collateral (deltoid) ligament in order to detect a grade I/II sprain and/or laxity.

Technique

Patient position

Long sitting on the couch.

Clinician position

One hand cups the calcaneum (right ankle/left hand and vice versa). The other hand is wrapped around the dorsum of the foot from the medial side, ensuring that the hand is positioned quite proximally (the medial edge of the hand resting over the navicular) in order to avoid stress falling primarily on the forefoot.

Action

The calcaneum is tilted into a valgus position while the upper hand gradually adds eversion in a degree of dorsiflexion (see Fig. 7.4).

Positive test

Pain over the medial aspect of the ankle and/or laxity is elicited as the stress is added. Mild or chronic cases may report minor discomfort at the end of the movement.

Clinical context

The medial ligament is a very strong fan-shaped structure (composed of the tibionavicular, tibiocalcaneal, anterior and posterior tibiotalar ligaments) which limits eversion of the ankle and lateral displacement of the talus. It is made up of superficial bands which are mainly vertically orientated, limiting rear foot eversion, and deeper fibres, more transverse in direction, which limit abduction/external rotation of the talus (Placzek & Boyce 2006). Its strength is demonstrated by the fact that the malleolus often fractures before



Fig. 7.4 • Medial collateral ligament stress test.

the ligament ruptures – 75% of ankle fractures occur on the medial side. Conversely, medial ligament injury represents only 10% of ankle sprains (Trojian & McKeag 1998) and this is attributed to the enhanced medial stability afforded by the mortise of the ankle, the articulation between the medial malleolus and talus and the anterior tibiofibular ligament, all of which make injury much less likely than on the lateral side (Wolfe et al 2001).

Injury to the medial ligament will be evident by the mechanism of injury (excessive eversion with the foot in a neutral or slightly dorsiflexed position), local tenderness, swelling and a positive medial ligament test. If significant trauma has occurred other injuries should also be considered such as a syndesmosis injury (see external rotation stress test, p. 244) or fracture, i.e. Maisonneuve fracture (proximal fibula), distal fibular fracture or avulsion fracture of the medial malleolus (Trojian & McKeag 1998) requiring further evaluation (see Ottawa rules, p. 238) and possible surgical intervention.

Clinical tip

The medial ligament is also vulnerable to chronic strain resulting from poor foot biomechanics. A valgus rear foot and associated

pronation of the forefoot will produce medial forces that, if left uncorrected, may lead to chronic strain on both the medial and spring ligaments. The stress test may well reveal some discomfort at the extreme of the movement and, if very established, a small degree of laxity may be evident. Because this is usually a bilateral problem, making a comparison with the 'normal' side is not always possible.

EXPERT OPINION	COMMENTS
★★	<p>MCL stress test</p> <p>Primarily evaluates the superficial fibres, which are more commonly involved in bio-mechanical overloading and minor injury.</p>

B LIGAMENT INSTABILITY TESTS

External rotation stress test

Aka

Kleiger's test

Purpose

To assess the integrity of the inferior tibiofibular syndesmosis.

Technique

Patient position

Sitting on the side of the couch with the knees flexed to 90°.

Clinician position

The examiner grasps the heel (right ankle/right hand and vice versa) and rests the anterior aspect of the forearm against the medial border of the foot. The foot is positioned in plantargrade. The other hand stabilizes the lower thigh.

Action

A passive external rotation stress is applied to the ankle.

Positive test

The test is positive for a syndesmosis injury if pain is reproduced over the inferior tibiofibular joint.

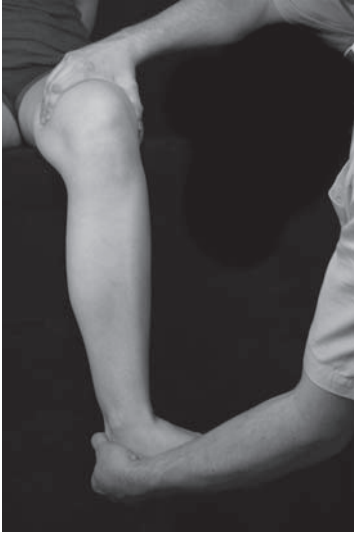

Fig. 7.5 • External rotation stress test.

Clinical context

The syndesmosis is stabilized by the interosseous membrane and the anterior and posterior inferior tibiofibular, transverse tibiofibular and interosseous ligaments. Syndesmosis injuries (commonly known as 'high ankle sprains') account for about 10% of ankle sprains and are most prevalent in contact sports. This injury, in contrast to lateral ligament sprain, does not present with significant swelling, nor is recurrence common (Trojian & McKeag 1998), although the degree of disability that can follow injury requires careful evaluation and a different management strategy (Wolfe et al 2001).

Syndesmotic injuries of the ankle without fractures can result from external rotation, eversion and dorsiflexion injuries (Wolfe et al 2001). A cadaveric study showed that forced external rotation of the ankle resulted in significant disruption to the inferior tibiofibular joint (Beumer et al 2006). When dorsiflexion is added the anterior tibiofibular ligament is under greatest duress and is most likely to rupture in this position, leaving the mortise of the ankle significantly undermined and mechanically unstable (Beumer et al 2006,

Colville et al 1990). The stress on the posterior tibiofibular ligament in this position is less and, because it is also mechanically stronger, is least likely to rupture (Colville et al 1990). It takes forceful 'hyperdorsiflexion' to expose this ligament to the possibility of significant injury. Combined rupture of both anterior and posterior tibiofibular ligaments, particularly when the anterior band of the deltoid ligament is also involved, creates gross instability (Beumer et al 2006).

This is not a definitive test and should always be used in combination with other findings to establish the extent of the injury. Where instability is suspected MRI investigation provides a more conclusive assessment (Gaebler et al 1997). In the event of the lateral ligaments being intact, the talar tilt test can be used to assess the integrity of the syndesmosis (see talar tilt test, p. 248).

Clinical tip

Failure of the inferior tibiofibular ligaments can result in either substance rupture of the ligament (the dominant failure mode of the anterior tibiofibular ligament) or fibular avulsion (the failure mode for 50% of posterior tibiofibular ligament injuries). As rupture of the anterior tibiofibular ligament is mechanically more likely (see clinical context), the presence of an avulsion fracture should alert the clinician to the possibility of a double ligament injury as well (Beumer et al 2003).

If medial ankle pain is elicited during this test or excess anterior or anteromedial movement of the talus is detected, closer evaluation of the medial ligament should be undertaken.

Injury to the syndesmosis resulting in only a 1 mm lateral shift of the talus due to loss of mortise stability decreases the weight-bearing surface of the talus by 40%, a 3 mm shift by 60%, and a 5 mm shift by 80%, thereby generating an increase in contact pressures and accelerating degenerative changes (Placzek & Boyce 2006).

Variations

The *Cotton test/side-to-side test/Chalke test* positions the patient in the same way but uses both internal *and* external tibial rotation to stress the mortise.

Related tests

With the patient in long sitting, the *dorsiflexion manoeuvre* requires tension to be taken off the gastrocnemius and soleus complex by flexing the knee. The lower leg is stabilized with one hand over the lower leg and the calcaneum is grasped with the other, allowing the anterior aspect of the forearm to be positioned under the sole of the patient's

foot. The ankle is then passively dorsiflexed to end-range. If this is pain-free and no apprehension is detected, the manoeuvre is repeated more forcibly, looking to reproduce pain and/or apprehension (Magee 2008).

The *dorsiflexion compression test* is done in standing. The patient is asked to actively dorsiflex the ankle and report any pain while the examiner assesses the joint range. The test is then repeated with the examiner using both hands to squeeze the malleoli together (Fig. 7.6). The test is considered positive if the pain is reduced and/or dorsiflexion increased when the squeeze is added (Magee 2008).

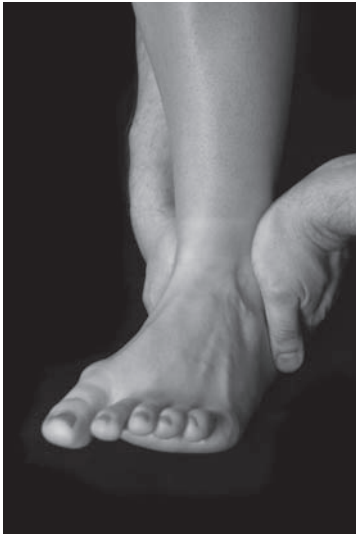

Fig. 7.6 • Dorsiflexion compression test in standing.

Other non-specific tests that can be used for injury to the syndesmosis include: the *crossed leg test* (Magee 2008) where pain around the syndesmosis is provoked when the patient crosses the affected leg so that the lower third of the fibula rests just above the opposite knee; the *heel thump test* (Magee 2008) where, with the patient in a sitting position, the examiner uses the fist to hit the centre of the heel while the other hand stabilizes the lower leg and the *squeeze test* (Wolfe et al 2001) where compression of both the tibia and fibula in the mid-calf region is considered positive if pain over the syndesmosis is elicited.

Talar tilt test

Purpose

The talar tilt test serves two main functions:

- 1 to test the integrity of the calcaneofibular ligament (CFL) and the anterior talofibular ligament (ATFL)
- 2 to assess the integrity of the inferior tibiofibular syndesmosis.

Technique

Patient position

Long sitting on the couch.

Clinician position

The calcaneum is cupped by one hand (right foot/left hand and vice versa) while the other hand wraps over the dorsum of the foot, the fingers positioned over the lateral talar dome and the thumb supporting the sole of the foot.

Action

The foot is taken into dorsiflexion, short of the close-packed position. The hand cupping the calcaneum provides a firm varus stress and the range of talar motion can be assessed by the other hand positioned over the talar dome (see Fig. 7.7).

Positive test

- 1 *For CFL/ATFL laxity*: increased excursion of the talus is suggestive of a combined rupture of the CFL and ATFL (see clinical context).
- 2 *For syndesmosis injury*: reproduction of high ankle pain, increased movement of the talus, apprehension and a painful clunk as the talus rotates in the widened mortise would all be indicative of syndesmosis disruption.

Clinical context

Injury to the CFL rarely occurs in isolation but it is vulnerable to inversion trauma and, if injured, will invariably be partnered by a torn ATFL. The ATFL takes the strain as the ankle moves into greater degrees of plantarflexion and inversion, while the CFL is most stressed when the talus is dorsiflexed and inverted (Bahr et al 1997). Essentially these two ligaments function together in all positions of ankle flexion to provide lateral stability (Colville et al 1990).



Fig. 7.7 • Talar tilt test.

With both ligaments torn, significant anterolateral instability ensues and both this test and the drawer test (see p. 250) are likely to be positive (Bahr et al 1997).

In an attempt to analyse the significance of varying degrees of increased talar movement, results of the test were compared with MRI investigation and findings at surgery (Gaebler et al 1997) as follows:

- $<5^\circ$ talar tilt: half were found to have no ligament damage and the rest had either single ATFL injury or a combined ATFL/CFL tear.
- $5\text{--}15^\circ$ talar tilt: a third had the combined ATFL/CFL rupture and an incomplete rupture of the posterior talofibular ligament; the rest had either double or single ruptures.
- $>25^\circ$ talar tilt: all had complete combined ATFL/CFL ruptures with either complete or partial ruptures of the posterior talofibular ligament reported.

While clinically useful to detect injury and laxity, the talar tilt test cannot therefore be regarded as an accurate tool for evaluating the exact *extent* of lateral ankle ligament injuries (Gaebler et al 1997, Van Dijk et al 1996, Wolfe et al 2001).

Involvement of the syndesmosis in ankle injury usually results from catastrophic ligamentous disruption (and fracture) but forced dorsiflexion/external rotation may cause an isolated injury (see external rotation stress test, p. 244). Disruption of the tibiofibular joint can lead to diastasis, rendering the mortise inherently unstable. The varus movement of the calcaneum during the talar tilt test, tensions the CFL (and ATFL) which in turn challenges the syndesmosis by pulling on the fibula and potentially widening the mortise enabling the talus to rotate excessively. It is essential, therefore, that the ATFL and CFL are intact if the test is being used for this purpose.

Clinical tip

A talar tilt of around 15° or more usually indicates a complete rupture of the ATFL and CFL (Gaebler et al 1997). The use of MRI has been advocated in cases where the talar tilt is between 5° and 20° (a lower threshold for imaging is recommended in the younger athlete) to determine the extent of injury before deciding on an appropriate management strategy (Gaebler et al 1997).

Drawer test

Aka

Positive 'suction' or 'dimple' sign

Purpose

To test the integrity of the anterior talofibular ligament (ATFL).

Technique

Patient position

The patient lies supine with the knee flexed and the foot resting on the couch.

Clinician position

Standing on the opposite side of the couch to the leg being tested. The webspace of the caudal hand is placed over the talus in order to provide stabilization during the test; the other hand is wrapped over the distal tibia and fibula so that the fingers are placed laterally and the thumb is over the medial malleolus, ensuring a clear view of the distal fibula is possible.

Action

Downward pressure is applied to fix the talus while the fibula and tibia are pushed backwards, observing the degree of posterior movement of the lateral malleolus.

Positive test

Increased posterior movement of the lateral malleolus is a positive sign and indicates laxity or rupture of the ATFL. This backward movement of the malleolus can result in a negative pressure which sometimes draws the adjacent skin in, producing the dimple or suction sign.

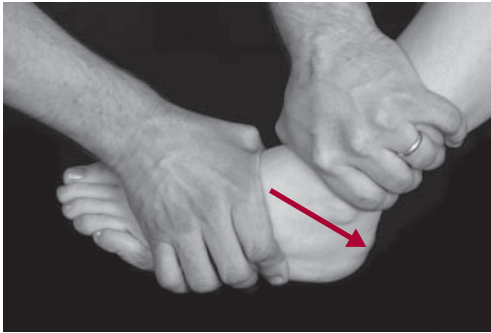


Fig. 7.8 • Drawer test. The arrow indicates the direction of tibial movement.

Clinical context

The most common mechanism of injury is a combination of plantarflexion and inversion where the ATFL and calcaneofibular ligaments (CFL) are particularly vulnerable. As the primary ligamentous restraint to forward subluxation of the talus, the ATFL is by far the most easily injured and rupture can result in a degree of instability, although concomitant injury to the CFL will amplify this significantly (see talar tilt test, p. 248) (Bahr et al 1997). The posterior talofibular ligament is the strongest of the lateral complex and is rarely injured in an inversion sprain (Wolfe et al 2001).

The drawer test is used to assess the integrity of the ATFL. In the event of a grade I sprain where no laxity is present, the ATFL stress test (p. 236) should be used to confirm injury.

The ATFL has been shown to be under greatest tension in 10–20° of plantarflexion (Bahr et al 1997, Colville et al 1990, Tohyama et al 1995) which, combined with 90° knee flexion, reduces soft tissue tension and largely removes the secondary restraint afforded by the gastrocnemius/Achilles complex (Kovaleski et al 2008), providing the ideal position to apply the test. The preferred choice by many clinicians, this version of the technique exposes stress on the ligament in the optimum position and reverses the conventional point of fixation where the tibia and fibula are fixed and the talus is drawn forwards – i.e. anterior drawer of the talus.

In the event of a combined ATFL and CFL rupture, the medial ligament acts as the centre of rotation during movement, allowing the talus to rotate internally – having lost its lateral restraints. Emphasizing the backward pressure over the fibula to deliver a slight rotational force may well improve the sensitivity of the test (Bahr et al 1997). Alternatively, if the ‘original’ test is performed, the foot should be pulled forwards and medially (Van Dijk 1996).

Both the sensitivity and specificity of the anterior drawer test have been called into question (Bahr et al 1997, Becker et al 1993, Lähde et al 1988), particularly when performed in the first day or two after injury (Van Dijk et al 1996). When the physical examination is performed by an experienced clinician at 5 days post trauma, the combination of a haematoma, pain on palpation and a positive anterior drawer test showed a high level of sensitivity and specificity for an ATFL tear compared to testing in the first 48 hours (Van Dijk et al 1996). The usefulness of further investigations and the attendant cost implications have therefore been questioned (Van Dijk et al 1996), although

TABLE 7.1 DRAWER TEST

Author and year	LR+	LR–	Target condition
Van Dijk et al 1996	6 ★★	0.05 ★★★	ATFL laxity 5 days post injury (physical examination including drawer test)
Van Dijk et al 1996	1.05	0.88	ATFL laxity <48 hours post injury (physical examination including drawer test)

in cases where physical examination has been unable to differentiate between isolated and combined tears, both MRI and arthrography are regarded as valuable methods of diagnosis (Gaebler et al 1997).

Clinical tip

Performing this test successfully requires the clinician to ensure that the patient is relaxed and that the force is applied gradually. A large amount of force is not necessary to achieve posterior translation of the lateral malleolus; indeed, lower forces have been shown to be more effective, as higher forces tend to elicit a protective muscle contraction which may mask a positive finding (Tohyama et al 2003).

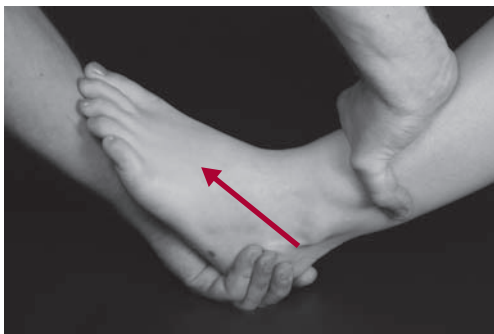In addition to lateral ligament damage following an inversion injury, patients sometimes also report *medial* ankle pain. Severe injury can evoke traumatic capsulitis of the subtalar joint where heel pain is accompanied by a loss of varus movement and a hard 'end-feel'. MRI evaluation also reveals high rates of bone bruising of the talus, probably explained by the pathomechanism of the inversion injury, where the medial malleolus is 'rammed' against the talus. This mechanism induces shear forces that may cause osteochondral lesions of the talar dome, a feature sometimes observed in the more severely injured ankle (Gaebler et al 1997).

EXPERT OPINION	COMMENTS
★★★	<p>Drawer test</p> <p>This test specifically evaluates the integrity of the ATFL. A double injury involving the CFL does not increase the amount of drawer excursion.</p>

Variations

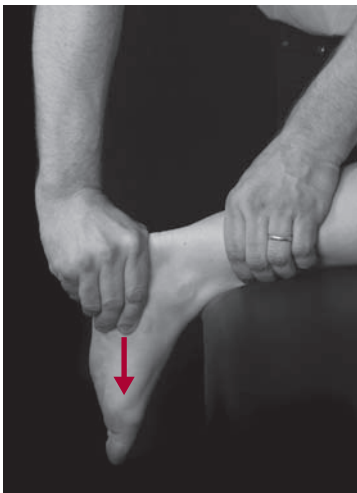The original test literally creates an *anterior drawer* of the talus. The patient lies supine with the knee flexed. Grasping the patient's heel with one hand, the ankle is held in about 10–20° of plantarflexion, allowing the sole of the foot to lie on the anterior surface of the examiner's forearm. The other hand fixes the distal end of the tibia in order to prevent anterior movement during the test. The patient must try to consciously relax the lower leg and foot before the test is performed in order to minimize the chance of a false negative finding. The heel is then pulled forward (Fig. 7.9). When a rupture of the ATFL is present, the lateral side of the talus translates forwards, essentially rotating partially out of the ankle mortise. The centre of rotation is created by the intact medial ligament (Magee 2008).

Fig. 7.9 • Anterior drawer test. The arrow indicates the direction of calcaneal movement.



The *anterior drawer test in prone* has the patient lying prone with the feet over the edge of the couch. The lower leg is fixed against the couch with one hand while the webspace of the other hand is positioned around the back of the calcaneum and a downward pressure is applied (Fig. 7.10). Excessive anterior movement indicates ligamentous laxity.

Fig. 7.10 • Prone anterior drawer test. The arrow indicates the direction of calcaneal movement.



C OTHER TESTS

Thompson's test

Aka

Simmonds' test

Squeeze test

Purpose

To detect the presence of a complete rupture of the Achilles tendon.

Technique

Patient position

The patient is positioned prone with their feet hanging over the edge of the couch.

Clinician position

The palm of the clinician's hand is positioned over the patient's calf at the point where the girth is widest, with the thumb on one side and fingers on the other.

Action

The clinician then opposes thumb and fingers to squeeze the calf (see Fig. 7.11).

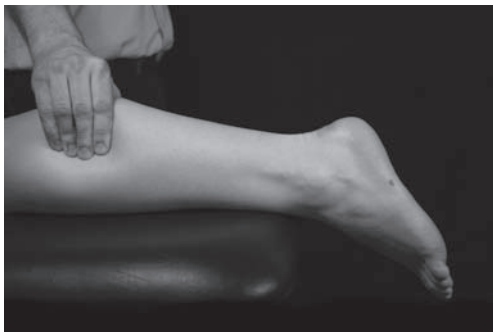Positive test

A lack of plantarflexion indicates a complete rupture. In a negative test where the tendon is intact, the ankle involuntarily plantarflexes. An inability to push-off during the normal gait cycle or get anywhere near a heel raise on the affected side would also be suggestive of a complete rupture. The loss of an intact Achilles tendon will be detectable when the ankle is passively dorsiflexed, particularly when the knee is held in extension, where the loss of soft tissue resistance will result in excessive movement and an altered end-feel. Normally a palpable gap in the tendon is also evident (Gross et al 2002).

Clinical context

Thompson's test is widely considered to be the 'gold standard' for detecting Achilles rupture (Placzek & Boyce 2006). The most common site for the injury is around the hypovascular section of the tendon, approximately 3–6 cm proximal to the insertion. Rupture is often seen in the older, deconditioned individual where there

Fig. 7.11 • Thompson's test indicating the normal response of plantarflexion when the calf is squeezed.



is a mismatch between demand and the tendon's ability to cope with forceful loading. The degenerative process reduces the tensile strength of the tendon (Maffuli et al 2005) and that, combined with sporadic and often sudden activity, makes the Achilles a vulnerable structure. It is also sometimes seen in the younger athlete who, having encountered prolonged inactivity resulting from another injury, then exposes the tendon to sudden, unaccustomed loading. The mechanism of injury is invariably rapid plantarflexion during full weight-bearing (i.e. jumping/landing or a sudden lunge during sport such as badminton or tennis). At the time of injury, the patient usually reports a severe, sharp pain around the heel although their lasting memory is of a loud 'crack' which feels like they have been hit from behind.

TABLE 7.2 THOMPSON'S TEST

Author and year	LR+	LR-	Target condition
Malanga & Nadler 2005	13.7 ★★★	0.04 ★★★	Complete rupture

Clinical tip

The test is only positive if the tendon is completely ruptured although some minor discrepancy in foot movement may be noted with a significant partial rupture (Scott & Al Chalabi 1992).

Additional tests

Matles' test can also be used to detect Achilles rupture. The patient lies prone with their foot over the edge of the couch. The patient is asked to flex the knee of the affected leg to 90°. The position of the foot is observed through the movement. With a normal Achilles, the foot gently moves into a degree of plantarflexion. If the foot falls into a neutral or slightly dorsiflexed position the test is considered to be positive. The test can also be performed passively in the case of the reluctant or anaesthetised patient. (See Table 7.3.)

TABLE 7.3 MATLES' TEST

Author and year	LR+	LR–	Target condition
Malanga & Nadler 2005	5.9 ★★	0.14 ★★	Complete rupture

Copeland's test has the patient lying prone with the knee flexed to 90°. A sphygmomanometer is positioned around the bulk of the calf and inflated to 100 mmHg with the ankle positioned in plantarflexion. The foot is then passively dorsiflexed. If the tendon is intact a rise in pressure to around 140 mmHg would be expected but only a flicker is elicited in the event of complete rupture. (See Table 7.4.)

TABLE 7.4 COPELAND'S TEST

Author and year	LR+	LR–	Target condition
Malanga & Nadler 2005	9.7 ★★	0.24 ★	Complete rupture

Peroneal subluxation test

Purpose

To detect subluxation/dislocation of the peroneus brevis and longus tendons as they travel behind the lateral malleolus.

Technique

Patient position

Long sitting on a couch.

Clinician position

The clinician palpates over the peroneal tendons as they pass behind the lateral malleolus.

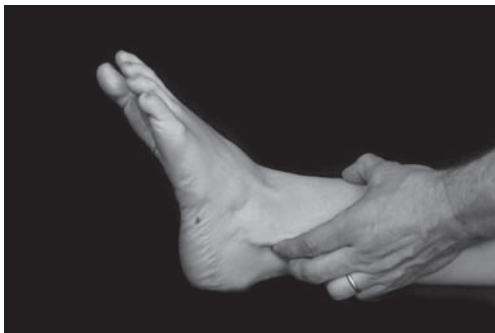Action

The patient is asked to actively dorsiflex and evert the affected foot.

Positive test

The clinician will feel the tendon sublux or snap out of position and/or the manoeuvre will elicit pain.

Fig. 7.12 • Peroneal subluxation test.



Clinical context

The peroneus longus and brevis tendons lie in a shallow groove (retromalleolus sulcus) behind the lateral malleolus of the fibula where they are contained by the bone anteriorly and the retinaculum laterally. Relatively common among skiers, the mechanism of injury is usually a forceful dorsiflexion/eversion movement of the foot combined with a strong reflex contraction of the peroneal muscles (Placzek & Boyce 2006). Fracture of the posterior edge of the fibula can also result in instability of the tendons.

Patients typically report lateral pain behind the malleolus when walking and this may become more pronounced when they walk on their heels (Trojian & McKeag 1998). A history of locking is also often described and if combined with the other findings the diagnosis is almost certain. The tendon most likely to sublux is peroneus brevis and although both tendons can dislocate, the longus never does in isolation. If left untreated, the subluxation can become recurrent and lead to tears of the brevis tendon.

Clinical tip

An acutely subluxed tendon can masquerade as an ankle sprain as the mechanism of injury and site of the pain may appear similar at first. The presence of swelling posterior to the lateral malleolus, pain on both resisted isometric eversion in dorsiflexion and passive ankle plantarflexion/inversion, along with and a 'snapping' sensation on movement, is strongly suggestive of peroneal instability (Placzek & Boyce 2006).

In the acute stages particularly, pain may inhibit an adequate peroneal contraction which could lead to a false negative conclusion.

EXPERT OPINION	COMMENTS
★★★	<p>Peroneal subluxation test</p> <p>As well as the typical mechanism of injury, forced inversion with an associated reflex peroneal contraction can also result in injury to the retinaculum and lead to peroneal instability.</p>

Metatarsal squeeze test

Aka

Morton's test

Purpose

To detect a Morton's neuroma on the intermetatarsal plantar digital nerve.

Technique

Patient position

Long sitting on the couch.

Clinician position

The medial and lateral aspects of the forefoot are grasped using one hand.

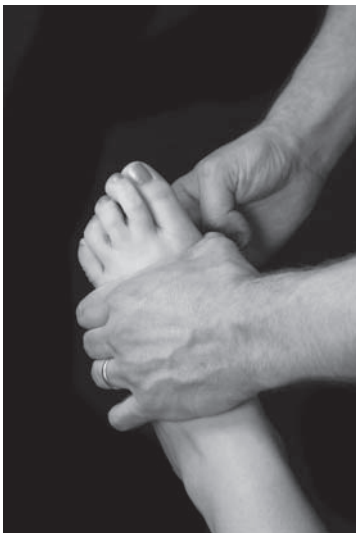Action

The medial and lateral aspects are squeezed together with one hand and the area of tenderness palpated with the other.

Positive test

Provocation of the pain.

Fig. 7.13 • Metatarsal squeeze test with palpation of the tender area between the metatarsal heads on the plantar aspect of the foot.



Clinical context

Neuromas are thought to result from irritation of the intermetatarsal plantar digital nerve as it travels under the metatarsal ligament. Poorly fitting footwear is commonly blamed for the symptoms and the patient reports a deep, localized 'burning' pain in the plantar aspect of the forefoot which is sometimes accompanied by localized paraesthesiae extending into the toe. Commonly neuromas are found in the space between the third and fourth metatarsals and are rare between the first and second and the fourth and fifth. Palpation in the webspace over the neuroma is also commonly tender (Placzek & Boyce 2006).

Clinical tip

An audible or palpable click can sometimes be elicited by gliding the two metatarsals in question in a dorsal and plantar direction while applying the compression. This is thought to occur as a

result of the neuroma catching between the metatarsals while under compression and is more likely where the condition is advanced or established. This is known as *Mulder's sign* (Gross et al 2002, Malanga & Nadler 2005). Though fascinating for the clinician, the test is uncomfortable for the patient and should not be repeated unnecessarily.

An accessory sign is pain elicited by metatarsophalangeal joint extension which tightens the ligament and increases compression on the nerve (Placzek & Boyce 2006).

References

- Bahr, R., Pena, F., Shine, J., et al., 1997. Mechanics of the anterior drawer and talar tilt tests: a cadaveric study of lateral ligament injuries of the ankle. *Acta Orthop. Scand.* 68 (5), 435–441.
- Becker, H.P., Komischke, A., Danz, B., et al., 1993. Stress diagnostics of the sprained ankle: evaluation of the anterior drawer test with and without anaesthesia. *Foot Ankle* 14 (8), 459–464.
- Beumer, A., Van Hemert, W.L., Swierstra, B.A., et al., 2003. A biomechanical evaluation of the tibiofibular and tibiotalar ligaments of the ankle. *Foot Ankle Int.* 24 (5), 426–429.
- Beumer, A., Valstar, E.R., Garling, E.H., et al., 2006. Effects of ligament sectioning on the kinematics of the distal tibiofibular syndesmosis: a radiostereometric study of 10 cadaveric specimens based on presumed trauma mechanisms with suggestions for treatment. *Acta Orthop. Scand.* 77 (3), 531–540.
- Colville, M.R., Marder, R.A., Boyle, J.J., et al., 1990. Strain measurement in lateral ankle ligaments. *Am. J. Sports Med.* 18 (2), 196–200.
- Duckworth, A.D., Porter, D.E., Ralston, S.H., 2009. *Orthopaedics, Trauma and Rheumatology*. Churchill Livingstone, London.
- Fujii, T., Luo, Z.P., Kitaoka, H.B., et al., 2000. The manual stress test may not be sufficient to differentiate ankle ligament injuries. *Clin. Biomech.* 15 (8), 619–623.
- Gaebler, C., Kukla, C., Breitenseher, M.J., et al., 1997. Diagnosis of lateral ankle ligament injuries: comparison between talar tilt, MRI and operative findings in 112 athletes. *Acta Orthop. Scand.* 68 (3), 286–290.
- Gross, J., Fetto, J., Rosen, E., 2002. *Musculoskeletal Examination*, second ed. Wiley-Blackwell, Chichester.
- Kovaleski, J.E., Norrel, P.M., Heitman, R.J., et al., 2008. Knee and ankle position, anterior drawer laxity, and stiffness of the ankle complex. *J. Athl. Train.* 43 (3), 242–248.
- Lähde, S., Putkonen, M., Puranen, J., et al., 1988. Examination of the sprained ankle: anterior drawer test or arthrography? *Eur. J. Radiol.* 8 (4), 255–257.
- Maffuli, N., Renström, P., Leadbetter, W.B., 2005. *Tendon Injuries: Basic Science and Clinical Medicine*. Springer-Verlag, London.

- Magee, D.J., 2008. *Orthopaedic Physical Assessment*, fifth ed. Saunders, Philadelphia.
- Malanga, G.A., Nadler, S., 2005. *Musculoskeletal Physical Examination: An Evidence-Based Approach*. Elsevier Health Sciences, Philadelphia.
- Placzek, J.D., Boyce, D.A., 2006. *Orthopaedic Physical Therapy Secrets*, second ed. Elsevier Health Sciences, Missouri.
- Scott, B., Al Chalabi, A., 1992. How the Simmonds–Thompson test works. *J. Bone Joint Surg. Br.* 74 (2), 314–315.
- Standing, S., 2005. *Gray's Anatomy*, thirty-ninth ed. Elsevier Churchill Livingstone, Edinburgh.
- Stiell, I.G., Greenberg, G.H., McKnight, R.D., et al., 1992. A study to develop clinical decision rules for the use of radiography in acute ankle injuries. *Ann. Emerg. Med.* 21 (4), 384–390.
- Stiell, I.G., McKnight, R.D., Greenberg, G.H., et al., 1994. Implementation of the Ottawa ankle rules. *JAMA* 271 (11), 827–832.
- Stiell, I., Wells, G., Laupacis, A., et al., 1995. Multicentre trial to introduce the Ottawa ankle rules for use of radiography in acute ankle injuries. Multicentre Ankle Rule Study Group. *Br. Med. J.* 2, 594–597.
- Tohyama, H., Beynnon, B.D., Renström, P.A., et al., 1995. Biomechanical analysis of the ankle anterior drawer test for anterior talofibular ligament injuries. *J. Orthop. Res.* 13 (4), 609–614.
- Tohyama, H., Yasuda, K., Ohkoshi, Y., et al., 2003. Anterior drawer test for acute anterior talofibular ligament injuries of the ankle: how much load should be applied during the test? *Am. J. Sports Med.* 31 (2), 226–232.
- Trojan, T.H., McKeag, D.B., 1998. Ankle sprains: expedient assessment and management. *Phys. Sports Med.* 26 (10), 29–40.
- Van Dijk, C.N., Lim, L.S., Bossuyt, P.M., et al., 1996. Physical examination is sufficient for the diagnosis of sprained ankles. *J. Bone Joint Surg. Br.* 78 (6), 958–962.
- Wolfe, M.W., Uhl, T.L., Mattacola, C.G., et al., 2001. Management of ankle sprains. *Am. Fam. Physician* 63 (1), 93–104.

INDEX

Note: **Emboldened page numbers** indicate chapter extents or main sections

A

- abduction stress test, valgus *see* valgus abduction stress test
- Abrahams, S. 230, 231
- accuracy of diagnostic tests 10–14
- ACJ *see* acromioclavicular joint
- Ackroyd, C.E. 203, 217
- acromioclavicular joint (ACJ) tests *see* *under* shoulder tests
- active compression tests 7, 76–9, 81
- active floor push-up test 103
- active patella grind test 222
- active pivot shift test 203
- active straight leg rise test for hip 165–6
- adduction tests
 - cross arm/crossover 79–81
 - flexion 155–6
 - horizontal impingement (scarf) 79–81
 - one-plane 186
 - quadrant 155–6
 - scour 155–6
 - ulnar collateral ligament 117–19, 133–5
 - varus stress, knee 186–8
 - wrist and hand 115–19, 133–5 *see also* FAIR test
- Aderinto, J. 68, 69
- Ahn, D.S. 137, 140
- aka ('also known as') sections 3
- Akseki, D. 220
- Al Chalabi, A. 256
- ALRI *see* anterolateral rotatory instability
- 'also known as' sections 3
- Altchek, D.W. 96
- AMRI (anteromedial rotatory instability) test 198–9
- Anderson, A.F. 203, 208
- Anderson, T.E. 48
- Andrews, J.R. 48, 84
- ankle and foot tests **236–62**
 - ligament instability **244–57**
 - anterior drawer test in prone 254
 - Chalke test 246
 - Cotton test 246
 - crossed leg test 247
 - dorsiflexion compression test 247
 - drawer test **250–4**
 - external rotation stress test **244–7**
 - heel thump test 247
 - Kleiger's test 244
 - positive 'dimple' sign 250
 - positive 'suction' sign 250
 - side-to-side test 246
 - squeeze test 247
 - talar tilt test **248–50**
 - ligament stress
 - anterior talofibular ligament stress test **236–8**
 - calcaneofibular ligament stress test **238–40**
 - calcaneocuboid ligament stress test **240–2**
 - medial collateral ligament stress test **242–4**
 - plantarflexion /inversion stress test 236
 - other
 - Copeland's test 257
 - Matles' test 257

- ankle and foot tests (*Continued*)
 metatarsal squeeze test **259–61**
 Morton's test 259
 peroneal subluxation test **257–9**
 Simmonds' test 255
 squeeze test 255
 Thompson's test **255–7**
- anterior drawer tests
 modified 198–201
 one-plane (for knee) 191–4
 in prone 254
- anterior glenohumeral instability 56, 59
- anterior labral tear test 159
- anterior shoulder instability 63–4
- anterior slide labral tests **52–4**
- anterior talofibular ligament stress tests **236–8**
- anterolateral rotatory instability
 199–204
 pivot shift test 201–4
 Slocum test 199–201
- anteromedial rotatory instability
 test 198–9
- anteversion, femoral, measuring 175–7
- Apley, A.G.: Apley's (grinding
 meniscal) test 212–15, 220
- apprehension sign 152
- apprehension tests 59, 152–6
 apprehension/crank/fulcrum test 56,
 60
 capitates, hand 124–6
 Fairbank's 224
 Jobe's 45, 56–61
 lateral pivot shift 98–101
 patellofemoral 224–5
 postlateral rotary, elbow 100
 and relocation instability 56–61
- arm tests
 biceps 19–21, 50–2
 cross 79–81
 drop/drop arm 27
 Speed's straight arm test 19–21
see also elbow; wrist and hand
- articular disruption, gleno-labral 47
- articular tests for hip *see under* hip tests
- Atkins, E. x-xi, 80, 94
 on hip 162, 178
 on knee 184, 218
 on wrist and hand 125, 130, 132,
 133, 138
- Austin, A. 160
- axial compression (axial grind)
 test **129–31**
- B**
- Badenoch, D. 7
- Bahk, M.S. 208, 210
- Bahr, R. 236, 237, 240, 248, 249, 251,
 252
- Baker, C.L. 187, 206, 212
- ballottement test 122
- Bandy, W. 171
- Bankart, A.S.P.: Bankart lesions 47, 73
- Bardakos, N.V. 164
- basal joint grind test 129
- Becker, H.P. 252
- belly-press (Napoleon) test 33
- Benjaminse, A. 193, 194, 197, 203
- Bennett, W.F. 20, 21
- Benson, E.R. 154
- Berg, E.E. 55
- Beumer, A. 245, 246
- biceps tests 19–21
 load II **50–2**
- Bigliani, L.U. 73
- Bird, P.A. 174
- Boeree, N.R. 203, 217
- Bousquet, G.: external hypermobility
 test 211
- Boyce, D.A. 168
 on ankle and foot 242, 246, 255,
 258, 259, 260, 261
 on wrist and hand 120, 121, 123,
 132, 136
- Bradley, J.P. 58
- Brown, D.E. 115, 121, 123, 129
- Bryan, R.S. 110
- Buehler, M.J. 108

Bulstrode, C. 128
 on elbow 91, 94, 100
 on knee 184, 221, 225
Burkhart, S.S. 33, 52
Burnett, R.S. 151, 153, 154, 155
Burwell, S. 6
Busconi, B.D. 153, 158
buttock
 pain 152–4, 158, 162, 166
 sign test for hip **177–9**
Byrd, J.W. 164

C

calcaneocuboid ligament stress
 tests 240–2
calcaneofibular ligament stress
 tests **238–40**
Callaghan, J. 166
Campbell, C.S. 134
capitate apprehension/displacement
 tests 124–6
carpal tunnel tests *see under* wrist and
 hand
chair push-up test of elbow
 ligament **101–3**
chair sign 101
Chalabi, A. al- 256
Chalke test 246
Childress's test 220
Chronopoulos, E. 78, 81
Cicak, N. 67
Ciullo, J.V. 55
'Clairon, signe de' (Patte's test) 29–30
Clarke's test 227
clicking hip test 159
clinical context of tests 6–9
Codman, E.A.: drop arm test 27
collateral ligament stress test 115–19,
 133–5
 medial **242–4**
Colville, M.R. 236, 240, 246, 248, 252
combined pressure provocation and
 flexion test 109
comfort, importance of 5

compression tests
 acromioclavicular joint 76–9
 active 7, **76–9**, 81
 axial **129–31**
 axial grind 129
 carpal tunnel, manual 145–7
 dorsiflexion 247
 Durkan's 145, 146
 knee, Noble's **227–9**
 rotation 46–50
 thumb **129–31**
Cooper, D.E. 208
Copeland, S.: test 257
Cosgarea, A.J. 208, 210
Cotton test 246
Cozen's test for elbow 91
Craig's test for femoral
 anteversion 175–7
crank tests
 apprehension 56, 60
 labral 46–50
Crenshaw, A.H. 20–1
cross arm/crossover adduction
 tests 79–81
 impingement tests 79
crossed leg test 247

D

Danlos, H.-A.: Ehlers-Danlos
 syndrome 164
Davidson, T.M. 134
de Quervain's tenosynovitis 117, 131,
 132–3
DeAngelis, N.A. 158
DeKrom, M.C. 142, 143
Dellon, A.L. 105, 106
Dervin, G.F. 217
diagnostic tests
 accuracy of 10–14
 expert opinion and clinical tips 13–14
 likelihood ratios in 11–13
 sensitivity 10–11
 specificity of 11
 variations and related tests 3

dial test 209–11
 ‘dimple’ sign 250
 disco weight-bearing knee test 218
 displacement tests, capitate 124–6
 Distefano, M.C. 59
 Donaldson, W.F. 202
 dorsiflexion compression test 247
 drawer tests
 ankle and foot 250–4
 knee 188–94
 Lemaire’s ‘T’ 198–9
 posterolateral rotatory instability (PLRI) 205–7
 posteromedial rotatory instability (PMRI) 204–5
 see also anterior drawer tests
 drop arm test 27
 drop sign, tendon 29
 Duckworth, A.D. 238
 Durkan, J.A.: compression test 145, 146

E

Eaton, R.G. 131
 Ege, R.: Ege’s test 220
 Ehlers, E.: Ehlers-Danlos syndrome 164
 elbow tests **89–112**
 ligament/instability
 active floor push-up test 103
 chair push-up test **101–3**
 chair sign 101
 Jobe’s test 95–7, 183–5
 moving valgus stress test 97
 posterolateral pivot shift test **98–101**
 posterolateral rotatory apprehension test 100
 posterolateral rotatory drawer test 100–1
 stand-up test 101
 valgus test **95–7**, 98, 99
 varus test **97–8**
 neurological **103–11**

combined pressure provocation and flexion test 109
 ‘OK’ sign 109
 pinch grip test **109–11**
 pressure provocation test **105–7**
 ‘Tinel’s test’ 94, 96, **103–5**, 106
 ulnar nerve flexion test **107–9**
 tendon
 Cozen’s test 91
 golfer’s elbow test **93–5**
 Mills’ test 92–3
 tennis elbow test **90–3**
 Ellenbecker, T.S. 63, 66, 68, 75
 Ely’s test 169
 Emery, R.J. 73
 empty/full can tendon tests **24–7**
 Evans, P.J. 217
 evidence
 appraisal 6–9
 interpretation of 5, **9–15**
 accuracy of diagnostic tests 10–14
 expert opinion and clinical tips 13–14
 extension test, hip 159
 external hypermobility test 211
 external rotation
 FABER test
 lag sign 27–30
 recurvation test 211–12
 stress test (Kleiger’s), ankle and foot **244–7**
 extension test, hip 159
 tendon
 Cozen’s test 91
 golfer’s elbow test **93–5**
 Mills’ test 92–3
 tennis elbow test **90–3**
 extension test, hip 159

F

FABER test (flexion, abduction and external rotation) articular test for hip 160–3
 FAIR test (flexion, adduction and internal rotation) 152–6, 162

- see also* flexion tests; impingement tests
- Fairbank's apprehension test 224
- Farber, A.J. 58, 59, 63
- Farber, J.S. 110
- Feagin's test 75
- feet *see* ankle and foot
- femoral anteversion, measuring 175–7
- Fertl, E. 137, 146, 147
- Field, L.D. 96
- Fingerth, R.J. 96, 194, 197, 202, 203
- fingers *see* wrist and hand
- Finkelstein, N.: thumb test 117, 121, 131–3
- Finochietto, R.: jump sign 193
- Fishman, L.M. 153, 154
- Fitzgerald, R.H. 153, 159
- Flatow, E.L. 36
- flexion tests
- adduction 155–6
 - of elbow 107–9
 - of hip 165–6
- see also* FABER test; FAIR test
- floor push-up test, active 103
- foot *see* ankle and foot
- forearm, supination of (Heuter's sign) 23–4
- forward flexion impingement test on shoulder (Neer's sign) 34–9, 42–3
- '4' test (FABER hip test) 160–3
- Fowler, P.J. 214, 216, 217, 218
- Fowler's sign 56
- Fritz, J.M. 7
- Frobell, R.B. 196
- Frund's sign 227
- fulcrum test 56, 60
- full can tendon test 24–7
- Fujii, T. 237
- G**
- Gaebler, C. 246, 249, 250, 253
- Gajdosik, R.L. 171
- Gamekeeper's thumb 134
- Gerber, C
- lift-off sign test 30–4
 - push-off test 31, 33–4
- Gerr, F. 105, 137, 138, 142, 143
- Ghavami, A. 129
- Gilchrest, B.: sign 23
- Giori, N.J. 177
- GLAD (gleno-labral articular disruption) 47
- glenohumeral instability, anterior 56, 59
- glenohumeral joint, load and shift test for 61–5
- gleno-labral articular disruption 47
- Glickel, S.Z. 131
- Godfrey's test 191
- Gold, S.M. 196
- Golding, D.N. 138, 142, 143
- golfer's elbow test **93–5**
- González del Pino, J. 146
- Graham, B. 137, 142
- gravity drawer test 191
- Greenfield, C. 91
- Greenwald, 106, D. 105
- Greis, P.E. 31
- grind tests
- Apley's **212–15**, 220
 - axial compression **129–31**
 - basal joint 129
 - meniscal 127–9, **212–15**, 220
 - patellofemoral **225–7**
- Gross, J. 121, 144, 255, 261
- Gross, M.L. 59
- Guanche, C.A. 20, 21, 49, 58, 78
- Guyon, J.C.F.: Guyon's canal 105, 143–4
- H**
- Hamner, D.L. 45
- Hanchard, Nigel viii, xii, 17
- hand *see* wrist and hand tests
- Hardaker, W.T. 230
- Hardcastle, P.: Hardcastle and Nade method 173, 174–5

- Harper, M.T. 135
 Hase, T. 153, 154
 Hawkins, R.J. 63
 Hawkins-Kennedy impingement test
 on shoulder 39–41
 Hayden, J.: Mital-Hayden test 229–31
 heel thump test 247
 Hegedus, E.J. 58, 79, 83
 Heinecke, A. 177
 Heller, L. 142
 Helmig, P. 74
 Heneghan, C. 7
 Hertel, R. 26, 28, 29, 32, 33
 Heuter, C.: Heuter's sign (supination of
 forearm) 23–4
 Hewett, T.E. 189
 hip tests **151–80**
 articular
 '4' test 160
 active straight leg raise (SLR)
 test **165–6**
 anterior labral tear test 159
 apprehension sign 152
 clicking hip test 159
 extension test 159
 FABER test **160–3**
 FAIR test **152–6**, 162
 impingement tests 152–6
 Jansen's test 160
 Ling test 166
 log roll test 160
 McCarthy test 153, **155–60**, 164
 Mens test 165
 Patrick's test 160
 piriformis test 152
 posterior labral tear test 152,
 159–60
 psoas test 152
 scour/quadrant/flexion adduction
 test 155–6
 snapping hip test 159
 Stinchfield resisted hip flexion
 test 165
 torque test **163–4**
 muscle and tendon
 Ely's test 169
 Hardcastle and Nade method 173,
 174–5
 Hugh Owen Thomas (HOT)
 test 166
 modified Ober's test **170–2**
 modified Thomas's test 168–9
 Ober's test 171–2
 rectus femoris contracture test 166
 Thomas's test **166–9**
 Thompson test 166
 Trendelenburg test **172–5**
 other
 Craig's test **175–7**
 Ryder method for measuring
 femoral anteversion 175
 sign of the buttock **177–9**
 history taking 3–4
 Holtby, R. 26
 horizontal adduction impingement
 (scarf) test 79–81
 hornblower's sign 30
 Hugh Owen Thomas (HOT) test *see*
 Thomas's test
 Hughston, J.C. 210
 jerk test 203
 plica test 231
 posterolateral drawer sign 205
 posterolateral drawer test 205–7
 posteromedial drawer sign 204
 posteromedial drawer test 204–5
 varus stress test 186–8
 Huijbregts, P.A. 79
 humeral head translation test, inferior
 (sulcus sign) 71–6
 Hurley, J.A. 48
 hypermobility test, external
 (Bousquet) 211
- I**
 impingement tests
 hip **152–6**
 shoulder **34–45**

- Hawkins-Kennedy 39–41
- Jobe's internal rotation
 - resistance **42–3**
- Neer's sign 34–9, 42–3
 - posterior 44–5
 - see also* FAIR test
- inferior humeral head translation test
 - (sulcus sign) 71–6
- infraspinatus spring back test *see* lag sign
- instability
 - anterolateral *see* anterolateral
 - rotatory instability
 - rotatory *see* rotatory instability
 - ligaments *see* ligament tests
 - shoulder *see under* shoulder tests
- internal rotation
 - lag sign 30–4
 - lift-off test, maximum 32
 - resistance tests on shoulder 42–3
 - see also* FAIR test
- interpretation of findings *see under* evidence
- inversion stress tests 236–8
 - calcaneofibular **238–40**
 - calcaneocuboid ligament **240–2**
- isometric action in push-off test 33–4
- Ito, K. 154
- Itoi, E. 25–6

J

- Jaberi, F. 153
- Jackson, J.L. 190, 193, 196, 197, 203, 216, 218
- Jaeschke, R. 7
- Jakob, R.P.: Jakob test (reverse pivot shift) 207–9
- Jansen's test 160
- jerk test, Hughston's 203
- Jobe, F.W.: tests
 - apprehension 45, 56–61
 - impingement 36, 38, **42–3**
 - relocation 24
 - tendon empty/full can **24–7**
 - valgus abduction stress 95–7, 183–5
- joint grind test, basal 129–31
- Jones, D.C. 20, 21, 49, 58, 78
- Jordan, R. 137

K

- Karachalios, T. 213–14, 216, 217, 218, 220
- Katz, J.N. 142
- Katz, J.W. 96, 194, 197, 202, 203
- Kelly, B.T. 25, 33, 34
- Kennedy, J.C.: Hawkins-Kennedy impingement test 39–41
- Kern, J.H. 230, 231
- Kibler, W.B. 53–4
- Kilgore, W.E. 20–1
- Kiloh, L.G.: Kiloh-Nevin syndrome 110
- Kim, S.J. and H.K. 193, 196, 203
- Kim, T.K. 20, 32, 36, 41, 51–2
- Kim, W.Y. 177
- Kleiger's external rotation stress test of ankle and foot 244–7
- knee tests **181–234**
 - meniscal **212–20**, 231
 - Apley's grinding test 212
 - Apley's test **212–15**, 220
 - Childress's test 220
 - disco test 218
 - Ege's test 220
 - McMurray's test 213, 214, **215–18**, 220, 231
 - Merke's test 218
 - Thessaly test 218
 - weight-bearing/rotation meniscal test **218–20**
 - multiplane **198–212**
 - active pivot shift test 203
 - Bousquet external hypermobility test 211
 - dial test **209–11**
 - external rotation recurvatum test **211–12**

- knee tests (*Continued*)
- Hughston's posterolateral drawer sign 205
 - Hughston's posteromedial drawer sign 204
 - Jakob test 207
 - jerk test of Hughston 203
 - lateral pivot shift test 201
 - Lemaire's 'T' drawer test 198
 - Loomer's test 211
 - Losee test 203
 - modified anterior drawer test 198, 199
 - pivot shift test **201-4**
 - reverse 207-9
 - soft 203
 - posterolateral drawer test **205-7**
 - posteromedial drawer test **204-5**
 - Slocum ALRI (anterolateral rotatory instability test) **199-201**
 - Slocum AMRI (anteromedial rotatory instability test) **198-9**
 - test of Macintosh 201
 - tibial lateral rotation test 209
 - one-plane **183-97**, 205
 - abduction stress test 183
 - active drawer test 191
 - adduction stress test 186
 - anterior drawer in extension test 194
 - anterior drawer test 191-4
 - Finochietto's jump sign 193
 - Godfrey's test 191
 - gravity drawer test 191
 - Hughston's varus stress test 186
 - Lachman's test 101, **194-7**, 199, 205
 - Lachman-Trillat test 194
 - posterior drawer test **188-91**
 - posterior sag sign 191
 - quadriceps active test 191
 - Ritchie test 194
 - Trillat test 194
 - valgus test **183-5**, 201, 207, 208
 - varus test **186-8**, 200, 206, 208, 218
 - other **227-31**
 - Hughston's plica test 231
 - mediopatellar plica test **229-31**
 - Mital-Hayden test 229
 - Noble's compression test **227-9**
 - plica stutler test 231
 - suprapatellar plica test 231
 - patellofemoral **221-7**
 - active patella grind test 222
 - Clarke's test 227
 - Fairbank's apprehension test 224
 - Frund's sign 227
 - grind test **225-7**
 - McConnell test **221-3**
 - patella apprehension test **224-5**
 - squat tests 222-3
 - step tests 222-3
 - vastus medialis* coordination test 223
 - Waldron's test 223
 - Zohler's test 227
 - Kocabey, Y. 196, 202
 - Kovaleski, J.E. 252
 - Krushell, R.J. 31, 32
 - Kutsumi, K. 132
- L**
- labral tests **46-55**
 - anterior slide **52-4**
 - apprehension 58
 - biceps 50-2
 - crank 46-50
 - posterior tear 152-6, 159-60, 162
 - SLAP prehension **54-5**
 - tear 58, 159
 - Lachman, J: one-plane test for knee (Ritchie or Trillat test) 101, **194-7**, 199, 205
 - lag sign
 - external rotation 27-30
 - internal rotation 30-4

- Lähde, S. 252
Laliotis, A.T. 134
Lapner, P.C. 100, 103
LaPrade, R.F. 187, 206, 208, 210, 212
Larsen, M.W. 187, 188, 189, 191, 206, 208, 212
Larson, R.L. 183, 199, 200
lateral pivot shift test 210
 apprehension 98–101
laxity test, ulnar collateral ligament 133–5
Lee, D. 164, 166, 168
Lee, M.D. 194, 197
Lee, M.L. 96
leg rise test for hip, active (SLR) **165–6**
Lemaire, M.: ‘T’ drawer test 198–9
Lequesne, M. 174
Lerat, J.L. 197
Leroux, J.L. 26, 32
Letz, R. 105, 137, 138, 142, 143
Lewis, A. 72
Lewis, C.L. 153
Lichtman, D.M.: test 126
lift test, supination 129
lift-off sign test **30–4**
ligament tests *see under* ankle and foot;
 elbow; wrist and hand
likelihood ratios in diagnostic tests 11–13
Ling test 166
Lintner, S.A. 73
Lippman, M.: test 23
Liu, S.H. 48, 49
Liume, J.J. 58, 59
Lo, I.K.Y. 58, 59, 60
Lo, J.K. 142
load tests
 and shift test for glenohumeral joint 61–5
 load II test, biceps 50–2
 triangular fibrocartilage complex (TFCC) tests 123, 127–9
log roll test 160
Loomer’s test 211
Losee test 203
LR (likelihood ratios in diagnostic tests) 11–13
Lubliner, P.A. 214, 216, 217, 218
Ludington’s test 24
lunotriquetral shear test of wrist and hand **122–4**
- M**
MacAuley, D. 28
McCarthy, J.C.: articular test for hip 153, **155–60**, 164
McConnell, J.S.: patellofemoral test **221–3**
MacDonald, P.B. 36, 41
McFarland, E.G. 7, 36, 41, 73
Macintosh test 201
 see also pivot shift tests
McKeag, D.B. 236, 243, 245, 258
McMurray, T.P.: test 7, 8, 11
 on knee 213, 214, **215–18**, 220, 231
 on shoulder 49
Macnicol, M. 155
McPherson, S.A. 105, 106
McRae, R. 121, 129, 146
Maffuli, N. 256
Magee, D.J. 137
 on ankle and foot 247, 253, 254
 on hip 159, 168, 177
 on knee 193, 197, 199, 209, 220, 225, 227, 231
 on shoulder 36, 64, 68
Malanga, G.A. 8
 on ankle and foot tests 256, 257, 261
 on knee tests
 Apley’s 213, 214
 patellofemoral grind 225, 226
 pivot shift 202
 posterior drawer 188, 190
 valgus 183, 185
 varus 187
 on wrist and hand tests 137, 139, 142
Mallon, W.J. 73

- manual carpal compression test 145–7
 Matles' test 257
 Matteson, E. 3
 Maudsley, R.H. 92
 maximum internal rotation lift-off test 32
 Meals, R.A. 105, 106
 medial collateral ligament stress tests **242–4**
 medial rotation 'spring back' (lift-off sign test) **30–4**
 median nerve percussion test (Tinell's test) *see* Tinell
 mediopatellar plica test for knees **229–31**
 meniscal tests *see under* knee tests
 Mens test (active straight leg rise) 165
 Merke's test of weight-bearing 218
 metatarsal squeeze test **259–61**
 midcarpal pivot shift test 126
 Miller, T.T. 120, 123, 127, 128, 134
 Mill's test 92–3
 Mital, M.A.: Mital-Hayden test 229–31
 Mitchell, B. 153, 162
 modification of techniques 5–6
 modified anterior drawer tests 198–201
 modified Ober's test 170–2
 Morgan, C.D. 52
 Morton's test (metatarsal squeeze) 259
 moving valgus stress test 97
 Mulder, J.D.: Mulder's sign 261
 Mullaji, A.B. 73
 multiplane knee tests *see under* knee tests
 Murphy's sign 124
 Murrell, G.A. 63, 74
 muscle and tendon hip tests *see under* hip tests
- N**
- Nade, S. 173, 174–5
 Nadler, S.: Hardcastle and Nade method 173, 174–5
 on ankle and foot 256, 257, 261
 on wrist and hand 137, 139, 142
 Napoleon (belly-press) test 33
 Naredo, E. 36, 41
 Narvani, A.A. 153, 156, 158, 228
 Neer, C.S.: Neer's sign 34–9, 42–3
 Neumann, R.D. 115, 121, 123, 129
 neurological elbow tests *see under* elbow tests
 Nevasier, J.S. 47
 Nevin, S.: Kiloh-Nevin syndrome 110
 Nijs, J. 223, 225
 Nisonson, B. 230
 Noble, P.: compression tests for knee **227–9**
 'normality' 4
 Norwood, L.A. 206
 on stress tests 67–71, 74
 Novak, C.B. 104, 105, 107, 108, 109
- O**
- Ober's muscle and tendon tests for hip **170–2**, 22
 O'Brien, S.J.: active compression test 76–9
 O'Driscoll, S.W. 97, 98, 100, 101, 102
 Oh, J.H. 21
 Oishi, S.N. 129
 'OK' sign (pinch grip test) 109–11
 one-plane knee tests *see under* knee tests
 O'Shea, K.J. 226
 Ostrowski, J.A. 193, 196, 202
- P**
- pain and apprehension 58
 buttock 152–4, 158, 162, 166
 Palmer, A.K. 127
 Pappas, A.M. 49
 Parentis, M.A. 20, 21, 22, 36, 41, 49, 53, 54, 78, 79
 Parsonage, M.J.: Parsonage-Turner syndrome 26
 Parvizi, J. 153

- passive mobility (shear) test on
 acromioclavicular joint 81–4
- patella apprehension test **224–5**
- patella grind test, active 222
- patellofemoral knee tests *see under*
 knee tests
- Patrick's test (FABER hip test) 160–3
- Patte's test ('signe de Clairon') 29–30
- Paxinos, A.: test **83–4**
- percussion test, median nerve *see* Tinel
 test
- peroneal subluxation test **257–9**
- Perthes, G.: Perthes' disease 155
- Phalen, G.S.: carpal tunnel test **135–40**,
 142, 146–7
- physical examination, basic 3–4
- piano key ligament instability test of
 wrist and hand **114–15**
- pinch grip ('OK' sign) test 109–11
- piriformis test 152
 see also FAIR test
- pivot shift tests
- of elbow, posterolateral **98–101**
 - of knee **201–4**
 - active 203
 - anterolateral rotatory
 instability 201–4
 - jerk of Hughston 203
 - Losee 203
 - midcarpal 126
 - reverse (Jakob test) **207–9**
 - soft 203
- Placzek, J.D.
- on ankle and foot 242, 246, 255,
 258, 259, 260, 261
 - on hip 168
 - on wrist and hand 120, 121, 123,
 132, 136
- plane tests for knees *see* multiplane;
 one-plane
- plantarflexion/inversion stress tests 236
- plica test for knees, mediopatellar
 229–31
- plica stutter test 231
- PLRI *see* posterolateral rotatory
 instability
- PMRI (posteromedial rotatory
 instability) **204–5**
- Popeye sign 20
- positive 'dimple' sign 250
- positive 'suction' sign 250
- posterior drawer one-plane test for
 knee 188–91
- posterior impingement tests on
 shoulder 44–5
- posterior labral tear test 152–6,
 159–60, 162
 see also FAIR test
- posterior sag sign 191
- posterior shoulder instability 63
- posterolateral pivot shift test **98–101**
- posterolateral rotatory apprehension
 test 100
- posterolateral rotatory instability
 (PLRI) 187, 205–12
- dial test 209–11
 - drawer test **205–7**
 - external rotation recurvation
 test 211–12
- posteromedial rotatory instability
 (PMRI) **204–5**
- Powell, J.W. 79
- prehension tests, SLAP **54–5**
- pressure provocation tests
- of elbow **105–7**
 - of wrist and hand 109, 145–7
- psoas test 152
 see also FAIR test
- push-off test, Gerber's 31, 33–4
- push-up test of elbow ligament
 101–3
- Q**
- quadrant adduction test 155–6
- quadriceps active test 191
- quality of tests 4
- Quervain, F. de: tenosynovitis 117,
 131, 132–3

R

- radial collateral ligament stress test **115–17**
- Rayan, G.M. 104, 109
- Razmjou, H. 26
- Reagan's lunotriquetral shear test **122–4**
- rectus femoris contracture test 166
- recurvatum test, external rotation 211–12
- Reese, N. 171
- Regan, W. 100, 103
- regularity of tests 4–5
- relocation tests 24, 56–61
- reverse pivot shift test (Jakob test) 207–9
- Ritchie test (Lachman test) 101, **194–7**, 199, 205
- Rivner, M.H. 137, 142
- Roberts, C.S. 36, 40
- Robinson, C.M. 68, 69
- Roles, N.C. 92
- Rosati, M. 108
- Rose, N.E. 196
- Rosenwasser, M.P. 96
- rotation
 - compression test 46–50
 - meniscal test on knee **218–20**
 - unstable *see* rotatory instability
 - see also* external rotation; internal rotation
- rotator cuff pathology 58
- rotatory instability **198–205**
 - anteromedial (AMRI) **198–9**
 - posteromedial (PMRI) **204–5**
 - see also* anterolateral; posterolateral
 - rotatory instability; rotation
- Rowe tests 60, 61–3, 75–6
- Rubenstein, R.A. 190
- Ryder method for measuring femoral anteversion (Craig's test) 175–7
- Ryzewicz, M. 214, 216, 217, 218, 220

S

- Sackett, D.L. 6, 7
- Saengnipanthkul, S. 230, 231
- Sahrman, S.A. 153
- Sallay, P.I. 225
- scaphoid shift ligament test of wrist and hand **119–22**
- scaphoid stress test 122
- scaption (empty/full can) tendon tests **24–7**
- scarf test on acromioclavicular joint **79–81**
- Scholten, R.J. 193, 194, 196, 197, 203, 217
- Schutzer, S.F. 154
- Schweitzer, M.E. 120, 123, 127, 128, 134
- Scott, B. 256
- scour adduction test 155–6
- selection of tests 4
- sensitivity of diagnostic tests 10–11
- Seror, P. 142
- shear tests
 - on acromioclavicular joint (passive mobility) **81–4**
 - lunotriquetral, of wrist and hand **122–4**
- shoulder tests **17–88**
 - acromioclavicular joint (ACJ) **76–84**
 - acromioclavicular passive mobility test 81
 - active compression 7, **76–9**, 81
 - cross arm adduction impingement test 79
 - cross arm adduction test 79
 - crossover impingement test 79
 - horizontal adduction impingement test 79
 - O'Brien's test 76
 - Paxinos test **83–4**
 - scarf test **79–81**
 - shear test (passive mobility) **81–4**
 - impingement **34–45**

- forward flexion impingement test **34–9**, 42–3
- Hawkin's impingement test 34
- Hawkins-Kennedy impingement test **39–41**
- internal rotation resistance strength test **42–3**
- Neer's sign 34–9, 42–3
- posterior impingement test 44–5
- instability **56–76**
 - apprehension crank test 56
 - apprehension and relocation test **56–61**
 - apprehension test 56, 59
 - Fowler's sign 56
 - Jobe relocation test 56
 - load and shift test **61–5**
 - Norwood stress test **67–71**, 74
 - subluxation/relocation test 56, 59
 - sulcus sign **71–6**
 - surprise test 58, 59, 60
- labral **46–55**
 - anterior slide test **52–4**
 - biceps load II test **50–2**
 - compression rotation test 46
 - crank test **46–50**
 - SLAP prehension test **54–5**
 - slapper test 54
- tendon **19–34**
 - belly press test 33
 - Codman's test 27
 - drop arm test 27
 - drop sign 29
 - empty/full can tests **24–7**
 - external rotation lag sign **27–30**
 - Gerber push off test 31, 33–4
 - Gilchrest's sign 23
 - Heuter's sign 23–4
 - hornblower's sign 30
 - lift-off sign **30–4**
 - Lippman's test 23
 - Ludington's test 24
 - maximum internal rotation lift-off test 32
 - Napoleon test 33
 - Patte's test 29–30
 - Speeds test **19–21**
 - Yergason's test **21–4**
- Shuck lunotriquetral shear test 122–4
- side-to-side test 246
- sign of the buttock 177–9
- 'signe de Clairon' (Patte's test) 29–30
- Simmonds' test 255
- SLAP/slapper prehension tests, labral **54–5**
- Slocum, D.B. and tests 183, 193, 203
 - for anterolateral rotatory instability **199–201**
 - for anteromedial rotatory instability **198–9**
- SLR (straight leg rise) articular test for hip 165–6
- snapping hip test 159
- Snyder, S.J. 48
- soft pivot shift test 203
- Solomon, D.H. 190, 193, 194, 197, 214, 216, 217, 218
- Spaeth, H.J. 135
- special tests in musculoskeletal examination **3–15**
 - see also* ankle and foot; elbow; hip; knee; shoulder; wrist and hand
- specificity of diagnostic tests 10–11
- Speed's tendon test 19–21
- Speer, K.P. 59, 73
- spring back test 27
- squat tests 222–3
- squeeze tests 247, 255, 259–61
- stand-up test of elbow ligament 101
- Standaert, C.J. 154, 158
- Strandring, S. 110, 240
- Stanley, J. 92
- Stefko, J.M. 32
- Stegink-Jansen, C.W.: Jansen's test 160
- Stener, B.: Stener lesion 134–5
- step tests 222–3
- Stetson, W.B. 49

- Stiell, I.G. 237, 238
- Stinchfield resisted hip flexion test
(active straight leg rise)
165–6
- straight arm test (Speed's test) 19–21
- straight leg rise test for hip 165–6
- stress tests 97–8, 183–8
- external rotation stress test, ankle and foot **244–7**
 - inversion 236–8, 240–2
 - ligament *see under* ligament tests
 - Norwood's shoulder **67–71**, 74
 - plantarflexion/inversion 236
 - see also* valgus abduction stress;
varus stress
- Struhl, S. 40
- stutter test, plica 231
- subluxation tests 58, 257–9
- /relocation test 56, 59
- 'suction' sign, positive 250
- Suder, P.A. 36, 37
- sulcus sign test on shoulder 71–6
- superior labral anterior posterior **54–5**
- supination lift test 129
- supination of forearm 23–4
- suprapatellar plica test 231
- supraspinatus strength test 24–7
- surprise test 58, 59, 60
- Szabo, R.M. 137
- T**
- 'T' drawer test, Lemaire's 198–9
- talar tilt test **248–50**
- talofibular ligament stress tests,
anterior 236–8
- tear tests, labral 58, 159
- posterior 152–6, 159–60, 162
- technique 3–6
- history and basic physical examination 3–4
 - modification according to tissue type and condition 5–6
 - 'normality' and huge variety of body type 4
- Tehrany, A. 33
- Templin, K. 49, 78
- tendon tests 19–34
 - elbow *see under* elbow tests
 - empty/full can 24–7
 - external rotation lag sign 27–30
 - hip muscle and tendon *under* hip tests
 - lift-off sign **30–4**
 - Speed's 19–21
 - Yergason's 21–4
- tennis elbow test **90–3**
- tenosynovitis, de Quervain's 117, 131, 132–3
- Terry, G.C. 187, 206, 212
- Terry Thomas sign 121
- tests *see* ankle and foot tests; elbow tests; hip tests; knee tests; shoulder tests; wrist and hand tests
- Tetro, A.M. 137, 138, 143, 146, 147
- TFCC (triangular fibrocartilage complex) tests 123, 127–9
- Thayer, D.T. 108
- Thessaly test 218
- Thomas, H.O.: muscle and tendon test (HOT), hip 166–9
- Thompson's ankle and foot tests **255–7**
- thumb tests *see under* wrist and hand
- tibial lateral rotation test 209
- tilt test, Talar 248–50
- Tindel, N. 230
- Tinel, J.: Tinel's test
- on elbow 94, 96, **103–5**, 106
 - on wrist and hand (carpal tunnel) 137, **140–4**
- Tohyama, H. 236, 252, 253
- Tonnis, D. 177
- Torg, J.S. 196
- torque articular test for hip **163–4**
- Toth, A. 187, 188, 189, 191, 206, 208, 212
- Trendelenburg, F.: test 172–5

- triangular fibrocartilage complex
tests 123, 127–9
- Trillat test (Lachman test) 101, **194–7**,
199, 205
- Trojan, T.H. 236, 243, 245, 258
- Trousdale, R.T. 177
- Turner, A.: Parsonage-Turner
syndrome 26
- Tzannes, A. 58, 63, 64, 74
- U**
- Ueo, T. 153, 154
- ulnar tests
- impaction test 127
 - ligament collateral **117–19**, 133–5
 - meniscal grind (TFCC load
test) 127–9
 - nerve flexion of elbow **107–9**
- ulnar tunnel syndrome 143–4
- Valadie, A.L. 36, 40
- valgus abduction stress test 7–8
- elbow **95–7**, 98, 99
 - knee **183–5**, 201, 207, 208
 - wrist and hand **133–5**
- Van Dijk, C.N. 237, 249, 252
- Van Dommelen, B.A. 134
- variety of body type 4
- varus stress test **97–8**
- adduction 186–8
 - ankle and foot 239, 248
 - elbow **97–8**
 - knee **186–8**, 200, 206, 208, 218
 - moving 97
 - wrist and hand 134
- vastus medialis* coordination test 223
- Villar, R.N. 164
- W**
- Wainner, R.S. 7
- Waldron's test 223
- Waller, A.V.: Wallerian
degeneration 104
- Walton, J. 78, 81, 83, 84
- Wang, T.G. 171
- Watson test of scaphoid shift
ligament 119–22
- Webster, V. 91
- weight-bearing/rotation by knee,
Merke's test of 218–20
- Weiss, S. 121
- Welsh, R.P. 35
- Wentorf, F. 206, 208, 210, 212
- Werner, F.W. 127
- Whitworth, J.A. 3
- Williams, T.M. 137, 138, 142, 143, 146
- Wolf, J.M. 132
- Wolfe, M.W. 236, 237, 243, 245, 247,
249, 251
- Woods, D. 155
- Woywodt, A. 3
- wrist and hand tests **113–47**
- carpal tunnel **135–49**
 - carpal compression test **145–7**
 - Durkan's compression test 145,
146
 - hand elevation test 140
 - manual carpal compression
test 145
 - median nerve percussion test 140
 - Phalen's test **135–40**, 142, 146–7
 - prayer test 139
 - pressure provocative test 145
 - three jaw chuck test 140
 - Tinel's test 137, **140–4**
 - tourniquet test 139–40
 - ulnar tunnel syndrome 143–4
 - ligament/instability **113–29**
 - adduction test 115
 - ballottement test 122
 - capitate apprehension test **124–6**
 - capitate displacement test 124
 - Lichtman's test 126
 - lunotriquetral shear test **122–4**
 - midcarpal pivot shift test 126
 - Murphy's sign 124
 - piano key test **114–15**
 - radial collateral ligament stress
test **115–17**

- wrist and hand tests (*Continued*)
 - Reagan's test 122–4
 - scaphoid shift test **119–22**
 - scaphoid stress test 122
 - Shuck test 122
 - ulnar collateral ligament stress test **117–19**
 - Watson test 119
 - wrist abduction test 117
 - wrist adduction test 115
 - thumb **129–35**
 - axial compression test **129–31**
 - axial grind test 129
 - basal joint grind test 129
 - Finkelstein's test 117, 121, **131–3**
 - gamekeeper's thumb 134
 - grind test 129
 - triangular fibrocartilage complex (TFCC) tests 123, **127–9**
 - supination lift test 129
 - TFCC load test 123, **127–9**
 - thumb grind 129
 - ulnar collateral ligament laxity test **133–5**
 - ulnar impaction test 127
 - ulnar meniscal grind test 127
- Y**
- Yergason's tendon test 21–4
 - Yoon, Y.S. 196
 - Youdas, J.W. 172
- Z**
- Zaslav, K.R. 43
 - Zohler's test 227
 - Zvirbulis, R.A. 134